



ISSN 2456-3110

Vol 6 · Issue 1

Jan-Feb 2021

Journal of
**Ayurveda and Integrated
Medical Sciences**

www.jaims.in

JAIMS

An International Journal for Researches in Ayurveda and Allied Sciences



Charaka
Publications

Indexed

A Clinical Study of *Apamarga Kshara Sutra* in the Management of *Bhagandara* - A Case Study

Dr. Ashok Naikar¹, Dr. Vanita², Dr. C. Halli³

¹Associate Professor, ²Final Year Post Graduate Scholar, ³Professor, PG Dept. of Shalya Tantra, N.K. Jabshetty Ayurvedic Medical College & P.G. Centre, Bidar, Karnataka, INDIA.

ABSTRACT

In *Ayurveda*, *Bhagandara* is considered as one of the *Ashta Mahagaroga* (8 major disease) by *Sushruta* due to more recurrence rate. In present era anorectic disorders are increasing, due to sedentary life style and others factors. The word *Bhagandara* is composed of 2 words *Bhaga* and *Darana*, it is a common disease occurring in Anorectal region around the anus which extends up to Genitalia. The formation of *Pidika* leads development of *Bhagandara* it is characterized by opening around the *Guda Pradesha* with painful Discharge. *Bhagandara* is treated by different modalities modern science but till day no single modalities have proven to be complete one for *Fistula*, *Kshara Sutra* therapy is the unique specialized parasurgical procedure which is used in *Fistula* in *Ano*. The present study was undertaken to assess the role of *Apamarga Kshara Sutra* in treatment of *Bhagandara* on diagnosed case was taken from OPD of NKJ AMC attached teaching, Shree Siddharudha Charitable Hospital, Bidar, Age 26 yrs. Male Patient presenting with pain, swelling, discharge in scrotal to anterior anal canal (scrotal extension) was examined in Shalya OPD treated with *Kshara Sutra* considering it an ideal procedure in the treatment of *Bhagandara* as it cuts and cures the unhealthy tissue present inside the fistulous tract.

Key words: *Bhagandara, Fistula in Ano, Scrotal Extension, Apamarga Kshara Sutra.*

INTRODUCTION

Bhagandara can be correlated with fistula in ano, *Bhagandara* means which cause splitting or discontinuity in the region of *Bhaga, Guda, Basti* region.^[1] It is one among *Ashtamahagada*,^[2] in modern fistula word is derived from a Latin word, a reed, pipe or flute. It is an abnormal communication between anal canal and rectum with exterior (perianal skin) is called fistula in ano,^[3] it usually results from an

anorectal abscess which burst spontaneously or opened in adequately.

In this study we found the fistula extended up to base of the scrotum in which pain, swelling, redness, pus discharge from base of the scrotum. Goodsall's Rule for predicting the tract of fistula is diagnosed with flexible copper probe it opens into the anterior anal canal.

High trans sphincteric or supra sphincteric fistula can be correlated with such type of fistulas. Application of *Kshara Sutra* in anorectal disease has become more popular due to its easy approach and low rate of recurrence.

In this case study, fistula in ano was treated by *Kshara Sutra* which was cured and no further complaints and recurrence were found during and follow up period. It is more important among *Shastra* and *Anushastra Karma*, *Kshara* having the *Chedana, Bhedana, Lekhana* also *Tridoshaghna* properties.^[4]

Address for correspondence:

Dr. Ashok Naikar

Associate Professor, PG Dept. of Shalya Tantra, N.K. Jabshetty Ayurvedic Medical College & P.G. Centre, Bidar, Karnataka, INDIA.
E-mail: dranaikar@rediffmail.com

Submission Date: 09/01/2021 Accepted Date: 02/02/2021

Access this article online

Quick Response Code



Website: www.jaims.in

Published by Maharshi Charaka Ayurveda Organization, Vijayapur, Karnataka (Regd) under the license CC-by-NC-SA

CASE REPORT

Gender - Male

Age - 26 yrs.

Occupation - Engineer

Date of admission - 11/09/2020

Date of recovery - 30/10/2020

Chief complaints and duration - Patient complaints of pain, swelling, pus discharge from base of the scrotum in the last 15 days.

H/O Present illness

26 yrs. young male patient present with complaints of painful swelling with discharge at anterior aspect of base of scrotum, with induration on 11/09/2020 at our OPD. h/o - surgery, before 8 months on 27/01/2020 in Anupama Hospital, Hyderabad (Telangana State). Underwent fistulotomy under spinal anesthesia. Presently, on examination patient was discharging tract at 11 o' clock position in the anterior perineum behind the scrotum was very painful with tenderness, diagnosis was confirmed by fistulography on 10/01/2020. Suggestive of high scrotal anal fistula internal opening at 12 o'clock position. Recurrence of fistula in Ano found.

H/o past illness - no previous h/o any other severe illness.

General Examination

- GC - moderate
- CVS - S1 S2 Heard
- Pulse - 82/min, BP-120/70mmhg
- RS - B/L Air entry is clear
- Digestive system - Appetite -Normal, Bowel-Normal
- Uro genital system - NAD

On local examination

In the lithotomy position of the patient findings observed were, patient has pus discharge at the base of scrotum small opening at 11 o' clock, in anterior perineum behind the scrotum at the root of penis seropurulent discharge through that opening tenderness on touch with induration was felt around

external opening probing was done from external opening to find the internal opening, on probing 8 cm Tract was found in between the anogenital space. On proctoscopic examination no any anal pathology was Diagnosed. Complete anorectal examination was done, finally diagnosis was confirmed as a complicated high scroto-anal fistula. (recurrence).

Preparation of Kshara Sutra

Arka Ksheera = 11 coatings

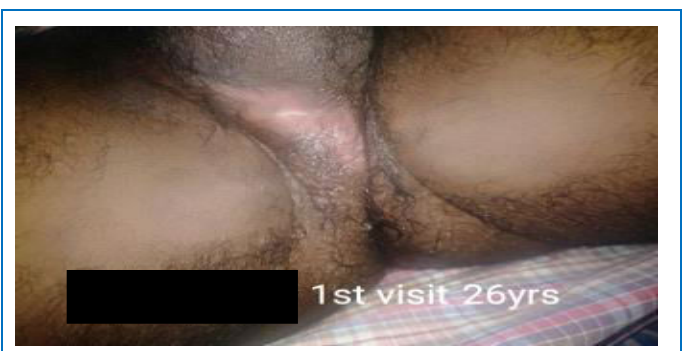Arka Ksheera + Apamarga Kshara = 7 coatings

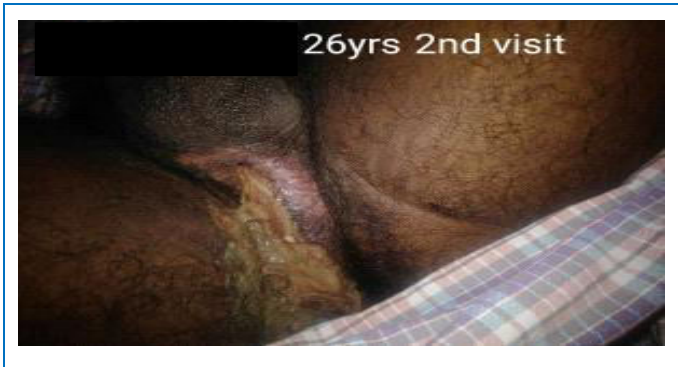
Arka Ksheera + Haridra Churna = 3 coatings

This was prepared in the hospital using barbour's linen thread No. 20, one coating was applied each day and kept for drying the *Kshara Sutra* cabinet. A total of 21 days was needed to complete the preparation of thread. After these threads were cut in 2 sizes medium length 25cm, small 16cm length and packed in a sterile sealed pack after packing in the UV cabinet with a small pack of silica inside to absorb moisture, all of these were packed in air tight container and stored keep it away from contact with any moisture.^[5] As a Pre-operative measure's patient is advised to routine investigations like CBP, CT BT, RBS, HIV, HbSAg, complete urine examination was done, all reports found within normal limit. Then patient consent was taken and posted for the *Ksara Sutra* application.

Pre-operative

Kshara Sutra prepared with *Apamarga* as per standard protocol was used. before application *Kshara Sutra*, patient was advised for part preparation. Followed by Inj T.T. 0.5 ml and plain 2% xylocaine test dose were done.

On first day of consultation.

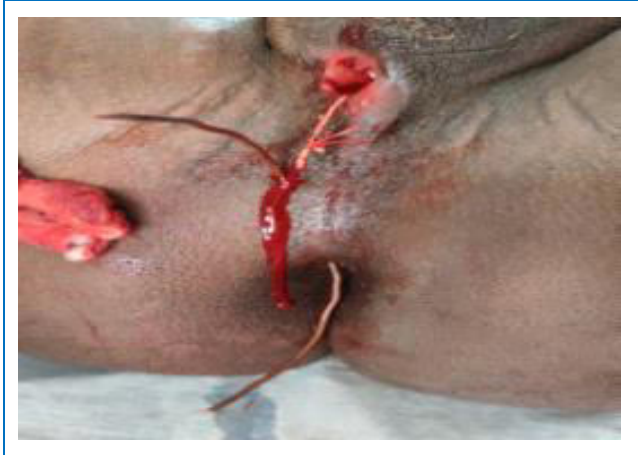
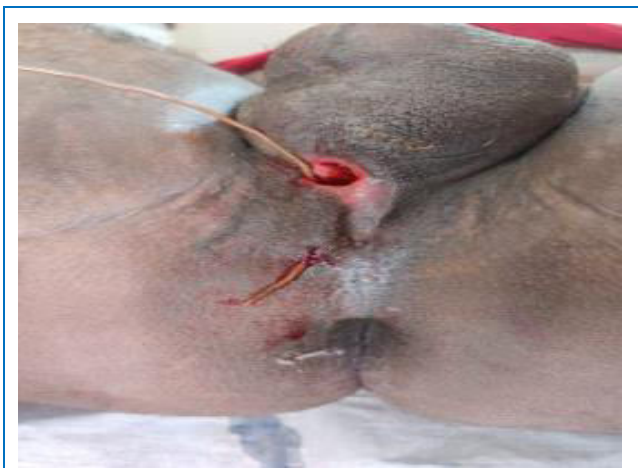
Operative Procedure

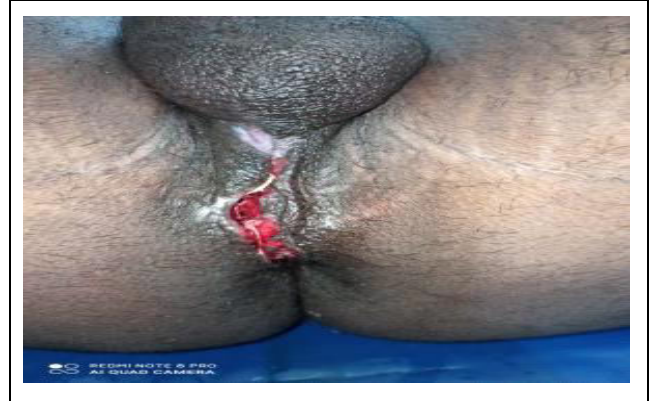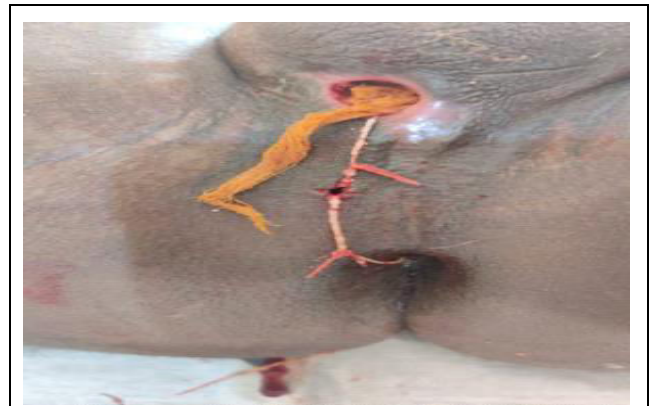Patient was taken in lithotomy position on operation table after proper painting and draping, Inj 2% xylocaine was infiltrated nearby anogenital space.

Reassessment of extension of tract was done by probing. Probe was removed through the external opening of scrotum at 11 o' clock position to internal opening. *Kshara Sutra* was tied covering the entire underlying track for cutting and healing. All aseptic precautions and haemostasis were maintained.

Probing



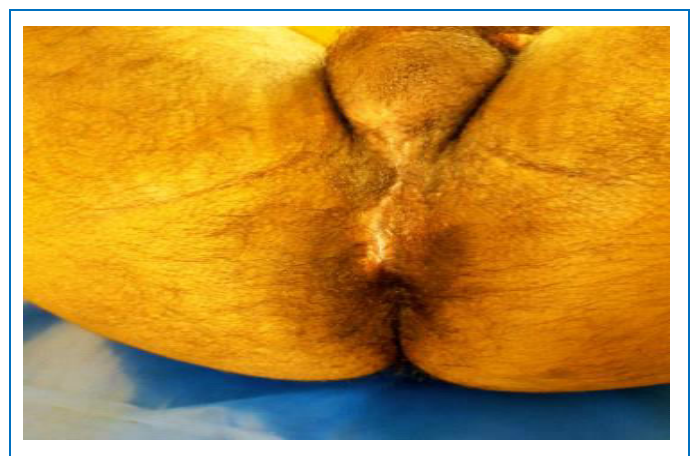Kshara Sutra Ligation



Post-operative

Kshara Sutra changed every week promotes healing and to reduce pain and inflammation. *Triphala Guggulu, Gandhaka Rasayana, Arogya Vardini Vati, BD* were Prescribed.

After complete Healing Scar formation



Follow up

Asked patient for changing *Kshara Sutra* every 7th day till cutting of the tract. hot sitz bath with *Triphala Churna, Yashtimadhu Taila* local application was done

after 6 settings tracts was totally cut out and healing was achieved simultaneously.

OBSERVATION

The initial length of track was 8cm. which got cut through in 1 month 13 days. After cut through of track patient was followed up for 2 months weekly. No sign and symptom of recurrence were observed.

CONCLUSION

Now a days *Kshara Sutra* is the first choice of treating the cases of fistula in ano especially in recurrence and complex high anal fistulas with scrotal extension *Kshara Sutra* requires minimal setup, equipments, and instruments minimal invasive para surgical measures, and also to achieve the goal of treatment it is necessary to practice *Kshara Sutra* therapy by surgeons. It helps in formation of healthy granulation tissue there by inducing a long healing pattern in depth of tissue, it also removes fibrous tissue and ultimately drains creating a healthy base for healing tract.

REFERENCES

1. Shastri Kaviraj Ambikadatta, Sushruta Samhita, Ayurveda Tatva Sandeepika, 2016 edition, Varanasi,

Chaukhambha Sanskrit Samsthana, Nidana Sthana,4/4, page no,317

2. Shastri Kaviraj Ambikadatta, Sushruta Samhita, Ayurveda Tatva Sandeepika, Hindi commentary, 1997th edition, Reedition 2016, Varanasi, Chaukhambha Sanskrit Samsthana, Sutrasthana,30/4-5, page no,165
3. Shenoy K Rajgopal, Shenoy Anita, Manipal Manual of Surgery, 4th edition 2014, New delhi, CBS Publishers, p799
4. Shastri Kaviraj Ambikadatta, Sushruta Samhita, Ayurveda Tatva Sandeepika, 2016 edition, Varanasi, Chaukhambha Sanskrit Samsthana, Sutrasthana,11/3,p-45
5. Deshapande, P G Pathak SN, The treatment of Fistula in ano with kshara sutra treatment, Nagarjuna edition, Varanasi, 1965; p 361- 367.

How to cite this article: Dr. Ashok Naikar, Dr. Vanita, Dr. C. Halli. A Clinical Study of Apamarga Kshara Sutra in the Management of Bhagandara - A Case Study. J Ayurveda Integr Med Sci 2021;1:352-355.

Source of Support: Nil, **Conflict of Interest:** None declared.

Copyright © 2021 The Author(s); Published by Maharshi Charaka Ayurveda Organization, Vijayapur (Regd). This is an open-access article distributed under the terms of the Creative Commons Attribution License (<http://creativecommons.org/licenses/by/4.0>), which permits unrestricted use, distribution, and reproduction in any medium, provided the original work is properly cited.