



ISSN 2456-3110

Vol 6 · Issue 4

July-Aug 2021

Journal of
**Ayurveda and Integrated
Medical Sciences**

www.jaims.in

JAIMS

An International Journal for Researches in Ayurveda and Allied Sciences



Maharshi Charaka
Ayurveda

Indexed

A Leech Application in Post Covid Thrombosed Hemorrhoids with Increased D'dimer Level - Case Study

Rahul Baviskar¹, K Rajeshwar Reddy²

¹Ph.D (Scholar), HOD, Professor, Dept. of Shalya Tantra, Smt. K.C. Ajmera Ayurved Mahavidyalay, Deopur, Dhule, Maharashtra, India.

²Associate Professor, Dept. of Shalya Tantra, M.A. Podar Ayurved Medical Collage, Worli, Mumbai, Maharashtra, India.

ABSTRACT

One of the main risks associated with infection by the novel corona virus (COVID-19) are thrombotic or circulatory complications. The coagulopathy with COVID-19 is a result of the Systemic inflammatory response to SARS-CoV-2 infection, this systemic inflammatory response to the Covid 19 Virus, there is injury to the vascular endothelial lining. Vertical veins e.g., hemorrhoidal veins are more prone for this type of injury resulting in thrombosis in hemorrhoidal veins. Leech saliva acts at both the site anti-inflammatory enzymes in the saliva of leech prevents further vascular injuries on the other hand it also thrombolysed blood clots within the vessels and thus helps to reduce the D'Dimer levels also. Series of few patients of post covid thrombosis (thrombosed hemorrhoids) were subjected to leech application which gave encouraging results. It showed remarkable decrease in D'dimer and thrombosis also.

Key words: Post Covid Thrombosis, Leech therapy, D'dimer levels, Thrombosed Hemorrhoids.

INTRODUCTION

Thrombosed piles are usually commoner in winter season. Surprisingly we started getting thrombosed external hemorrhoids cases even in summer 2021. Incidentally news was also there in the medical community about increased incidence of thrombotic episodes in Covid pandemic.

Address for correspondence:

Dr. Rahul Baviskar

Ph.D (Scholar), HOD, Professor, Dept. of Shalya Tantra, Smt. K.C. Ajmera Ayurved Mahavidyalay, Deopur, Dhule, Maharashtra, India.

E-mail: rahiba79@gmail.com

Submission Date: 19/07/2021 Accepted Date: 16/08/2021

Access this article online

Quick Response Code



Website: www.jaims.in

Published by Maharshi Charaka
Ayurveda Organization, Vijayapur,
Karnataka (Regd) under the license CC-
by-NC-SA

Putting two plus two together, we have analyzed 14 such cases, which reach our OPD during two-month period of April and May in contrast to the 2 cases in the same time period last year 2020.

In this Covid pandemic while doing pile mass dissection. We are finding small thrombus inside the external plexus of hemorrhoids; even on careful local examination we are able to palpate small nodules of blood clots in the pile mass.

In the last 2 month we came across 14 such cases out of which 9 patients had history of Covid in the last month. Three had history of Vaccination. 2 patients didn't have any history

Post Covid thrombosis is known entity. It should be searched and always kept in mind while examining hemorrhoids in this covid 19 pandemic

Clot formation proving fatal even after recovering from Covid 19.

Thrombosis is happening as sequel of systemic inflammatory response to the Covid 19 Virus. As a result of inflammatory response there is injury to the vascular endothelial lining resulting in;

1. Thrombocytopenia
2. Thrombin Formation
3. Diminution of natural antithrombotic responses
4. Raised levels Of D'dimer (4 to 5 times Higher than the normal)

Studies shows approximately 50% of the covid Positive patients suffer from thrombotic disorders. This thrombosis usually occurring around 30 to 60 days after the covid positivity. Veins are more affected than the arteries.

Atypical Manifestation of this thrombosis is thrombosis of external hemorrhoidal plexus. This thrombosis is definitely different from the IVth degree prolapsed thrombosed hemorrhoids

1. Usually occurs in cold weather.
2. Internal as well as external plexus is affected by thrombosis.
3. Sphincter s are in spasm due to which venous congestion occurs resulting in thrombosis in Prolapse part of internal pile mass and also in external pile mass.
4. In these cases, per rectal digital examination is severe painful or difficult.

In contrast

Post covid thrombosis of external plexus

1. This type of thrombosis is occurring in summer / hot weather also
2. Mostly external hemorrhoidal Plexus is showing thrombosis
3. Anal Sphincters are not in Spasm
4. Per-rectal digital examination can be done without much more pain

So, this is definitely a different from thrombosed prolapsed hemorrhoids.

Do Ayurveda have answer / Solution/ treatment to this new challenge to mankind?

Yes, it is there in the form of Leech Application

While describing indications of Different types of Raktamokshana, *Aacharya Vagbhata* have clearly mentioned these conditions of thrombosis and suggested that *Grathith* blood (thrombosed), *Avgadh* Coagulated blood should be removed with the help of *Jalauka* (Leech) while as *Pindit* blood (Small Hematoma) should be excised.

While sucking blood leech secretes it's saliva into the patient's body. This saliva contains different enzymes which have several beneficial effects that can fight against the complications of the Covid-19 such as;

1. Hirudin - Inhibits blood coagulation by binding to thrombin.
2. Calin (saratin) Inhibits blood coagulation by blocking the binding of von Will brand factor to collagen Inhibits collagen - mediated platelet aggregation
3. Destabilase - Dissolves fibrin Thrombolytic effects
4. Bdelins & Eglins Anti-inflammatory can act against the systemic inflammatory response to covid 19 Virus.
5. Factor Xa inhibitor Inhibits the activity of coagulation factor Xa by forming equimolar complexes
6. Complement inhibitors May possibly replace natural complement inhibitors if they are deficient.

Thus, contents of leech saliva can very well fight against the Pathology of thrombosis.

- Acting against the systemic inflammatory response to the Covid 19 Virus.
- Prevention of thrombus formation.
- Dissolving thrombin (thrombolysis).

CASE STUDY

On 17th May 2021, 66 yrs. old male patients came with the complaints of three swellings at anal verge

since last 5 to 7 days Painful. History of taken treatment from local general practitioner for piles but didn't had relief. On careful history taking patient admitted that he had fever and covid like symptoms one month back and then he was treated by with oral antiviral drugs.

On local examination it was found that there was skin covered three large swellings at 3, 7, 11 O'clock position approximately of size 5x4x4 cm. With very small area covering the internal segment of corresponding pile mass.

On palpation they were little bit tender with firm consistency.

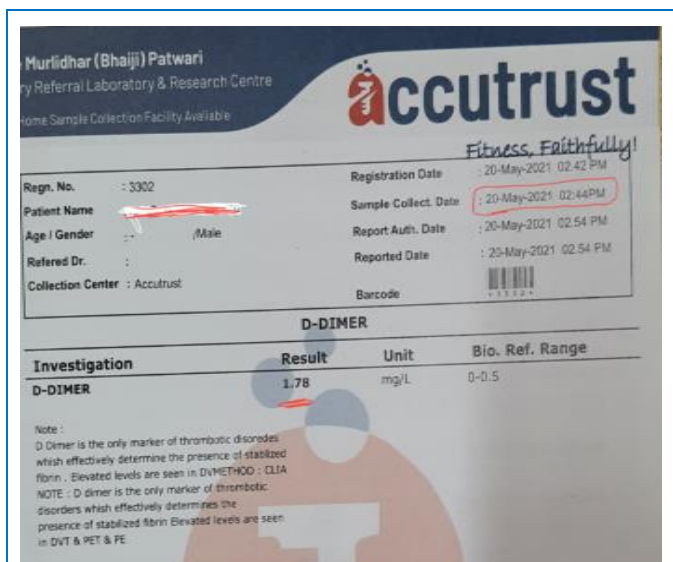There was no sphincter spasm

Per rectal digital exam was NAD except small portion of internal pile mass firm thrombosis.

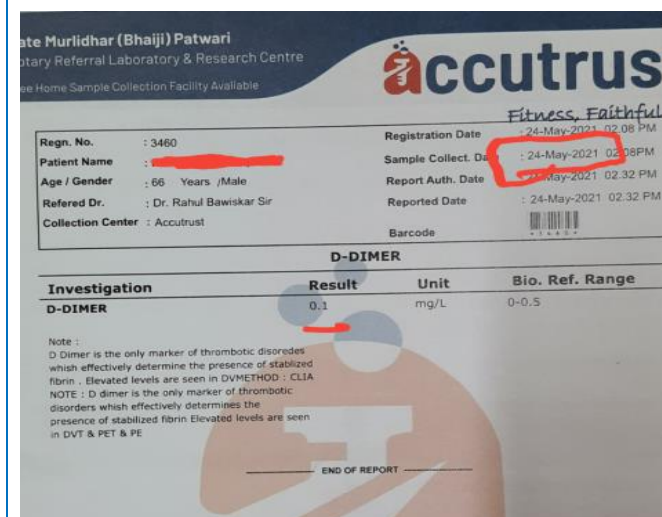
Diagnosis was Post Covid Thrombosis of external plexus of hemorrhoids.

Treatment

- Leech Application daily for 5 days
- Antibiotics and analgesics to avoid secondary infection
- Low molecular weight Heparin SC. For 3 days
- With leech therapy D'dimer went down from 3.9 to 0.1
- Photographic evidences are as follows.



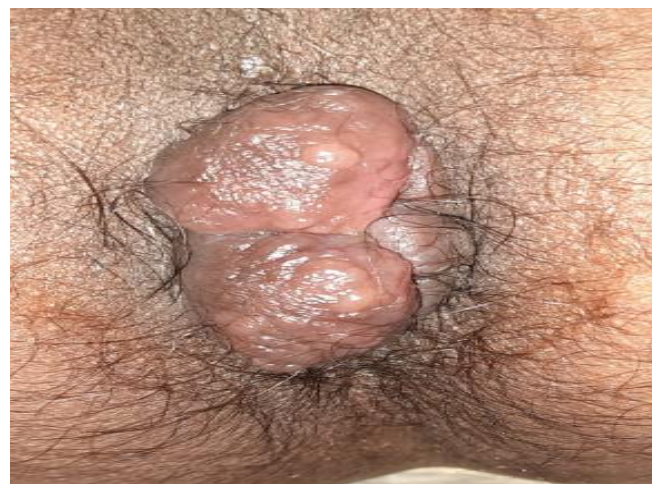Day 3



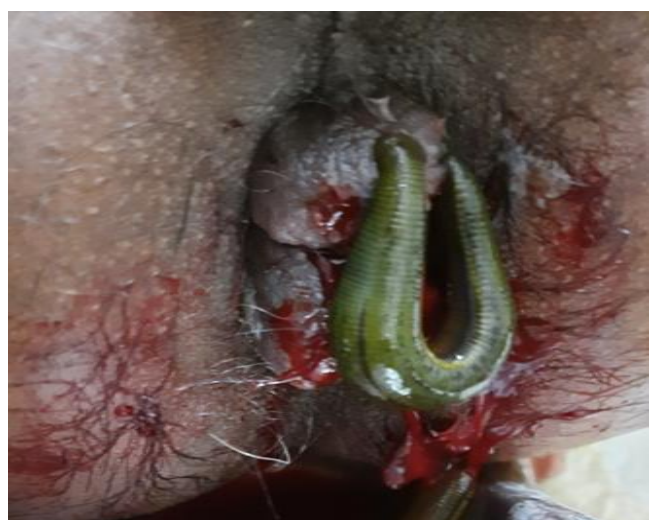Day 6



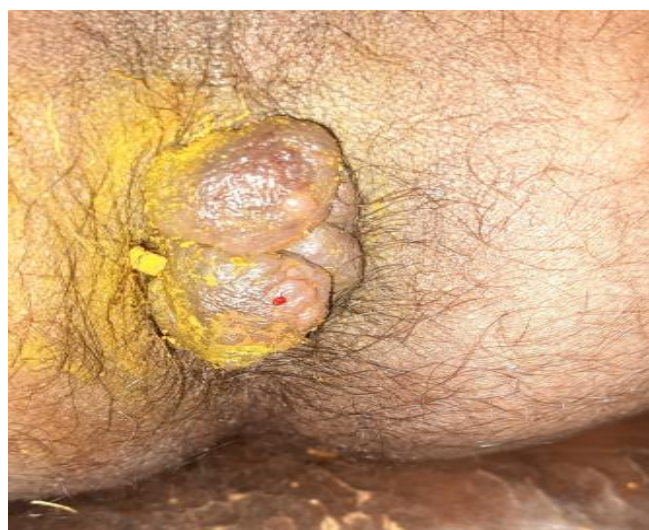Day 1



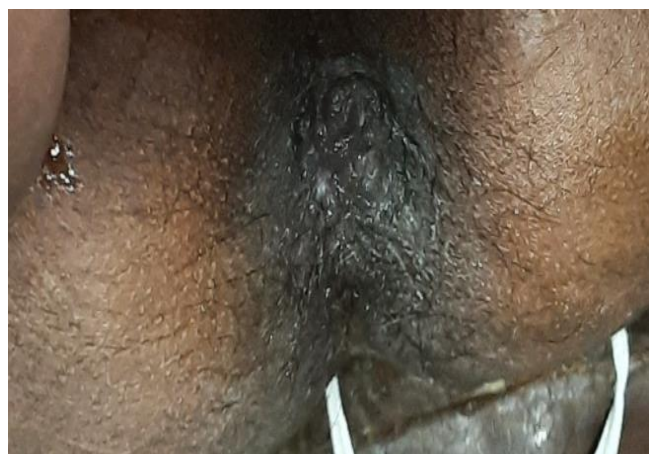
Day 1



Day 2



Day 3



Day 6

CONCLUSION

Post Covid Thrombosis in hemorrhoidal plexus is a commoner presentation in this pandemic. Mostly external hemorrhoidal plexus is involved. If thrombosed hemorrhoids occur other than winter season causes of coagulopathy should be investigated and treated accordingly. Leech Saliva is an effective tool in treating thrombosis. Leech application also helps in reducing D'dimer levels. Effect of Leech therapy on active cases of Covid-19 should be investigated as the basic pathology involves

REFERENCES

1. Markwardt F. Pharmacology of hirudin: One hundred years after the first report of the anticoagulant agent in medicinal leeches. *Biomed Biochim Acta* 1985; 44: 1007–1013.
2. Baskova IP, Zavalova LL. Proteinase inhibitors from the medicinal leech *Hirudo medicinalis*. *Biochemistry* 2001; 66: 703–714.
3. Harsfalvi J et al. Calin from *Hirudo medicinalis*, an inhibitor of von Will brand factor binding to collagen under static and flow conditions. *Blood* 1995; 85: 705–711
4. Muller IW. *Handbuch der Blutegeltherapie*. Heidelberg: Haug: 2000
5. Sawyer RT. *Leech Biology and Behaviour*. Oxford: Clarendon; 1986.
6. Barnes CS et al. Production and characterization of saratin, an inhibitor of von Willebrand factor – dependent platelet adhesion to collagen. *Semin Thromb Hemost* 2001; 27: 337–348.
7. Ganesh Krushn Garde. Sarth Vagbhat, Chaukhamba Surbharati Prakashan, edition-2015, Sutrasthan Adhyay 26/53-54 p.103
8. Ambikadattashashtri. *Sushrut samhita*, reprint 2074, Sutrasthan Adhyay 13.p.56-61

How to cite this article: Rahul Baviskar, K Rajeshwar Reddy. A Leech Application in Post Covid Thrombosed Hemorrhoids with Increased D'dimer Level - Case Study. *J Ayurveda Integr Med Sci* 2021;4:368-371.

Source of Support: Nil, **Conflict of Interest:** None declared.