



ISSN 2456-3110

Vol 6 · Issue 4

July-Aug 2021

Journal of
**Ayurveda and Integrated
Medical Sciences**

www.jaims.in

JAIMS

An International Journal for Researches in Ayurveda and Allied Sciences



Maharshi Charaka
Ayurveda

Indexed

A critical study on *Urdhwashakhagata Vaikalyakara Marma*

Mahesh KS¹, Krishnamurthy N²

¹Final year Post Graduate Scholar, Department of Shareera Rachana, Shri Dharmasthala Manjunatheshwara College of Ayurveda, Kuthpady, Udupi, India.

²Professor & Head, Department of Shareera Rachana, Shri Dharmasthala Manjunatheshwara College of Ayurveda, Kuthpady, Udupi, India.

ABSTRACT

Marma is considered as the vital point present in the human body which has life in it and the injury to these spots leads to death or death like miseries. In our classics, 107 *Marmas* are explained. They are grouped separately on the basis of structural classification, based on injury consequences, based on the *Pramana*, & based on the location in the body. Total 44 *Vaikalyakara Marmas* are present in our body among which 6 are present in each *Urdhwashakha* namely *Kakshadhara*, *Lohitaksha*, *Urvi*, *Aani*, *Koorpara* and *Kurcha*. The location, anatomical structures in specific region and effect on injury to each *Marma* differs from one another.

Key words: *Marma*, *Urdhwashakhagata Vaikalyakara Marma*.

INTRODUCTION

Marma Shareera is one of the important topics discussed in *Ayurveda*. It is illustrated as the vital points in the human body where *Mamsa*, *Sira*, *Snayu*, *Asthi* and *Sandhi* along with the *Prana* resides.^[1]

They are classified according to *Marma Vastu*, location, *Pramana*, and effect of injury.

Parinama Bhedena (based on injury consequences) it is classified into 5 types. *Vaikalyakara Marma* is one among this classification. *Urdhwa Shakhagata Vaikalyakara Marma* are 6 in number. They are *Kurcha*, *Koorpara*, *Aani*, *Urvi*, *Lohitaksha* and

Kakshadhara.^[2]

Present work is been taken up with an idea of updating the concept of *Urdhwashakhagata Vaikalyakara Marma* in view of regional anatomy. The descriptions of *Viddha Lakhanas* of these *Marmas* are available in our classics and it is explored in detail with the help of contemporary science.

Need for detailed evaluation of each *Marma* in the preview of anatomy, pathology, and traumatology. The present study was intended to evaluate the relevancy and systematic description of the *Urdhwashakhagata Vaikalyakara Marma*. Thus, it can contribute in the field of traumatology and *Ayurveda*.

Address for correspondence:

Dr. Mahesh KS

Final year Post Graduate Scholar, Department of Shareera Rachana, Shri Dharmasthala Manjunatheshwara College of Ayurveda, Kuthpady, Udupi, India.

E-mail: mahasha0150@gmail.com

Submission Date: 21/07/2021 Accepted Date: 23/08/2021

Access this article online

Quick Response Code



Website: www.jaims.in

Published by Maharshi Charaka Ayurveda Organization, Vijayapur, Karnataka (Regd) under the license CC-by-NC-SA

METHODOLOGY

- Literatures regarding the *Urdhwashakhagata Vaikalyakara Marma* were collected from the literary works, books, and journals including all published materials on concept related to the subject.
- Dissection was done in the upper limb region to study the regional anatomy of the *Urdhwashakhagata Vaikalyakara Marmas*.

DISCUSSION**1. Kakshadhara Marma****Discussion on the location**

Kakshadhara Marma is located in between *Kaksha* (armpit) and *Vaksha* (chest). It can be considered as the axillary region where the 2nd part of axillary artery surrounded by the cords of brachial plexus along with axillary vein can be considered.

Discussion on Marma Vasthu

Kakshadhara is *Snayu Marma*.

Snayu Marma Vastu - Lateral, medial and posterior cords of brachial plexus.

Sira Marma Vastu - 2nd part of axillary artery with its branches, axillary vein with its tributaries.

Mamsa Marma Vastu - pectoralis major, pectoralis minor muscles.

2. Lohitaksha Marma**Discussion on location**

Lohitaksha Marma is located above the *Urvi*, below the *Kaksha Sandhi* in the *Baahumoola*. The brachium or the arm is considered from the lower border of teres major muscle. Above that region is considered as axilla. Therefore, the *Baahumoola* can be considered as the region of third part of axillary artery.

Discussion on Marma Vasthu

Sira Marma Vastu - axillary artery (3rd part) with its 3 branches namely subscapular, anterior and posterior circumflex humeral arteries, axillary vein with its tributaries.

Snayu Marma Vastu - branches of the cords of the brachial plexus

Mamsa Marma Vastu - pectoralis major muscle

3. Urvi Marma**Discussion on location**

Urvi Marma is located in the middle of arm (*Baahu*). But it is not clear whether it is anterior or posterior or

medial or lateral. Therefore, the structures located in the middle of the arm on all the aspects should be considered.

Discussion on Marma Vastu**Anteriorly**

Sira Marma Vastu - brachial artery with 2 venae comitantes

Mamsa Marma Vastu - biceps brachii and brachialis

Snayu Marma Vastu - median nerve and musculocutaneous nerve

Asthi Marma Vastu - anteromedial and anterolateral surfaces of shaft of humerus.

Posteriorly

Sira Marma Vastu - profunda brachial artery

Mamsa Marma Vastu - triceps brachii

Snayu Marma Vastu - radial nerve

Asthi Marma Vastu - posterior surface of shaft of humerus

Medially

Sira Marma Vastu - Basilic vein, superior ulnar collateral artery

Mamsa Marma Vastu - Insertion of coracobrachialis

Snayu Marma Vastu - ulnar nerve

Asthi Marma Vastu - medial border of shaft of humerus

Laterally

Sira Marma Vastu - cephalic vein, anterior descending branch of profunda brachii

Snayu Marma Vastu - radial nerve

Asthi Marma Vastu - lateral border of shaft of humerus

4. Aani Marma**Discussion on location**

Aani Marma is located 3 *Angula* above the *Koorpara Marma* on both the aspects which can be taken as

anterior and posterior aspect of the lower part of arm above the elbow joint.

Discussion on Marma Vastu

Anteriorly

Snayu Marma Vastu - Biceps brachii tendon, median nerve, musculocutaneous nerve, radial nerve.

Sira Marma Vastu - brachial artery with venae comitantes

Mamsa Marma Vastu - biceps brachii, brachialis

Asthi Marma Vastu - anteromedial and anterolateral surface of lower part of shaft of humerus

Posteriorly

Snayu Marma Vastu - triceps brachii tendon, ulnar nerve

Sira Marma Vastu - posterior division of profunda brachial artery

Mamsa Marma Vastu - triceps brachii muscle

Asthi Marma Vastu - posterior surface of lower part of shaft of humerus.

5. Koorpara Marma

Discussion on location

Koorpara Marma is located in the middle of the *Bhuja*. *Bhuja* extends from *Manibandha* to *Amsa Peeta*. Thus the area of elbow joint can be considered as the location.

Discussion on Marma Vastu

Sandhi Marma Vastu - elbow joint

Snayu Marma Vastu - ligaments of elbow joint, median nerve, radial nerve, tendon of biceps brachii, bicipital aponeurosis

Sira Marma Vastu - termination of brachial artery dividing into radial and ulnar arteries, median cubital vein, venae comitantes following the artery.

Asthi Marma Vastu - lower end of humerus, upper end of ulna, radial head.

6. Kurcha Marma

Discussion on location

Above the *Kshipra Marma* on both the sides the *Kurcha Marma* is located. This can be considered as the region of palmar and dorsal aspects of the hand, 4 *Angula* in diameter.

Discussion on Marma Vastu

On palmar aspect

Snayu Marma Vastu - palmar aponeurosis, tendon of flexor digitorum superficialis & profundus, median & ulnar nerves in hand.

Sira Marma Vastu - superficial & deep palmar arches.

Mamsa Marma Vastu - Lumbricals, palmar interossei

Asthi Marma Vastu - metacarpals

On dorsal aspect

Snayu Marma Vastu - tendon of extensor digitorum, extensor digiti minimi, extensor indices, radial & ulnar nerves.

Sira Marma Vastu - dorsal venous arch

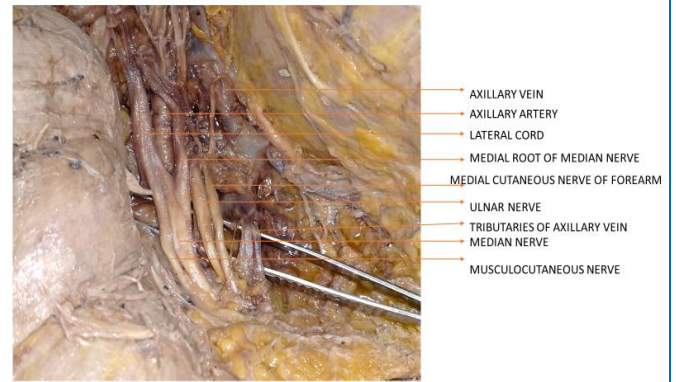
Mamsa Marma Vastu - dorsal interossei

Asthi Marma Vastu - metacarpals.

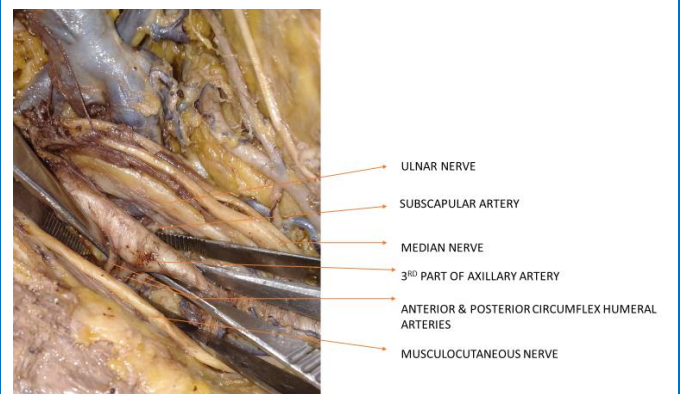
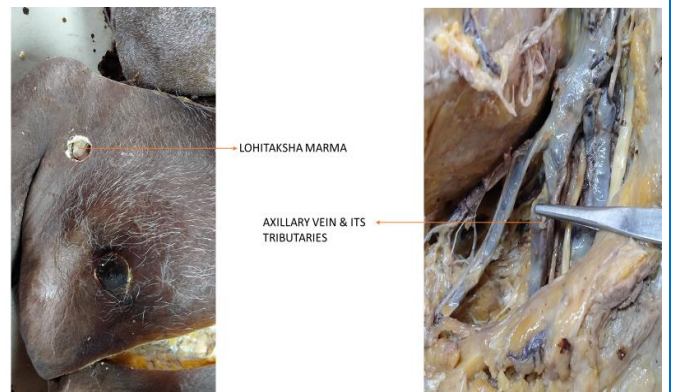
CONCLUSION

The upper limb can be considered as the *Urdhwashakha* which includes the axilla, the arm, the elbow joint, the wrist joint and the hand. The region of axilla where the 2nd part of axillary artery is located can be taken as the location of *Kakshadhara Marma*. Injury to the cords of brachial plexus located in this region leads loss of movements of upper limb which can be considered as *Pakshaghata*. The region of axilla where the 3rd part of axillary artery is located can be taken as the location of *Lohitaksha Marma*. Vascular injuries of axillary vessels may lead to severe loss of blood and death. *Pakshaghata* of upper limb may be due to acute ischemia. The mid part of arm region can be considered as the location of *Urvi Marma*. It may be on anterior or posterior or medial or lateral aspects. Injury to brachial artery with venae comitantes or profunda brachii artery or superior


ulnar collateral artery or anterior division of profunda brachial artery respectively may be the cause for severe loss of blood leading to ischemia and contractures of upperlimb. The lower part of arm both on anterior and posterior aspects, 3 *Angula* above the elbow can be considered as the location of *Aani Marma*. Injury to this leads to *Shopha* (swelling) and *Stabdhasathita* (restricted movements of the limb) may be due to the biceps and triceps tendons anteriorly and posteriorly respectively. The elbow joint region can be taken as the location of *Koorpara Marma*. Injury to *Koorpara Marma* leads to *Kuntitva* (shortness of the limb) can be correlated to the consequences of fractures and dislocations of elbow joint and its complications. The palmar and dorsal aspects of the hand 2 *Angula* above the *Kshipra Marma* can be considered as the location of *Kurcha Marma*. Injury to it leads to *Bhramana* (rotation) and *Vepana* (tremors) which can be related to various deformities of hand as Dupuytren's contracture, claw hand deformity, wrist drop which occurs due to involvement of contracture of palmar aponeurosis, median & ulnar nerves injury and radial nerve in hand.



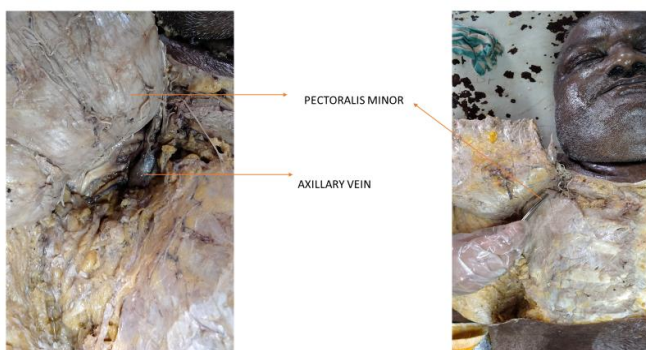
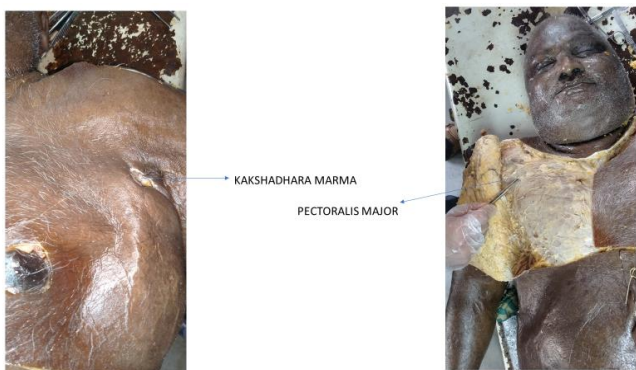
Lohitaksha Marma



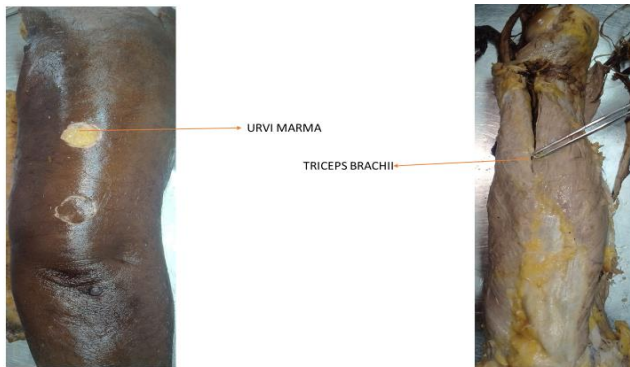
Urvi Marma - Anterior Aspect



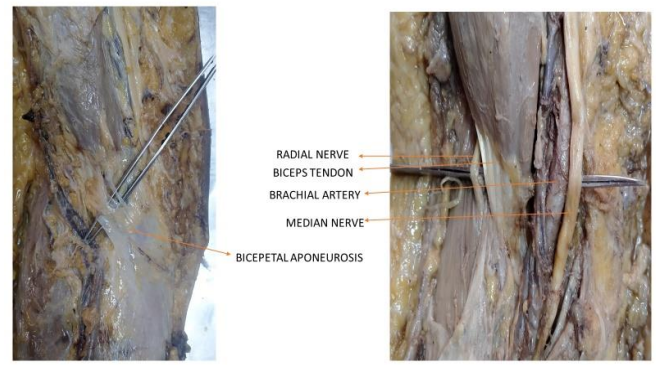
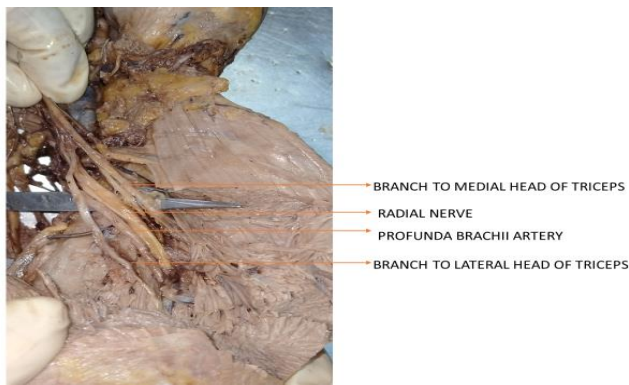
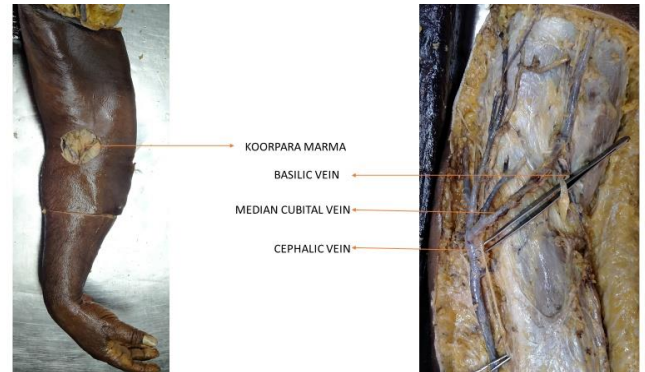
Kakshadhara Marma



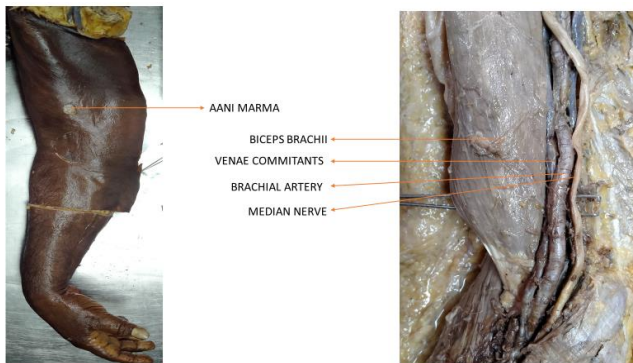
Urvi Marma - Posterior Aspect



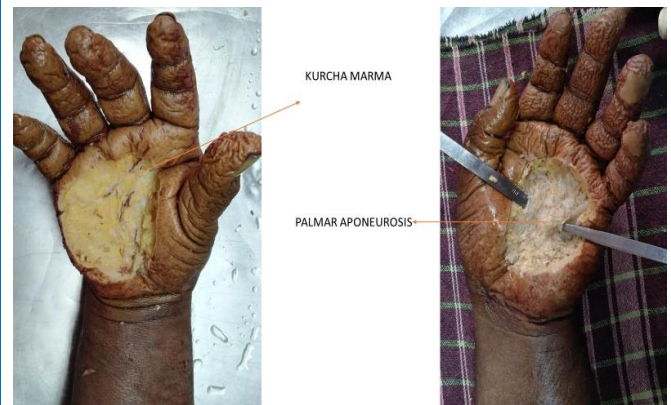Koorpara Marma



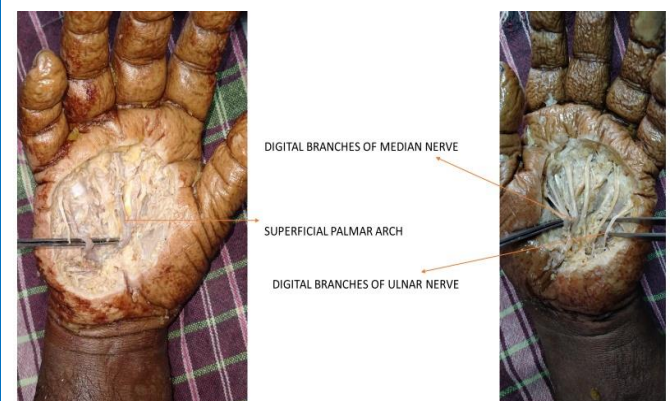
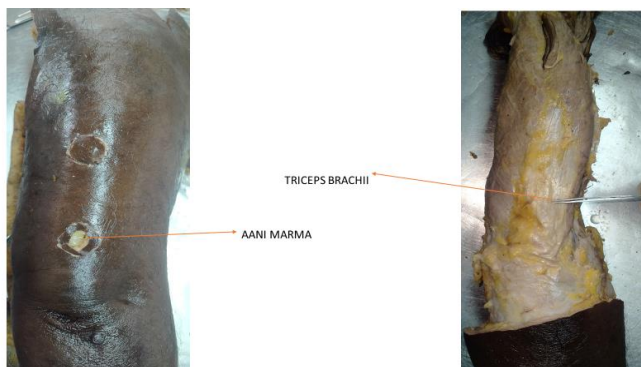Aani Marma - Anterior Aspect

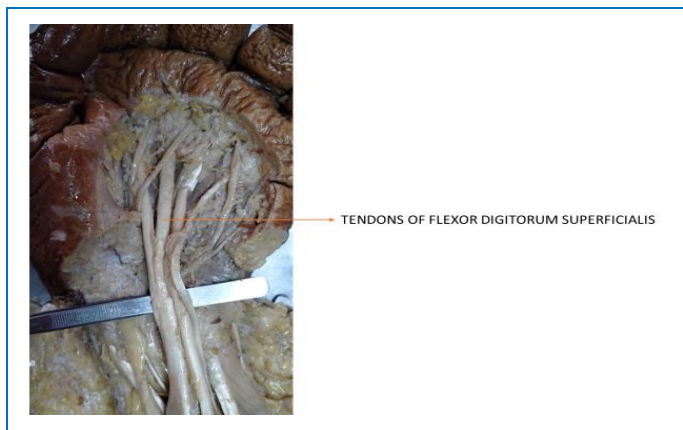

Koorcha Marma - Anterior Aspect

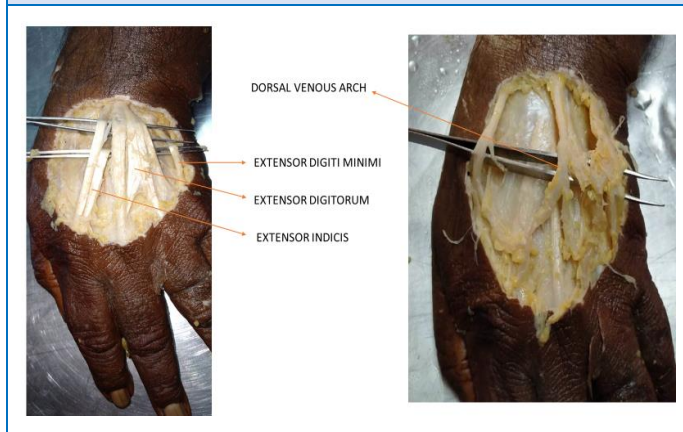


Aani Marma - Posterior Aspect





Koorcha Marma - Posterior Aspect



REFERENCES

- 1. Sushruta, Yadavji Trikamji Acharya, editor. Sushruta Samhita with Nibandha Sangraha of Dalhanacharya. 8th ed. Varanasi: Chaukhambha Orientalia; 2008. Pp824, p369.
- 2. Sushruta, Yadavji Trikamji Acharya, editor. Sushruta Samhita with Nibandha Sangraha of Dalhanacharya. 8th ed. Varanasi: Chaukhambha Orientalia; 2008. Pp824, p375.

How to cite this article: Mahesh KS, Krishnamurthy N. A critical study on Urdhwashakhagata Vaikalyakara Marma. J Ayurveda Integr Med Sci 2021;4:190-195.

Source of Support: Nil, **Conflict of Interest:** None declared.

Copyright © 2021 The Author(s); Published by Maharshi Charaka Ayurveda Organization, Vijayapur (Regd). This is an open-access article distributed under the terms of the Creative Commons Attribution License (<https://creativecommons.org/licenses/by-nc-sa/4.0>), which permits unrestricted use, distribution, and perform the work and make derivative works based on it only for non-commercial purposes, provided the original work is properly cited.