



ISSN 2456-3110

Vol 7 · Issue 1

Jan-Feb 2022

Journal of  
**Ayurveda and Integrated  
Medical Sciences**

*www.jaims.in*

**JAIMS**

An International Journal for Researches in Ayurveda and Allied Sciences



**Maharshi Charaka**  
Ayurveda

Indexed

# Observational anatomical study of *Mamsdhara Twacha* with special reference to *Vidradhi*

Mohini D. Deshpande<sup>1</sup>, Vinod M. Choudhari<sup>2</sup>

<sup>1</sup>Post Graduate Scholar, Dept. of Rachana Sharir, Shri. Ayurved Mahavidyalaya, Nagpur, Maharashtra, India.

<sup>2</sup>Professor and HOD, Dept. of Rachana Sharir, Shri. Ayurved Mahavidyalaya, Nagpur, Maharashtra, India.

## ABSTRACT

Ayurveda means science of life; it's not only curative but also preventive. Detail knowledge of human body is necessary for the wellbeing of the body, after getting knowledge about the entities of the body; one is able to know about the factors which are useful of the body. *Sharir Rachana* includes structural and numeric *Asthi, Sandhi, Peshi, Sira, Snayu, Dhamani, Stotasa, Koshtanga, Twacha, Kala, Marma, Kurcha, Jalaka, Kandara, and Indriya* etc. Amongst all these, *Twacha* is very important *Dnyanendriya* which occupies all other *Indriyas* and whole body. Today whole world is familiar about most of the modern concept of skin, but still many concepts about *Twacha* (skin) mentioned in various *Ayurvedic* text is yet to disclose. In this study an attempt is made to explore the hidden concept about *Twacha Sharir* such as formation and development of skin (*Twacha Uttapti*) skin layers and its associated disorder.

**Key words:** *Twacha, Mamsadhara Twacha, Vidradhi, Skin*

## INTRODUCTION

Ayurveda means science of life; it's not only curative but also preventive.<sup>[1]</sup>

Detail knowledge of human body is necessary for the wellbeing of the body, after getting knowledge about the entities of the body; one is able to know about the factors which are useful of the body.<sup>[2]</sup> *Sharir Rachana* includes structural and numeric *Asthi, Sandhi, Peshi, Sira, Snayu, Dhamani, Stotasa, Koshtanga, Twacha, Kala, Marma, Kurcha, Jalaka, Kandara, and Indriya* etc.

Amongst all these, *Twacha* is very important *Dnyanendriya*

which occupies all other *Indriyas* and whole body.<sup>[3]</sup> Today whole world is familiar about most of the modern concept of skin, but still many concepts about *Twacha* (skin) mentioned in various *Ayurvedic* text is yet to disclose. In this study an attempt is made to explore the hidden concept about *Twacha Sharir* such as formation and development of skin (*Twacha Uttapti*) skin layers and its associated disorder. *Acharya Sushruta* has described seven layers of skin and corresponding disease of those layers of *Twacha* and its *Praman*.<sup>[4]</sup> *Sushruta Acharya* has mentioned that seventh layer is the seat of manifestation of *Vidradhi Vyadhi*. Various skin diseases have been observed in hot, humid environment, poor personal hygiene and modern lifestyle. *Vidradhi* is one of them.

*Acharya Sushruta* has described seven layers of skin and corresponding disease of those layers of *Twacha* and its *Praman*.<sup>[5]</sup> According to modern science, skin is the largest organ of the body, essential to life. It consists of two major divisions.<sup>[6]</sup>

## AIM

To Study of anatomical changes in *Mamsdhara Twacha* with special reference to *Vidradhi*.

### Address for correspondence:

Dr. Vinod M. Choudhari

Post Graduate Scholar, Dept. of Rachana Sharir, Shri. Ayurved Mahavidyalaya, Nagpur, Maharashtra, India.

E-mail: vmchoudhari72@gmail.com

Submission Date: 05/01/2022 Accepted Date: 09/02/2022

### Access this article online

Quick Response Code



Website: [www.jaims.in](http://www.jaims.in)

DOI: 10.21760/jaims.7.1.5

**OBJECTIVE**

1. To study the concept of *Mamsdhara Twacha* & its relation with *Vidradhi*.
2. To study and correlate the concept of *Twacha Sharir* with modern aspect of skin.
3. To study about *Vidradhi* in detail.

**The Epidermis**

It is outer protective layer of skin and made up of epithelial cells and avascular in nature which has four or five layers depending upon the type of skin present in specific locations.

They are

1. Stratum corneum
2. Stratum lucidum
3. Stratum granulosum
4. Stratum spinosum
5. Stratum basal

**The Dermis**

It is made up of fibrous connective tissue and highly vascular in nature which has two layers

1. Papillary layer
2. Reticular layer

*Sushruta Acharya* has mentioned that seventh layer is the seat of manifestation of *Vidradhi Vyadhi*. Various skin diseases have been observed in hot, humid environment, poor personal hygiene and modern lifestyle. *Vidradhi* is one of them.

Literary study is done under four sections

- Review of *Twacha Sharir*
- Review of Anatomy of Skin
- Review of *Vidradhi Vyadhi*
- Review of Abscess

**Ayurvedic Review****Twacha**

While explaining genesis of *Twacha*, *Sushrutacharya* has given simple and accurate *Drushtanta* of *Santanika* i.e., cream on milk surface.

Seven folds or layers of covering (skin) are formed and deposited on rapidly transforming product of the combination of (semen) *Shukra* and *Shonita* (fertilized ovum) which have been thus charged with the individual soul or self in the same manner as layers are formed and deposited on the surface of (boiling) milk.<sup>[7]</sup>

**Number of Twacha (number of Twacha Sthar)**

There is a great variation in different *ayurvedic* texts regarding number of *Twacha*.

Regarding all these references we come to the conclusion that *Acharya Sushruta*, *Vagbhata Sharangdhara*, *Bhavaprakash* has stated 7 types of *Twacha* while *Acharya Charaka*, *Vridhdhavagbhata Bhela* and *Kashyapa* has stated 6 types of *Twacha*.

**Sushruta has mentioned Twak Sharir in 7 layers**

Layers	Praman	Vyadhi Aadhistan
<i>Avabhasini</i>	1/18 <sup>th</sup> <i>Vrihi</i>	<i>Varnabasyati</i> , <i>Panchvidh Chaya</i> <i>Prakashyati</i>
<i>Lohita</i>	1/16 <sup>th</sup> <i>Vrihi</i>	<i>Tilkalk</i> , <i>Nyachah</i> , <i>Vyang</i>
<i>Shweta</i>	1/12 <sup>th</sup> <i>Vrihi</i>	<i>Charmdal</i> , <i>Mashak</i> , <i>Aajgallika</i>
<i>Tamra</i>	1/8 <sup>th</sup> <i>Vrihi</i>	<i>Kilas</i> , <i>Kustha</i>
<i>Vedini</i>	1/5 <sup>th</sup> <i>Vrihi</i>	<i>Kustha</i> , <i>Visarpa</i>
<i>Rohini</i>	1 <i>Vrihi</i>	<i>Granthi</i> , <i>Apachi</i> , <i>Arbud</i> , <i>Shlipad</i> , <i>Galgand</i>
<i>Mamsdhara</i>	2 <i>Vrihi</i>	<i>Bhagandar</i> , <i>Arsha</i> , <i>Vidradhi</i>

**Modern Review of Skin**

Skin is the largest organ of the body. it has a sensory function as well as protective functions. It considerably thick, measuring about 5mm and weight is about 4.5-5kg

The skin is complex organ of the body, consisting of cellular epidermis and an underlying dermis of

connective tissue. Subcutaneous fat lies beneath the dermis.

### Skin is made up of two layers

#### 1. Outer epidermis

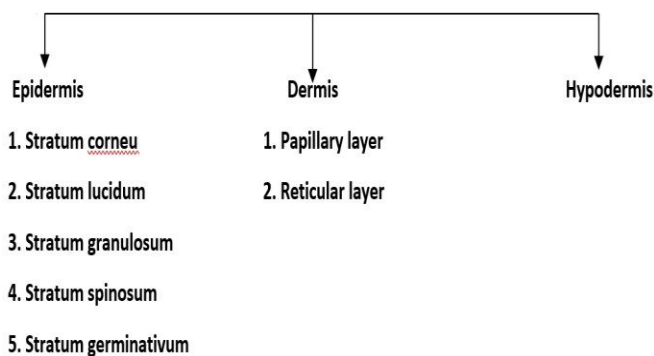
It is other productive layer of skin and made up of epithelial cells and avascular in nature.

#### 2. Inner dermis

It is made up of fibrous connective tissue and highly vascular in nature

#### 3. Hypodermis

Deep to dermis, is the subcutaneous tissue called as hypodermis,



### Ayurvedic Review of Vidradhi

- *Vidradhi* causes by indulgence in food which are state (kept overnight), very hot, dry (without moisture & fat), dried up, those causing burning sensation during digestion; laying on uneven bed, improper movement of the body parts and those (foods and activities) which cause vitiation of blood. The *Doshas* getting aggravated cause vitiation of skin, muscle, fat, bone, ligaments, blood & tendons and produce a swelling arising from them (any one or more), either outside or inside (the body) situated deep inside accompanied with severe pain; being either round or wide, this is known as *Vidradhi* (abscess).<sup>[8]</sup>
- *Acharya Sushruta* said *Twak, Rakta, Mamsa, Meda, Asthi* are the site of *Vidradhi*. The *Vidradhi* has *Mahamula, Rujavant*. The shape of *Vidradhi* is like *Vrutta* (round), *Aayat* (rectangle) It is of six kinds,

from each *Dosha* separately from the combination of all, from blood and trauma.<sup>[9]</sup>

1. *Vataj Vidradhi*
2. *Pittaj Vidradhi*
3. *Kaphaj Vidradhi*
4. *Sannipataj Vidradhi*
5. *Raktaj Vidradhi*
6. *Agantuj Vidradhi*

### Vidradhi

The *Doshas* located around the *Asthi* or bone tissue, on getting vitiated will contaminate *Twak* (skin), *Rakta* (blood), *Mamsa* (muscle) and *Meda* (fat) and will produce swelling which develops gradually and into big size and gets hard in consistency. This swelling (*Shopha*) is called *Vidradhi*. *Vidradhis* are deep located and are associated with pain. They are either round (circular) or elongated (oval) in shape.<sup>[10]</sup>

### Detail study of Vidradhi according to its types

*Vidradhis* are said to be of 6 types and are caused due to vitiated *Vata* (*Vataja*), *Pitta* (*Pittaja*), *Kapha* (*Kaphaja*), all 3 *Doshas* (*Tridoshaja* or *Sannipataja*), *Kshataja* (due to injury) and *Raktaja* (due to contaminated blood).<sup>[11]</sup>

#### 1) Vataj Vidradhi

*Vata* type of *Vidradhi* presents with thin and transparent secretions or fluid, associated with pain, hard in texture, appears black in color and inconsistent swelling which raises and goes away in an unpredictable way. Suppuration is also inconsistent. All painful blisters with serous fluid can be included in this type of *Vidradhi*.

#### 2) Pittaj Vidradhi

*Pitta* type of *Vidradhi* looks yellow in color, filled with yellow fluid or pus and is associated with burning sensation. The abscess or blister comes on quickly and suppurates quickly. All blisters with pus and infection come under this category.

#### 3) Kaphaj Vidradhi

*Kapha* type of *Vidradhi* is in the shape of *Sharava* or crucible or lid of earthen material, appears white in

color, filled with white or pale colored fluid, cold on touch, unctuous, associated with less or mild pain, slow raising and slowly suppurating abscess or blisters. Big blisters filled with clear fluid or pus fall under this category.

#### 4) Sannipataja Vidradhi

*Sannipataja Vidradhi* or abscess caused due to simultaneous vitiation of all 3 *Doshas* appear in different colors, have fluids of various colors, mixed symptoms of all the 3 *Doshas*, size of blisters vary from small to big sized ones. Blisters caused due to various causes leading from pressure to infection can be considered under this group.

#### 5) Abhighataja Vidradhi

*Abhighataja Vidradhi* (caused due to injuries) is caused due to vitiation of *Vata*, *Pitta* and *Rakta* after an injury and is associated with fever, thirst, burning sensation etc symptoms. All types of blisters caused due to friction, burning, chemical exposure and injuries fall under this category and should be dealt accordingly. Its symptoms are similar to *Pitta* type of *Vidradhi* and hence inflammatory and superlative in nature.

#### 6) Raktaja Vidradi

*Raktaja Vidradi* caused due to vitiated blood is dark black in colour and are associated with burning sensation, fever and pain. It also resembles *Pitta* type of *Vidradhi* in terms of symptoms and is also closer to blood blisters.

### Modern Review of Vidradhi

#### Abscess

An Abscess is collection of pus in any part of the body. In most of case the area around an abscess is swollen and inflamed. Abscess can form in almost any part of the body, the skin, under the skin and the teeth are the most common sites. Abscesses in the skin are easy to see they are red, raised and painful.<sup>[12]</sup>

*Vidradhi* is compared to Abscess. Abscess is a collection of pus that has built up within the tissues. It is thus a confined pocket of pus that collects in the tissues, organs or spaces inside the body. They are associated with pain, swelling and redness.

There are different types of Abscess as follows:<sup>[13]</sup>

#### Types of Abscess

- Abdominal abscess
- Amebic liver abscess
- Anorectal abscess
- Brain abscess
- Epidural abscess
- Peritonsillar abscess
- Pyogenic liver abscess
- Skin abscess
- Spinal cord abscess
- Subcutaneous abscess
- Tooth abscess

Sign and Symptoms of skin abscess include redness, pain, warmth & swelling. The swelling may feel fluid filled when pressed the area of redness often extends beyond the swelling.

Abscesses may be classified as either skin abscesses or internal abscesses, skin abscesses are common.

Skin abscesses are also called Cutaneous or Subcutaneous Abscess.<sup>[14]</sup>

#### Risk factors for Cutaneous Abscesses include the following

- Bacterial overgrowth
- Antecedent trauma (particularly when a foreign body is present)
- Immunosuppression
- Impaired circulation

Bacteria causing Cutaneous Abscesses are typically indigenous to the skin of the involved area. For Abscesses on the trunk, extremities, axillae, or head and neck, the most common organisms are *Staphylococcus Aureus* (with methicillin-resistant *S. Aureus* [MRSA] being the most common) and streptococci.

Abscesses in the perineal (i.e., inguinal, vaginal, buttock, perirectal) region contain organisms found in



the stool, commonly anaerobes or a combination of aerobes and anaerobes).

A Skin Abscess is a pocket of pus.

It is similar to a pimple, but larger and deeper under the skin. It forms when the body tries to protect itself from an infection by creating a wall around it. The pus contains bacteria, white blood cells, and dead skin. The most common bacteria are *Staphylococcus aureus* (known as "staph") and methicillin-resistant *Staphylococcus aureus* (known as MRSA). Most people carry these bacteria on their skin yet never develop an infection. However, when the bacteria penetrate the skin (through a cut, along a hair follicle, or under the edges of a wound), they may lead to an abscess.<sup>[15]</sup>

### Signs and Symptoms

A Skin Abscess is round and feels firm and squishy due to the thick membrane around it and the liquid pus inside. It is usually painful, and the overlying skin is often red. Sometimes there is a pinpoint opening in the center (a punctum). This is the weakest part of the wall and pus might spontaneously drain through it.

### Skin Abscess

A Skin Abscess is a collection of pus within the dermis or subcutaneous space. It manifests as a painful, fluctuant, erythematous nodule, with or without surrounding cellulitis. Spontaneous drainage of purulent material may occur. Regional adenopathy may be observed. Fever, chills, and systemic toxicity are unusual.

A Skin Abscess may develop via deep infection of a hair follicle (known as a furuncle or boil), which reflects extension of purulent material through the dermis into the subcutaneous tissue. Multiple furuncles can coalesce to form carbuncles which may be associated with systemic symptoms. Common areas of involvement include the back of the neck, face, axillae, and buttocks.<sup>[16]</sup>

### Skin Abscess causes

The most common cause of Skin Abscess is *S. Aureus*.<sup>[17]</sup> (either methicillin-susceptible or

methicillin-resistant *S. aureus*), which occurs in up to 75 percent of cases.

Unusual causes of Skin Abscess include nontuberculous mycobacteria; blastomycosis, nocardiosis, and cryptococcosis.

Most Abscesses are due to infection. However, sterile Abscesses can occur in the setting of injected irritants. Examples include injected drugs (particularly oil-based ones) that may not be fully absorbed and so remain at the site of injection, causing local irritation. Sterile Abscesses can turn into hard, solid lesions as they scar.

### Skin Biopsy

A skin biopsy is straight forward minor surgical procedure.

### Indications

1. Skin biopsy is taken to confirm a clinical diagnosis.
2. Sometimes, biopsy is excisional for the treatment of skin lesions particularly malignant neoplasma and other lesions for cosmetic reasons.
3. Skin biopsy may be used for a variety of investigative procedures such as ultrastructural examinations and immunochemistry, microbiological studies, tissue culture etc.

### Instruments

- 1) Biopsy punch (disposable-4mm)
- 2) Scissor
- 3) Forceps
- 4) 10% formaline for sample preservation
- 5) Plain bulb
- 6) Cotton
- 7) Xylocain 2%
- 8) Syringe with needle

### Site of Biopsy

The lesion chosen for biopsy was of an early and untreated lesion which represents the skin disorder as a whole.

If lesions are presents at all stages of evolution, it may be appropriate to biopsy more than one lesion.

Written consent was obtained from the patients and local anesthesia with 1% or 2% lignocaine with or without adrenaline was injected around the biopsy site.

### Techniques of skin biopsy

Various techniques are elliptical surgical biopsy, punch biopsy, curettage or shave biopsy among this punch biopsy was used.

### Punch biopsy technique

The biopsy punch of at least 4 to 5 mm was required to obtain satisfactory specimen. The punch was pushed into the skin with a downward twisting movement and then removed. The tissue specimen was lifted and cut.

The wound may be left to heal without suturing.

The biopsy specimen was put in 10% formalin solutions for histopathological studies.

It was properly labeled and sent to pathology department with full clinical details of the case.<sup>[18]</sup>

## RESULTS AND DISCUSSION

In the present study based of observational finding, 30 diagnosed patients of *Vidradhi* were registered.

In this study most of the patients were male 17 (56.66%) as compared to female patients 13 (43.33%). From this it is clear that the disease was slightly more common in males. This could be due to more outdoor activity of males in hot, humid polluted environment.

30 patients were ranging from 20 to 60yrs of age, divided in 4 groups. The maximum no. of patients was observed in the age group of 20 to 30yrs i.e., 14 (46.66%). Since this age group was found to be more physically active.

The disease was found to be more common in middle socio-economic patients 14 (46.66%). This could be attributed to poor hygienic practices, lowered immunity or resistance to disease and faulty life style. It was found in married group's i.e., 19 (63.33%).

Majority of patients subsisting mixed (non-vegetarian) diet 18 (60%).

Patients taking *Alpa-Ruksha Ahar* was more prone to disease i.e., 16 (53.33%). Patients doing sitting type work or *Vihar* are also prone to disease i.e., 15 (30%). Patients belongs to *Alpa Kshudha* was 16 (53.33%) and *Alpa Pipasa* was also 16 (53.33). Patients belongs to *Manda Koshta* was more prone to disease i.e., 11 (36.66%).

It was found that moderate *Shopha* (swelling) was observed in 21 (70%) patients followed by *Mahamula* of *Vidradhi* (depth of abscess) below 0.5cm in 20 (66.66%) patients.

It was found that moderate pain found in most of patients i.e., 15 (50%) and Patients having irregular shape of *Vidradhi* was high 18 (60%). From above it is stated that *Shopha*, depth of *Vidradhi*, pain and shape of *Vidradhi* are the main signs which defines the severity of *Vidradhi* which occurs in *Mamsdhara Twacha*.

In modern science for diagnostic conformation catalyze test requires to be done. In the present study in all 30 patients catalyze test was found to be positive for *Staphylococcus auries* bacteria. i.e., result is 100%. So, it confirms that the main cause of skin abscess was *Staphylococcus auries* gram positive organism.

The histopathological study shows this impression stratified squamous epithelium lining, squamous lining, lymphatic infiltrate, dilated and congested blood vessels, congested and chronic inflammatory infiltrate, congested subcutaneous tissue and muscles. According to distribution of *Vidradhi* patients showing histopathological study on skin it was found that out of 30 patients there is no inflammatory changes.

From all above we found that *Vidradhi* is closely related to *Mamsdhara Twacha*.

## CONCLUSION

On the basis of observed facts and according to discussion following factors are concluded. Some parameters are present in volunteers and some are absent in volunteers i.e., *Shopha* (swelling of abscess),

depth of abscess, pain and shape of abscess. Moderate swelling and pain present in most of volunteers. The histopathology report shows this impression stratified squamous epithelium lining, squamous lining, lymphatic infiltrate, dilated and congested blood vessels, multiple dilated and congested blood vessels, congested and chronic inflammatory infiltrate, congested and subcutaneous tissue and muscles, purulent congested subcutaneous tissue and muscles.

On the basis of observation and statistics we got positive response for these parameters.

- Moderate swelling in 24 (80%).
- Depth of abscess below 0.5cm in 20 (66.66%).
- Moderate pain in 17 (56.66%)
- Irregular shape in 18 (60%).
- Stratified squamous epithelium lining seen in 20 (66.66%)
- Subcutaneous tissue and muscles in 8 (26.66%)
- Inflammatory changes in 9 (30%).
- *Staphylococcus auries* abscess infection in 30 (100%).

So, from above finding it concludes that there are significant Anatomical Changes seen in *Mamsdhara Twacha* due to *Vidradhi*.

- There is strong correlation of origin of *Vidradhi* in *Mamsdhara Twacha*.
- The study of *Twacha Sharir* according to ayurveda and modern science in details reveals that the finding of the study is in agreement with Charaka's view regarding the number of *Twacha Sthara*.
- The study also demonstrated the relation between *Vidradhi* and abscess. As most of the signs and symptoms of *Vidradhi* are similar to abscess infection.

## REFERENCES

1. Agnivesh, Charak, Drudhbal, Charak samhita, Sutrasthan, Athdashmahamuliy 30/26 Edited by Pra.Vaidya Y.G.Joshi 4<sup>th</sup> edition 2009 vaidyamitra prakashan page no 412.
2. Agnivesh, Charak, Drudhbal, Charak samhita, Sharirasthan, Sharirvichayam Sharir 6/3 Edited by Pra.Vaidya Y.G.Joshi 4<sup>th</sup> edition 2009 vaidyamitra prakashan page no 706.
3. Article on "conceptual study of vedini twacha – sharir as a seat of Vicharchika-with related to eczema" by Dr.Balaji Jadhav PG Scholar, Department of Rachana Sharir, GAC. Nanded. article accepted on 14/06/2017
4. Sushrut Samhita, Sharir Sthan, Garbhvyakaransharir 4/4, Edited by Ambikadatta Shatri, Edition: reprint, 2014 Choukhamba Publication page no-37
5. Sushrut Samhita, Sharir Sthan, Garbhvyakaransharir 4/4, Edited by Ambikadatta Shatri, Edition: reprint, 2014 Choukhamba Publication page no-37
6. Essential of medical physiology, chapter-structure of skin, edited by, k sembulingam, prema sembulingam, 5<sup>th</sup> edition reprint 2010, jaypee brothers medical publishers (p)ltd. Page no-334
7. Sushrut Samhita, Sharir Sthan, Adhyay-Garbhvyakaran sharir 4/3, Edited by Dr. Ambikadatta Shatri, Edition: reprint, 2014 Choukhamba Publication page no-3788.
8. Vagbhatt, Sarth Vagbhatt Samhita, Astanga Hridayam, Nidan Sthan, Vidradhivrudhigulmanidanm 11/1,2 Edited by Dr.Ganesh Krushna Garde edition on 2015 Choukhamba Surbharti Prakashan, Varanasi Page no-193
9. Sushrut Samhita, Nidan Sthan, Vidradhinamnidan 9/4,5, Edited by Dr.Ambikadatta Shatri, edition: reprint, 2014 Choukhamba Publication page no-37
10. Vagbhatt, Sarth Vagbhatt Samhita, Astanga Hridayam, Nidan Sthan, Adhya-Vidradhivrudhigulmanidanm 11/3 Edited by Dr.Ganesh Krushna Garde edition on 2015 Choukhamba Surbharti Prakashan, Varanasi Page no-193
11. Vagbhatt, Sarth Vagbhatt Samhita, Astanga Hridayam, Nidan Sthan, Adhya-Vidradhivrudhigulmanidanm 11/3 Edited by Dr.Ganesh Krushna Garde edition on 2015 Choukhamba Surbharti Prakashan, Varanasi Page no-193
12. Davidson's principles & practice of medicine, the Editors Nicholas a. boon, Nicki R. Colledge, Brian R Woalker, John A. A. Hunter, illustrated by Robert Britton 20<sup>th</sup> edition 2006.



13. Abscess-  
Wikipedia <https://www.ayurvedatreatments.co.in/ayurvedatreatments/index.php/e-book-downloads>.
14. Davidson's principles & practice of medicine, the Editors Nicholas a. boon, Nicki R. Colledge, Brian R Woalker, John A. A. Hunter, illustrated by Robert Britton 20<sup>th</sup> edition 2006.
15. Davidson's principles & practice of medicine, the Editors Nicholas a. boon, Nicki R. Colledge, Brian R Woalker, John A. A. Hunter, illustrated by Robert Britton 20<sup>th</sup> edition 2006.
16. Davidson's principles & practice of medicine, the Editors Nicholas a. boon, Nicki R. Colledge, Brian R Woalker, John A. A. Hunter, illustrated by Robert Britton 20<sup>th</sup> edition 2006.
17. Davidson's principles & practice of medicine, the Editors Nicholas a. boon, Nicki R. Colledge, Brian R Woalker, John A. A. Hunter, illustrated by Robert Britton 20<sup>th</sup> edition 2006.
18. Lever's histopathology of the skin, edited by David E. Elder, Rosalie Elenitsas, Bennett I. Johnson, George F. Murphy, 10<sup>th</sup> edition reprint 2009, published by Lippincott Williams and Wilkins.

**How to cite this article:** Mohini D. Deshpande, Vinod M. Choudhari. Observational anatomical study of Mamsdhara Twacha with special reference to Vidradhi. J Ayurveda Integr Med Sci 2022;1:29-36. <http://dx.doi.org/10.21760/jaims.7.1.5>

**Source of Support:** Nil, **Conflict of Interest:** None declared.

\*\*\*\*\*