



ISSN 2456-3110

Vol 6 · Issue 6

Nov-Dec 2021

Journal of
**Ayurveda and Integrated
Medical Sciences**

www.jaims.in

JAIMS

An International Journal for Researches in Ayurveda and Allied Sciences



Maharshi Charaka
Ayurveda

Indexed

A Case Report on management of *Grahani* with special reference to Ulcerative Colitis

M.R. Poornima¹, Sarika A. K², Gadilinga³, Srinivas Masalekar⁴, Ananta S Desai⁵

^{1,2}Post Graduate Scholar, Dept. of Shalya Tantra, Government Ayurveda Medical College and SJIM Hospital, Bengaluru, Karnataka, India.

³Post Graduate Scholar Dept. of Panchakarma, Government Ayurveda Medical College and SJIM Hospital, Bengaluru, Karnataka, India.

⁴Associate Professor, Dept of Shalya Tantra, Government Ayurveda Medical College and SJIM Hospital, Bengaluru, Karnataka, India.

⁵Professor and HOD, Dept. of Panchakarma, Government Ayurveda Medical College and SJIM Hospital, Bengaluru, Karnataka, India.

ABSTRACT

Ulcerative colitis (UC) is a disease with unknown specific cause, a chronic inflammatory disease of mucosa and sub mucosa of colonic wall. Several theories have been put forward of which the main ones are infective, nutritional, psychosomatic and immunological. Ulcerative colitis can be divided into three forms according to its clinical features. These are: (i) Chronic and continuous; (ii) Chronic-relapsing-remitting and (iii) Acute fulminant. The onset of the disease is usually highest in the third decade, though second and fourth decades are often involved. A slight female predominance has been reported. The first symptom is watery diarrhoea. Abdominal pain is the next symptom and rectal discharge of mucus, sometimes blood and sometime pus is not uncommon. In Allopathic medical science, no significant treatment is there for UC. Corticosteroid, anti-diarrhoeal agents etc. are used which results in other complications too. Hence there is a need for better management of the condition. Here a case of 21yrs old male, n/k/c/o DM or HTN has been discussed who presented with c/o mucous discharge and occasionally pus discharge from Anum and loose stools since 1year, diagnosed with ulcerative colitis. The condition can be considered as *Grahani* and *Basti* treatment was being followed with *Pittahara* internal medication.

Key words: *Grahani, Basti, Pittahara, Ulcerative colitis, inflammatory disease*

INTRODUCTION

Ulcerative colitis is an ulcero-inflammatory disease affecting the colon but limited to mucosa and submucosa. Its incidence is 7 per 1,00,000 population and with a peak incidence between age 20 to 25 years.

Address for correspondence:

Dr. M.R. Poornima

Post Graduate Scholar, Dept. of Shalya Tantra, Government Ayurveda Medical College and SJIM Hospital, Bengaluru, Karnataka, India.

E-mail: mr.poornima4@gmail.com

Submission Date: 09/11/2021 Accepted Date: 16/12/2021

Access this article online

Quick Response Code



Website: www.jaims.in

Published by Maharshi Charaka Ayurveda Organization, Vijayapur, Karnataka (Regd) under the license CC-by-NC-SA

It begins in rectum and can extend proximally to involve whole colon. The presentation is usually insidious, with cramps, tenesmus, and colicky lower abdominal pain that is relieved by defecation.^[1] Numbers of stool are 30-40 per day, consisting of small amount of watery stool, mucus, blood and pus. Extreme dehydration, hypocalcaemia, anaemia, hypoproteinaemia and marked weight loss are the features of acute fulminating form of UC.^[2] In some cases, it is also associated with systemic illness as sacroiliitis, ankylosing spondylitis, uveitis, hepatic involvement and migratory polyarthritis etc. The diagnosis is confirmed by barium enema, endoscopy and biopsy. The medical treatment includes antidiarrheal (Lomotil), antibiotics (sulphasalazine), corticosteroids, multivitamins, intravenous fluid to overcome dehydration and electrolyte imbalance.

Sometimes blood transfusion is required to correct anaemia.^[3]

In Ayurveda, Ulcerative colitis can be considered as a *Tridoshaja* disease of *Purishavaha Srotasa*. *Nidana Sevana* leads to vitiation of *Pitta* along with *Vridhdhi* of *Kapha* and *Vata*. *Vridhdha Kapha* and *Vata* cause the vitiation of *Agni* leading to *Agnimandya*. Excessive consumption of *Pittaja-Ahara* (*Pitta* aggravating foods) and *Pitta* aggravating regimen leads to vitiation of *Pitta Dosha* which further cause the vitiation of *Rakta Dhatu*. *Dosha Sanchaya* takes place in *Grahani* and *Pakwashaya* (Rectum and Colon) which results in *Shula* (abdominalpain), *Shotha* (inflammation of intestine), *Atisara* (Diarrhoea), *Vrana* (Ulcers) and *Raktasraava* (bleeding per rectum) etc. Vitiating *Kapha* blocks the channels causing further inflammation, mucous accumulation and oedema. Thus, it produces symptoms.^[4]

Ayurveda described various treatment modalities for the management of ulcerative colitis such as; *Deepana-Pachana*, *Grahi*, *Stambhana*, *Raktha Vardhana* etc.

CASE STUDY

A 21year old male patient visited the OPD of the GAMC and SJIMH, Bengaluru for the complaints of frequent defecation 10-15 times per day associated with pain in abdomen, mucous mixed with stools, severe weakness, reduced appetite for 1 year. A history of the present illness revealed that the patient was apparently normal 1 year back. He started with abdominal pain watery stools 6 times per day along with mucous and weakness. The symptoms aggravated on taking spicy and heavy foods. After 6 months loose stools increased up to 10 times/day, frothy and stools stained with mucous and blood. For the same patient consulted a gastroenterologist, where the patient was diagnosed with ulcerative colitis by colonoscopy and biopsy. The patient underwent conservative management. As the patient was not getting better, he visited our hospital.

Physical examination

He looked pale and afebrile. His heart rate was 90/min, Blood pressure (110/70mm of Hg) and respiratory

rates (18/min) were normal. There was no clubbing, lymphadenopathy and skin lesion.

Abdomen was soft, mild tenderness present in lower abdomen left iliac region but there was no guarding & no organomegaly.

Rectal Examination

Inspection: small erosions with anterior and posterior fissure present. No active bleeding seen. No fistula or no external pile mass is noticed

DRE: Normal sphincter tone, no mass, blood mixed mucous discharge present on the examining finger.

Proctoscopic examination not done as patient had erosions and burning sensation.

Haematological investigations on 13.03.2021: Hb-9.6 gm/dl, total leukocyte counts $11.24 \times 10^{[3]} \mu\text{l}$

Sigmoidoscopy on 29.02.2020 showed - ulcerative colitis. Mayo endoscopic score-2, UCEIS score - 3/8, internal haemorrhoids.

Treatment

The Ayurvedic management planned was *Basti* mainly for *Deepana* (Increase digestive power), *Pachana* (Digestant), *Stambhana* (Astringent), *Grahi* (Anti-Diarrhoeal) and *Raktha Vardhana* (Increase blood).

- *Kalabasti* (medicated decoction enema) was administered for 10 days.
- *Anuvasana Basti* (medicated enema) - *Dadimadi Gritha* - 80ml
- *Niruha Basti*
- *Saindhava Lavana* (Rock salt) - 12gms
- *Madhu* (honey) - 40ml
- *Kalka - Shatapushpadi Choorna, Musta Choorna, Yashtimadhu Choorna* – 10 grams each.
- *Sneha - Dadimadi Gritha* - 80ml
- *Kashaya - Musta-Takra* - 300ml

Basti pattern

Day	1	2	3	4	5	6	7	8	9	10

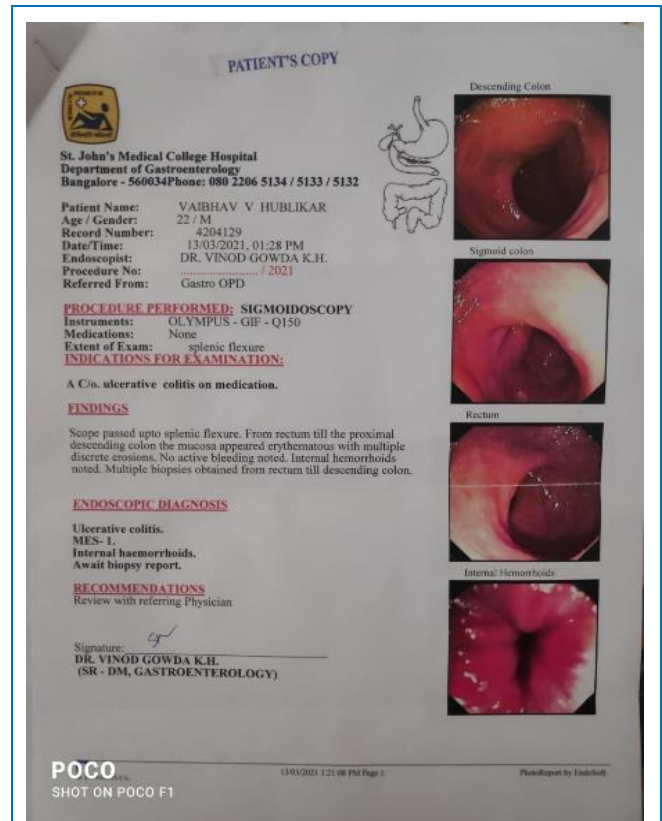
Basti	A	A	N	N	N	N	N	N	A	A
			A	A	A	A	A	A		

N - Niruha Basti, A - Anuvasana Basti

Oral medicine

1. *Dadimastaka Choorna* 5 grams tid with *Takra* (Buttermilk) after food.
2. *Pittashekhara Rasa* 1-1-1 a/f
3. *Dhatri Loha* 1-0-1 a/f
4. *Dadimadi Ghrita* 1tsp-0-0 empty stomach (after analysing agni of the patient)

He was also explained with do and don'ts of *Ahara-Vihara* (food habit and regimen) as avoidance of *Amla* (sour), spicy, fried items, Maida items (*Vistabdha* and *Vidahi*), and other *Pitta-Vardhaka Ahara, Adhyashana* (repeated eating before the prior digestion of food), *Diva-Swapna* (day time sleep), *Ratri-Jagrana* (Night awakening), sleeping after meal, over exertion, heavy meals, non-vegetarian diet etc.



After treatment

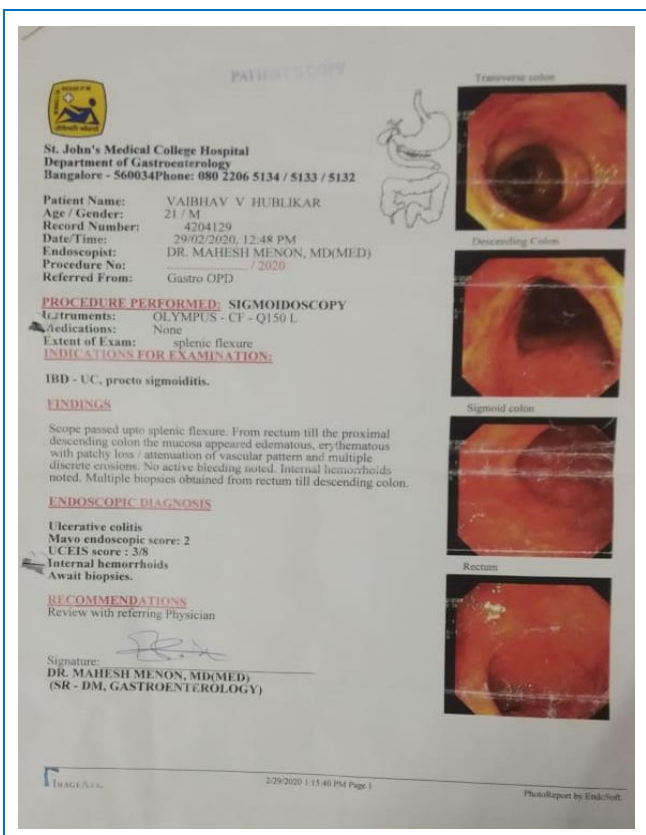
RESULT

On the 4th day of treatment, the patient reported reduction of frequency of bowel. Improvement was observed in appetite, distension and pain abdomen was relieved. On the 10th day, the frequency of bowel reduced to normal. Mucous- and blood-mixed stool was completely stopped. Improvement was noted in weakness, appetite, and reduced sleep. Complete relief was reported in all the other signs and symptoms by the patient. On the 30th day, there was no any previous complaint reported by the patient and improvement in *Bala* (general strength), *Varna* (complexion), *Agnideepti* (appetite), and body weight was achieved. The patient was on follow-up till 5 months, without any single episode of relapse.

Sigmoidoscopy done on 13.03.2021 - The grading has reduced from MES-2 TO MES-1.

DISCUSSION

Musta (*Cyperus rotundus*) has *Katu* (pungent), *Tikta* (bitter) and *Kashaya* (astringent) taste *Laghu* (light)



Before treatment

and *Ruksha* (dry) properties, *Sita* (cold) potency and *Katu* (pungent) taste after digestion. It is *Kapha-Pittahara* (reduces *Kapha* and *Pitta Dosha*), *Deepana* (increases digestive fire), *Pachana* (digests undigested material), *Grahi* (water absorbing), *Jwarahara* (antipyretic), *Atisarahna* (anti-diarrhoeal), *Kanduhara* (antipuritic), *Vrana Shodhana* and *Ropana* (Wound cleansing and Healing).^[5-8] *Cyperus rotundus* has the properties of antimicrobial activity, anti-laceration/ulcer activity, analgesic activity, anti-inflammatory activity, anti-diarrhoeal activity, antipyretic activity due to the presence of the chemical constituents such as flavonoid, Tannin, tri terpenoids, sesquiterpenes, cyperolone, cyperone, copaene, cyperene, cyperenone.^[9]

Takra (Buttermilk) - *Deepana*, *Pachana*, *Sangrahi* and *Tridosahara*. *Laghu Guna* and *Deepana* properties of *Takra* helped to correct the *Agni*. Due to its *Madhura Vipaka* helped in the balance of *Pitta*. Also, its *Vatahara* property helped to correct the vitiated *Samana Vayu*. The *Grahi* action of *Takra* subsided *Drava Mala Pravritti* which has been proved to restore the bacterial flora of the intestinal mucosa. Hence *Takra* was major diet administered throughout the course of treatment.^[10]

Dadimadigritha: It contains *Dadima*, *Dhanyaka*, *Chitraka*, *Shunthi*, *Pippali* and *Gritha*. It is *Tridosahara*, it has qualities such as *Deepana*, *Pachana*, *Raktavardaka*, so helps in proper digestion and increases *Raktha*.^[11]

Dadimastaka Choorna - *Twakshiri*, *Chaturjata*, *Yavani*, *Dhanyaka*, *Ajaji*, *Chavyamoola*, *Trikatu*, *Dadima* and *Sita* - It is *Tridosahara* does *Deepana*, its qualities include *Grahi*, *Hrdyam*, *Atisarahna*, *Soolahara* and especially *Grahanibalya* so, it helps in Digestion, improves metabolic activities, promotes appetite and it reduces loose stools. *Dadimastaka Choorna* can be used for conditions like *Grahani* where *Agnimandya* is the chief pathology.^[12]

Shatapushpa Churna (*Anethum sowa*)- reported to have antimicrobial, antibacterial, anti-inflammatory, anti hyperlipidemic, anti hypercholesterolaemic activities. Fruits of plant are reported to have antispasmodic effect on smooth muscles of GIT. The

efficacy of high dose of *Anethum sowa* extracts was reported to be similar to sucralfate. The acidity and total acid content were reported to be reduced by orally or intra peritoneally administration of extracts. It was also found to be effective to treat mylasis. The oil obtained from the fruit is official in I.P. as Dill oil. The oil and its emulsion in water are considered stomachic, diuretic, anthelmintic and antifatulent and are in important ingredient of gripe water preparations. It is found that the limonene fraction on the oil arrests general dehydrogenesis of paramoecia and helminths and is more effective than the carvone traction or the whole oil. *Shatapushpa* traditionally used in disorders wiz indigestion, excessive flatulence, anorexia.^[13]

Yastimadhu Churna (*Glycyrrhiza glabra*) - *Rasa* (Taste) - *Madhura* (Sweet)

Guna (Properties) - *Guru* (Heavy), *Snigdha* (Unctuous)

Vipaka (Post digestion effect): *Madhura* (Sweet)

Veerya (Potency) -- *Sheeta* (Cold)

Vata-Pittahara (Pacifies the aggravated / morbid *Vata* and *Pitta*). Being heavy and unctuous and possessing sweet taste and post-digestion effect, which are antagonistic to *Vata*, *Yastimadhu* pacifies (controls) it. Similarly, *Yastimadhu* pacifies the aggravated *Pitta* due to its sweet taste and post-digestion effect and also its cold potency.

The medicine also helps in healing the erosions and ulcers, prevents excess acid formation and being a mild laxative owing to its *Snigdha* and *Guru Gunas* will flush the excess *Pitta* out of the stomach and intestines. It also corrects the metabolism and aids in proper digestion and absorption of food. These further energizes the cells and restores strength and immunity of the body. The medicine also allows the recovery of gastric mucosa and musculature in quick time.^[14]

Overall, due to the improvement in *Agni* (digestion and absorption), *Bala* (strength), and *Varna* (complexion), body weight of the patient was also improved.

CONCLUSION

In this case study, Ulcerative colitis was successfully managed through Ayurveda, modern science has various treatment modalities but the complication and

relapsing of disease is most common. Ayurveda treatment can be a promising alternative, safe and convenient treatment in the management of ulcerative colitis as it can be useful for reducing the need of steroids and surgical procedures in the patient of ulcerative colitis. This treatment protocol could be explored further on larger sample and standardisation of treatment protocol can be carried out.

REFERENCES

- Robbins. Basic Pathology. 7 th ed. New Delhi: Harcourt India Pvt. Ltd.; 2003.p. 572.
- Somen Das. A concise text book of surgery. 3 rd ed. Calutta: S.Das; 2001.p.1017.
- Somen Das. A concise text book of surgery. 3rd ed. Calutta: S.Das; 2001.p. 1020.
- Acharya Vidyadhar Shukla & Prof. Ravidutt Tripathi (Author), Acharya Priy Vrata Sharma (Foreword) Charak Samhita (2 Vol.) – 1 January 2015 Hindi Edition, chikitsastana 15th chapter.
- Sastri K, editor. Caraka Samhita of Agnivesa, Sutrasthana. 5th ed., Vol. I. Varanasi: Chaukhambha Sanskrit Sansthan; 1997.
- Chunekar KC, editor. Bhavaprakasa Nighantu of Sri Bhavamisra. 1st ed. Varanasi: Chaukhambha Bharati Academy; 2004. p. 63, 127-8, 243-4
- Sastry JL. Dravyaguna Vijnana. 2nd ed., Vol. II. Varanasi: Chaukhambha Orientalia; 2005. p. 23- 32, 551-7.
- Acharya Vidyadhar Shukla & Prof. Ravidutt Tripathi (Author), Acharya Priy Vrata Sharma (Foreword) Charak Samhita (2 Vol.) – 1 January 2015 Hindi edition, chikitsastana 16th chapter/44-46.
- Kamala A, Middha SK, Karigar CS. Plants in traditional medicine with special reference to Cyperus rotundus L.: a review. 3 Biotech. 2018 Jul;8(7):309
- Priyanka Bangre & Archana Belge: Benefits Of Takra (Buttermilk) As Per Different Preparatory Methods. International Ayurvedic Medical Journal {online} 2019 {cited July, 2019} Available from: http://www.iamj.in/posts/images/upload/1189_1192.pdf
- Charaka Samhita of Agnivesa, Elaborated by Charakaand Drdhabala (Vol-II) Edited with Charaka-Chandrika by Dr Brahmanand Tripathi. Foreword by Dr Prabhakar Deshpande.
- Chaukhamba Surbharati Prakashan, Varanasi. Panduroga Chikitsadhyaya. Cha.chi.16/44-46 page no.-598.
- Shastri P, editor. Sharangadhara Samhita of Sharangadhara acharya, Madhyama Khanda, Choorana Kalpana. 7th ed. Ch. 6, Ver. 58-59. Varanasi: Chaukhambha Orientalia; 2000. p.52.
- Akhil Jain, Nidhi Garg, Therapeutic and medicinal uses of Shatapushpa: A Review, World Journal Of Pharmacy And Pharmaceutical Sciences. SJIF Impact Factor 6.647 Volume 6, Issue 2, 336-342. Review Article ISSN 2278 – 4357
- Shashikant M Prajapati, Bhupesh R Patel, Phyto-Pharmacological Perspective of Yashtimadhu (Glycyrrhiza Glabra LINN.) – A Review, International Journal of Pharmaceutical & Biological Archives 2013; 4(5): 833 - 841
- S.M. Prasad Raj, Mahesh Kumar E.S. Effectiveness of Musta-Takra Basti in the Management of Ulcerative Colitis (Pittaja Grahani) – A Case Report. AYUSHDHARA, 2020;7(5):2940-2944.
- Ved Bhushan Sharma, Parul Sharma. Ayurvedic management of ulcerative colitis – A case study. Ayurpharm Int J Ayur Alli Sci. 2015;4(4):105-108
- Peshala K.K.V.S et al. Ayurveda approach for management of ulcerative colitis: A review. Int. J. Res. Ayurveda Pharm. 2019;10(1):21-26 <http://dx.doi.org/10.7897/2277-4343.10016>
- Kalapi et al.: P02.87. Ayurvedic management of Ulcerative Colitis: a non-randomized, observational clinical study. BMC Complementary and Alternative Medicine 2012 12(Suppl 1):P143
- Madhuri D. Daberao, Brijesh Mishra "Role of Piccha Basti in the management of celiac disease w. s. r. to Grahani: a review." Ayurline: International Journal of Research In Indian Medicine 2020;4(5): 01-09
- Joshi A, Chaudhary S, Thakar AB. Role of Basti and Sirodhara in the management of Grahani (Irritable Bowel Syndrome) - A Case Report. Int. J. AYUSH CaRe. 2020; 4(3):90-96

How to cite this article: M.R. Poornima, Sarika A. K, Gadilinga, Srinivas Masalekar, Ananta S Desai. A Case Report on management of Grahani with special reference to Ulcerative Colitis. J Ayurveda Integr Med Sci 2021;6:238-242.

Source of Support: Nil, **Conflict of Interest:** None declared.
