



ISSN 2456-3110

Vol 6 · Issue 6

Nov-Dec 2021

Journal of
**Ayurveda and Integrated
Medical Sciences**

www.jaims.in

JAIMS

An International Journal for Researches in Ayurveda and Allied Sciences



Maharshi Charaka
Ayurveda

Indexed

Successful management of Cervical Erosion through *Kshara Karma* - A Case Report

Nanda KO¹, Usha DT², Sankanagoud Patil³

¹Assistant Professor, Department of Prasuti Tantra & Stree Roga, JSS Ayurveda Medical College & Hospital, Mysuru, Karnataka, India.

²Reader, Department of Prasuti Tantra & Stree Roga, JSS Ayurveda Medical College & Hospital, Mysuru, Karnataka, India.

³Reader, Department of Swasthavritta, JSS Ayurveda Medical College & Hospital, Mysuru, Karnataka, India.

ABSTRACT

Cervical erosion is a common gynecological condition seen in OPD. About 85% of woman suffers from cervical erosion which is a benign condition of female genital tract during Reproductive life time. Though it's not a fatal one yet the long-term association with the disease and the number of symptoms both related to genito-urinary system as well as psychological imbalance in patient needs attention. The complications encountered by diathermy, cauterization, laser therapy, etc. like local operations on the cervix causes menstrual disturbances, reactionary hemorrhages, cervical stenosis, sepsis, perforation of cervix, troublesome vaginal discharge and effect on subsequent pregnancy and child birth. Cervical erosion can be considered as *Gabhashayagrivagata Vrana*, as it shows the features of *Vrana*. By considering the *Lakshana* and *Chikitsa* of *Karnini Yonivyapath*, *Kshara Karma* having better result in treating Cervical Erosion.

Key words: *Karnini Yonivyapath*, *Kshara Karma*, *Cervical Erosion*, *Garbhashayagrivagata Vrana*

INTRODUCTION

Cervical Erosion is a condition in which the cells from the "inside" of the cervical canal, known as glandular cells (or columnar epithelium), are present on the "outside" of the vaginal portion of the cervix. The cells on the "outside" of the cervix are typically squamous epithelial cells. It is one of the most common gynecological conditions seen in OPD. About 85% of

women suffer from cervical erosion which is a benign condition of female genital tract during Reproductive life time. Though it's not a fatal one yet the long-term association with the disease and the number of symptoms both related to genito-urinary system as well as psychological imbalance in patient needs attention. The complications encountered by diathermy, cauterization, laser therapy, etc., like local operations on the cervix causes menstrual disturbances, reactionary hemorrhages, cervical stenosis, sepsis, perforation of cervix, troublesome vaginal discharge and effect on subsequent pregnancy and child birth.^[1]

As we go through the etimology and features of cervical erosion, it can be corelated to *Karnini Yoni Vyapata*. And the main treatment for *Karnini Yoni Vyapata* is mentioned as *Sthanik Shodhana*. Going through the *Kshara Gunas*^[2] i.e. *Ushna Virya*, *Tikshna Guna*, *Vrana Shotha Pachaka*, *Sroto Shodhaka*, *Klinnata Shoshaka*, *Raktatirava Stambhaka*, *Ropaka*, *Kathin Unnata Mamsadi Lekhaka*. Comparing the line

Address for correspondence:

Dr. Nanda KO

Assistant Professor, Department of Prasuti Tantra & Stree Roga, JSS Ayurveda Medical College & Hospital, Mysuru, Karnataka, India.

E-mail: nandako89@gmail.com

Submission Date: 02/11/2021 Accepted Date: 07/12/2021

Access this article online

Quick Response Code



Website: www.jaims.in

Published by Maharshi Charaka Ayurveda Organization, Vijayapur, Karnataka (Regd) under the license CC-by-NC-SA

of treatment and the *Kshara Gunas*, it is observed that *Kshara* can be used in the treatment of cervical erosion. And also the side effects of cauterisation, specially cervical stenosis and discharge may be overcome by the use of *Kshara*.

Keeping in view, the above-mentioned symptomatology and problems in treating them, so *Kshara Karma* acts as an alternative, safe and cost-effective management in treating *Karnini Yonivyapath*.

CASE REPORT

A patient aged 44 years; c/o thick white discharge PV associated with severe itching since 1 year. She had shown to local clinic and treated for the same, but after completion of medication often starts with the same complaints and it is interfering and disturbing her daily routine and also there is increase in white discharge PV along with itching since 3 months.

On Examination

General Examination

Moderately Built and Nourished, Height - 164cms, Weight - 64 kgs

PR: 82/min, BP: 120/80 mmHg; Pallor ++

P/A – Soft, NAD

Local Examination

External Genitalia – Vulva – Scratch wound present

P/S – Cervix – Erosion +++++, White Discharge +++, Congestion ++, Inflamed +

Vagina – White Discharge ++

P/V- Anteverted & Anteflexed Uterus/ Mild Bulky/ Fornices tenderness ++

OBG History

Married Life - 22 years; Non consanguineous marriage

Menarche: 14th year; MC – Regular; 4-5 days /30 days; LMP - 05-04-2020, Moderate Flow

P2L2 – P1 L1 Male 18 years; P2 L2 Female 16 years – both Full term Normal Delivery followed by LTO 18 years back

Coital History: Weekly twice

Not a K/C/O DM/HTN/Thyroid Dysfunction; No similar complaints in family members

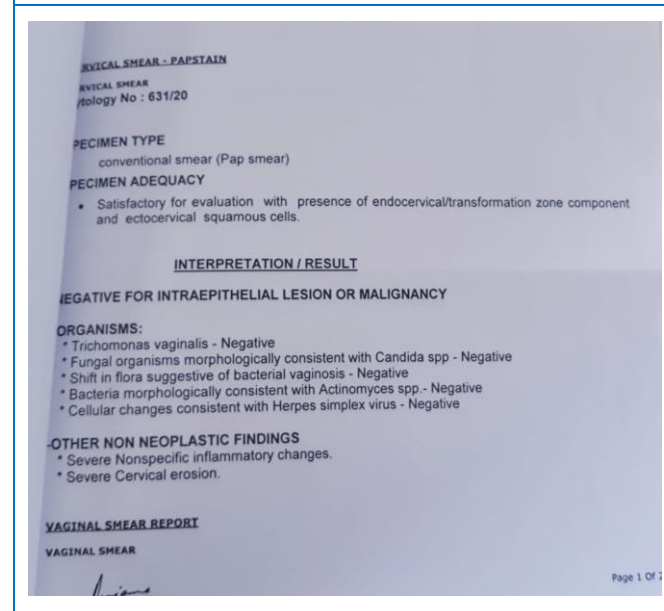
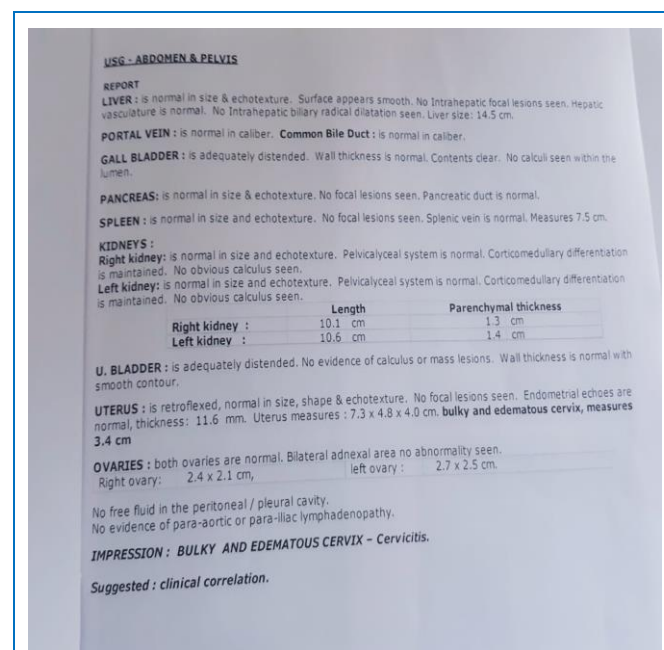
Investigation

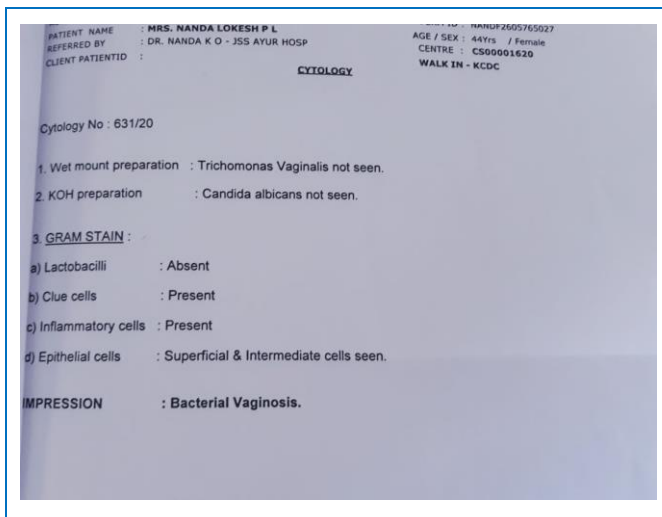
Hb% - 10.5 gm%; RBS -97 mg/dl, Urine Routine - Normal

Vaginal Smear s/o Bacterial Vaginosis

Pap smear s/o Severe Nonspecific Inflammatory Changes, Severe Cervical Erosion

USG Abdomen & Pelvis s/o Bulky and Edematous Cervix – Cervicitis





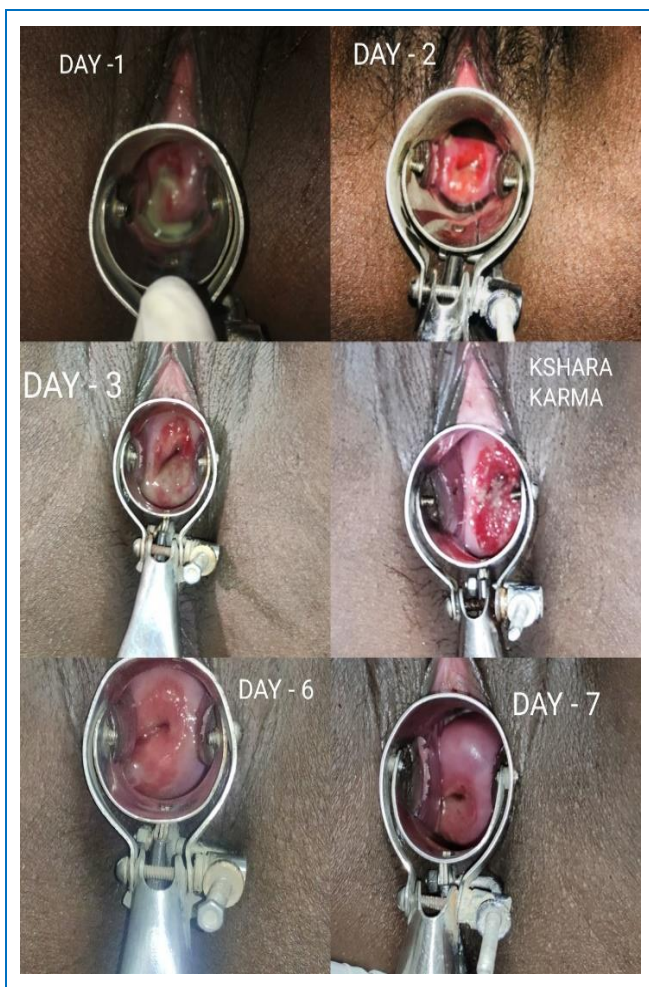Management

Yoniprakshalana with *Panchavalkala Kwatha* - 7 days

Yonikshara Lepa with *Apamarga Kshara* - 1 day

Yonipichu with *Yashtimadhu Taila* - 7 days

RESULT



Mode of Action

Yoniprakshalana with *Panchavalkala Kwatha* – the drug is *Sheetaveerya*, *Kashaya Rasa Pradhana* helps for *Vranaropana* and *Shodana* and also helps to reduce the *Yonivrava*. *Panchavalkala Kwatha* acts as antibacterial and anti-inflammatory property which helps

Yoniksharalepa with *Apamarga Kshara* – which helps for *Dahana*, *Pacana*, *Darana*, *Vilayana*, *Shodana*, *Ropana* and *Shoshana* of *Karnika* which in turn helps to relieve the symptoms. *Ksharana* and *Kshalana Karmas* of *Kshara* slowly transmitted into interior strata thus eradicating dysplastic cells and at the same time causing healthy re-epithelization.

Yonipichu with *Yashtimadhutaila* – the drug helps for *Vranaropana* as well as *Yonivishodhana*.

DISCUSSION

Karnini Yonivyapath, the word *Karnini* is derived from *Karnika* which means having ears, finger like projections, barbed wire, the tip of an elephant’s trunk and furnished with knots. The condition is due to the development of *Karnika* on *Garbhashayamukha*. Development of *Karnika* is the characteristic feature of *Karniniyonivyapath*. *Karniniyonivyapath* can also be understood as *Garbhashayagreevagata Vrana* and similar management of *Vrana* can also be adopted.

Cervical Erosion (also called as Cervical Ectopy) is a condition in which the squamous covering of the vaginal aspect of cervix is replaced by columnar epithelium which is continuous with that lining the endocervix. It is not an ulcer. It is described as “ The interplay between the two epithelia.” An ectopy has a reddened appearance with a clearly defined edge, the colour being explained by the underlying tissue showing through a thin epithelium. The columnar epithelium may be arranged in a regular pattern but is sometimes proliferated and heaped up to form villous projections – a papillary ectopy. This may be congenital or acquired. The symptoms may include-persistent white discharge, backache, metrorrhagia, frequency of micturition, chronic ill health, pruritis, infertility, psychological upsets or there may be no symptom at all. [3,4,5]

Kapha Vataghna, *Sroto Shodhana* and *Kandu- Kleda-Shopha Hara* line of treatment has been described in texts. Mainly indicates *Shodhana* by the topical application of medicine is the principle line of treatment. According to modern view, the main line of treatment for cervical erosion is Cauterisation, Cryosurgery. By adopting the *Yoni Prakshalana*, *Pichu* and *Kshara Karma* by selecting the drugs which are having *Kapha Vataghna*, *Sroto Shodhana* and *Kandu-Kleda-Shopha Hara* property the condition can be treated

CONCLUSION

In Present Case Report, In *Karnini Yonivyapath*, *Yoniprakshalan* followed by *Yonimukha Kshara Lepa* and *Yonipichu*, these *Sthanika Chikitsa's* having effective management in treating Cervical Erosion.

REFERENCES

1. Dutta DC, Textbook of Gynaecology including contraception, 5th edition, pg no. 257
2. Kaviraja Ambikadatta Shastri, Susruta Samhita, reprint edition 2009, Chaukhamba Sanskrit Sansthan, Sutra Sthana 11th chapter /5, pg no. 45
3. Dutta DC, Textbook of Gynaecology including contraception, 5th edition, pg no. 257
4. Streeroga Vigyana by V N K Usha. pg no 289-292
5. Jeffcoate's Principles of Gynaecology, 7th international edition, edited by Pratap Kumar, Narendra Malhotra; Pg.no. 410-411

How to cite this article: Nanda KO, Usha DT, Sankanagoud Patil. Successful management of Cervical Erosion through Kshara Karma - A Case Report. J Ayurveda Integr Med Sci 2021;6:258-261.

Source of Support: Nil, **Conflict of Interest:** None declared.
