



ISSN 2456-3110

Vol 7 · Issue 1

Jan-Feb 2022

Journal of
**Ayurveda and Integrated
Medical Sciences**

www.jaims.in

JAIMS

An International Journal for Researches in Ayurveda and Allied Sciences



Maharshi Charaka
Ayurveda

Indexed

Management of *Parikartika* w.s.r. to Acute Fissur-In-Ano with *Guduchi Taila Pichu* - A Case Study

Renuka T¹, Shreedhar Rao²

¹Post Graduate Scholar, Dept of Shalya Tantra, Govt. Ayurvedic Medical College & Hospital, Bengaluru, Karnataka, India.

²Professor, Dept of Shalya Tantra, Govt. Ayurvedic Medical College & Hospital, Bengaluru, Karnataka, India.

ABSTRACT

Fissure in ano is very common yet troublesome condition. Due to life style, intake of low fibre diet, junk food and constipation. Recurrence nature of this disease makes the treatment challenging. The symptoms can be correlated to *Parikarthika* according to Ayurveda. Many treatment modalities have been mentioned and practiced in management of *Parikarthika* such as *Deepana*, *Pachana*, *Vaatanulomana*, *Avagaaha*, *Basti Karma* and local application of *Madhura*, *Sheetha*, *Snigdha Dravyas*, *Taila Poorana*, *Lepa* and *Pichu-Dharana*. *Pichudhaarana* works on the basis of cellular absorption and is easier method for adoption. **Conclusion:** A case having features of *Parikarthika* was selected from OPD, SJIIM Hospital for case study and *Guduchi Taila Pichudharana* was done for 7 days. Assessment was done based on features like pain, burning sensation and sphincter tone. Significant improvement was observed after treatment.

Key words: *Parikartika*, *Guduchi Taila*, *Fissure-In-Ano*.

INTRODUCTION

Parikarthika is a complication of *Basti Karma* and *Virechana Vyapath* as mentioned in *Brihatrayees*. *Parikarthika* is characterized by *Kartanavat* and *Chedanavat Shoola* in *Guda*.^[1]

Major etiological factors of *Parikarthika* are summarized as: improper administration of *Virechana* and *Basti Karmas* and it is a complication of *Atisara*, *Grahani* and *Arsha Roga*. *Acharya Kashyapa* classifies the condition into three types viz. *Vataja*, *Pittaja* and *Kaphaja*. *Acharya Sushruta* described the symptoms of the disease as cutting or burning pain in *Guda*, *Basti*,

Shiras and *Naabhi*^[2] and *Acharya Charaka* describes the features as cutting pain with burning sensation in *Guda*, *Naabhi*, *Medhra*, *Basti Shira* and *Aruchi*. *Acharya Charaka* also mentioned slimy blood discharge as a *Lakshana* of *Parikarthika* in *Siddhi Sthana*.

Parikarthika can be correlated with Fissure-in-ano of the contemporary science. It is longitudinal split in anoderm of the distal anal canal which extends from the anal verge proximally towards but not beyond the dentate line.^[3] Fissure in ano is characterized by excruciating pain during and after defecation, bleeding per anum along with spasm of anal sphincter. About 30-40% of population suffers from proctologic pathologies at least once in their lives. Anal fissures comprise of 10-15% of anorectal disorders.

The line of management in contemporary science includes analgesics, stool softeners, smoothing ointments and anal dilatation. Surgical intervention includes Lords dilatation, Posterior fissurectomy and Anal sphincterotomy. All these treatments have their own limitations and side effects.^[3]

Acharya Sushruta has mentioned *Anuvasana Basti*^[4] with *Ghritha Manda* or oil processed with *Yashtimadhu* as line of treatment in *Parikarthika*.

Address for correspondence:

Dr. Renuka T

Post Graduate Scholar, Dept of Shalya Tantra, Govt. Ayurvedic Medical College & Hospital, Bengaluru, Karnataka, India.

E-mail: dr.renugopi43@gmail.com

Submission Date: 15/01/2022 Accepted Date: 18/02/2022

Access this article online

Quick Response Code



Website: www.jaims.in

Published by Maharshi Charaka
Ayurveda Organization, Vijayapur,
Karnataka (Regd) under the license
CC-by-NC-SA

The condition demands innovative techniques for its management. Many techniques have been tried, each by no means better than other. There is always a need for the cost effective and patient friendly method of management for *Parikarthika*.

Pichu^[5] is safe, ideal, convenient and cost effective. *Pichu* is explained in *Charaka Siddhi Sthana* 5th chapter. *Pichu* is a thick swab or cotton pad which is soaked in medicated ghee or oil. And it can be placed in the desired position or according to site of treatment. As it remains in-situ for more duration better absorption and action of the drug can be achieved. *Guduchi Taila*^[6] is *Tridosha Shamaka* having properties like *Vranahara*, *Kushtagna*, *Vaata-Raktahara* and *Kandugna*. Hence, *Guduchi Taila Pichu* is used here in the study for the treatment of *Parikarthika*.

CASE REPORT

A 47 yrs old female, house wife presented with complaints of severe pain in the anal region during and after defecation associated with burning sensation, constipation, stools streaked with blood since a week at Shalya Tantra OPD, SJIIM Hospital, GAMC, Bangalore, approached SJIIM Hospital for better management.

The patient had history of constipation and is not a known case of Diabetes mellitus, Hypertension or underwent any surgery. Patient consent was taken.

On physical examination pulse - 86/min, Blood pressure - 120/ 80 mmHg. All the laboratory investigations done were within normal limit.

Systemic examination was done and clinically no abnormalities were detected.

Local Examination

Inspection: Active bleeding was seen at the anal verge. On separation of anal verge, a longitudinal tear extending from the anal verge was seen at 1 o' clock position 1cm inside the anus.

Palpation: Tenderness present over the fissure area

Nidana

Ahara - *Ruksha Aahaara*, *Katu Pradhaana Aahaara Sevana*

Vihara - Prolong standing

Samprapti

The *Nidanas* (Aetiological factors) results in *Agnimandya* and there by leads to *Vata Pradhana Pitta Dosh Dushti*. Then localisation of *Dushita Doshas* occurs particularly in *Guda Pradesha*, producing *Twak Mamsa Dushti* and results in *Rukshata* of *Twacha* which later attains tendency to crack. Thus, cracked skin in the perianal region is *Parikartika*.

Diagnosis: *Parikartika* (Acute Fissure in Ano)

MATERIALS AND METHODS

Guduchi Taila preparation

Moorchita Tila Taila cooked with *Guduchi Kashaya* and *Kalka* with equal quantity of milk on mild fire till *Paaka Lakshana* was observed.

Treatment was planned as:

Sthanika Chikitsa and *Pathya*

Sthanika Chikitsa : *Guduchi Taila Pichhu* for 3 hours and duration of 7 days

Pathya

Sukoshna Jala Paana (*Deepana*, *Paachana*, *Vaataanulomana*) Rice, wheat, Buttermilk, milk, Bottle guard (*Patola*), elephant foot yam (*Soorana*), green leafy vegetables and rich fibre diet.

Assessment Criteria

Burning sensation at anal verge

- Severe - 3
- Moderate - 2
- Mild - 1
- Absent - 0

Pain - Visual analogue scale

- 7-10 : severe
- 4-6 : moderate
- 1-3 : mild
- 0 : absent

Bleeding per anum

- Grade 0 : Absent
- Grade 1 : Present

Sphincter tone

- Grade 1 : spasm present
- Grade 0 : Normal sphincter tone

Treatment	Day	Observation			
		Burning sensation	Pain	Bleeding per anum	Sphincter tone
Guduchi Taila Pichu	1st	3	Severe	1	1
	2nd	3	Moderate	1	1
	3rd	2	Mild	1	0
	4th	1	Mild	1	0
	5th	0	0	1	0
	6th	0	0	0	0
	7th	0	0	0	0

OBSERVATIONS AND RESULTS

Clinical examination of the patient revealed regression of symptoms with treatment day by day. On third day there was mild pain and scanty bleeding streaked to stools. On 4th day minimal burning sensation was seen and sphincter tone was normal and on last day of treatment patient had no symptoms.

DISCUSSION

Patient got relieved from the symptoms of fissure-in-ano with Guduchi Taila Pichu.

Probable mode of action

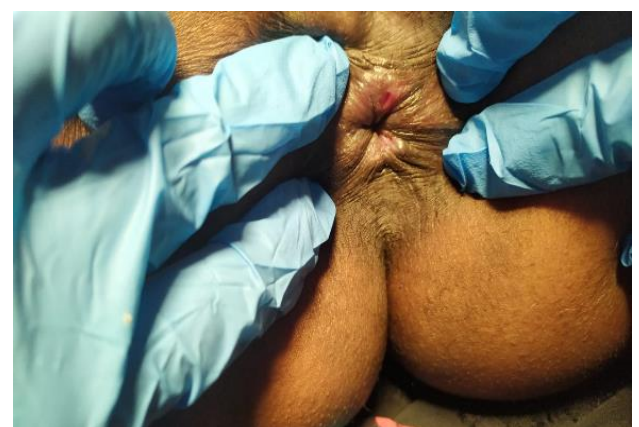
Properties	Guduchi	Taila
Rasa	Tikta, Kashaya	Katu
Guna	Guru, Snigdha	Guru

Veerya	Ushna	Ushna
Vipaaka	Madhura	Madhura
Doshagnata	Tridoshashaamaka	Vaataghna

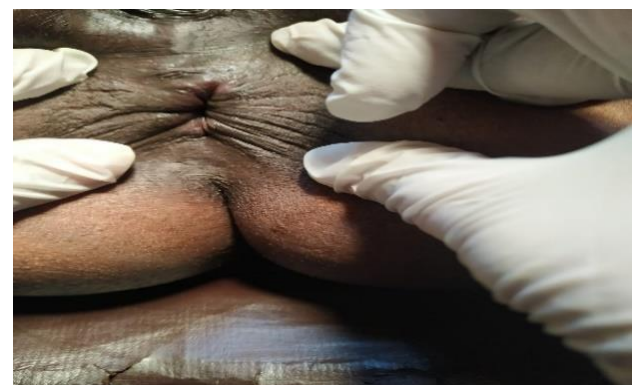Guduchi Taila mentioned by Chakradatta in Vaatarakta does Shamana of Vaata and Rakta and is indicated in Kushta, Twak Dosh, Vrana, Visarpa, Kandu and Dadru.

Local action of Pichu is based on cellular absorption of medicines, by which Vaata is regulated and Vedana and Rookshata is reduced.

Thus, Guduchi Taila Pichu helps in healing of acute fissure with symptomatic relief.



Before treatment



After treatment

CONCLUSION

In this single case study, Guduchi Taila Pichu along with proper Pathya has showed good results. Relief from

Acute Fissure-in-ano was seen. And on examination Fissure was also healed completely.

REFERENCES

1. Kashinath Shastri, Gorakanath Chaturvedi Charaka Samhita 23rd edition, Uttarardha, Siddisthana Ch.No.06 SI No. 61-62, Chowkamba Varanasi pp.1027
2. Kaviraja Ambika Datta Shashtri. Sushruta Samhita. 11th edition, Chikitsa sthana, Ch. No.34, SI.No16 Chowkamba Varanasi pp.151
3. Baileys and love short practice of surgery 24th ed.pp.1253-1254
4. Kaviraja Ambika Datta Shashtri. Sushruta Samhita. 11th edition, Chikitsa sthana, Ch. No.34, SI.No16 Chowkamba Varanasi pp.151

5. Kashinath Shastri, Gorakanath Chaturvedi. Charaka Samhita. 23rd edition, Uttarardha, Siddisthana Ch.No.06 SI No. 61-62, Chowkamba Varanasi. Pg.no. 620
6. Chakradatta, Priyavat Sharma, Chaukamba Publishers, Chikitsastaana. Vatarakta Chikitsa. Ch No.23. SI no.21,22.

How to cite this article: Renuka T, Shreedhar Rao. Management of Parikartika w.s.r. to Acute Fissur-In-Ano with Guduchi Taila Pichu - A Case Study. J Ayurveda Integr Med Sci 2022;1:339-342.

Source of Support: Nil, **Conflict of Interest:** None declared.
