



ISSN 2456-3110

Vol 7 · Issue 1

Jan-Feb 2022

Journal of
**Ayurveda and Integrated
Medical Sciences**

www.jaims.in

JAIMS

An International Journal for Researches in Ayurveda and Allied Sciences



Maharshi Charaka
Ayurveda

Indexed

Eranda Kshara an effective alternative for Apamarga Ksharasutra - A Case Study

Amala J. Tharesa¹, Srinivas Masalekar²

¹Post Graduate Scholar, Dept. of Shalya Tantra, Govt. Ayurveda Medical College and Hospital, Bengaluru, Karnataka, India.

²Associate Professor, Dept of Shalya Tantra, Govt. Ayurveda Medical College and Hospital, Bengaluru, Karnataka, India.

ABSTRACT

Bhagandara which is correlated to Fistula in Ano, is considered as one of the *Ashta Maharoga*^[1] (8 major diseases) by *Acharya Susruta*, that is diseases which are difficult to cure. In modern science treatment of *Bhagandara* includes fistulotomy, fistulectomy, LIFT, VAAFT etc., but till date none of these methods have proven to give complete cure in fistula in ano. *Kshara Sutra* therapy is a parasurgical procedure which is used in fistula in ano and is mentioned by *Acharya Susruta* in the context of *Nadi Vrana Chikitsa Adhyaya*.^[2] The *Kshara Sutra* therapy is found to be effective in treating *Bhagandara* as it is minimal invasive procedure with least recurrence nature. Among 28 *Kshara Gana* mentioned in classics all drugs have been researched to assess the effectiveness by using it as *Kshara Sootra* and *Apamarga Kshara Sutra* has been standardized. Though *Apamarga* is proven to be effective *Ksharasutra*, as it is a seasonal plant its collection is found to be very difficult and makes it costly. *Eranda* is a drug, which is easily available throughout the year, grown abundantly everywhere in India, cost effective, from which *Ksharasutra* can be made easily. The present study was undertaken to assess the role of *Eranda Ksharasutra* in treatment of *Bhagandara* in a patient who approached OPD of SJIIM Hospital, Bengaluru.

Key words: *Bhagandara*, *Fistula in ano*, *Eranda Ksharasutra*

INTRODUCTION

The word *Bhagandara* is derived from two words *Bhaga* and *Darana* that is tear in ano rectal region. The formation of *Pidaka* in *Guda pradesha* leads to development of *Bhagandara*.^[3] It is characterized by opening around *Guda Pradesha* with painful discharge. According to modern science, the word fistula is derived from Latin word which means reed, pipe or flute. It is an abnormal connection between anal canal

and rectum which has an external opening in perianal skin and internal opening in anal canal.^[4] It usually results from an anorectal abscess which burst spontaneously or opened inadequately.

Kshara Karma is considered as one of the most important Parasurgical procedure as it can produce excision, incision, scrapping and can pacify all three *Doshas*. In present days *Ksharasutra* therapy is the chief treatment modality adopted for *Bhagandara* in Ayurvedic science. Hence it demands the usage of a drug which is easily available for making *Ksharasutra*. *Eranda* is plant which is mentioned to be effective in its *Kshariya* form in diseases like *Medo Roga*, *Ksudra Roga*. Also, it possesses properties like *Kapha-Vatahara* (pacifies *Vata* and *Kapha*), *Sirovirechana*, *Dipana - Pacana* (carminative), *Medohara* (disintegrates fat). Hence in the present study an effort is made to access *Eranda* in its *Kshara* form and to evaluate its effectiveness as *Ksharasutra* in management of *Bhagandara*.

Address for correspondence:

Dr. Amala J. Tharesa

Post Graduate Scholar, Dept. of Shalya Tantra, Govt. Ayurveda Medical College and Hospital, Bengaluru, Karnataka, India.

E-mail: ammujoy92@gmail.com

Submission Date: 09/01/2022 Accepted Date: 14/02/2022

Access this article online

Quick Response Code



Website: www.jaims.in

Published by Maharshi Charaka Ayurveda Organization, Vijayapur, Karnataka (Regd) under the license CC-by-NC-SA

In this case, patient presented with complaints of profuse pus discharge, pain and swelling. After routine blood investigations and careful examination with probe the case was diagnosed as fistula in ano associated with external hemorrhoids which is confirmed by TRUS report and fistula was of inter-sphincteric type.

In this case study, Fistula in ano was treated with *Eranda Kshara Sutra*. Fistula was cured and there were no complications during the treatment and there was no recurrence.

CASE REPORT

Gender - Male

Age - 56 yrs.

Occupation - Engineer

Date of first visit - 27/07/2021

Date of recovery - 28/8/2021

Chief complaints and duration - Patient complaints of pain, swelling, pus discharge in the perianal region since 3 months.

H/O Present illness

56 yrs old male patient presents with complaints of painful swelling, mass and itching in the perineal region on 26/07/2020 at our OPD. On examination patient had external opening at 5 'o' clock position with tenderness. Provisional diagnosis was made as fistula in ano, which was confirmed by trans rectal ultrasonography on 31/07/2021. Features were suggestive of inter-sphincteric fistula in ano.

H/o past illness

h/o surgery for inguinal hernia - reports not available

General Examination

- GC - moderate
- CVS - S1 S2 Heard
- Pulse - 82/min, BP-120/70mmhg
- RS - B/L Air entry is clear
- Digestive system - Appetite - Normal, Bowel - regular, hard
- Uro genital system - NAD

Local Examination

Patient made to lie in lithotomy position and findings were noted.

Inspection: swelling 1 × 1 cm, watery discharge, no redness, no scar marks

Palpation: temperature slightly raised, tenderness present

Per rectal examination: dimpling was noted at 5 'o' clock position

Probing: approximately 3 cm track which had external and internal opening at 5 'o' clock position.

TRUS: there is evidence of inter-sphincteric fistula in ano. The external opening at 5 'o' clock position. The course of sinus is straight. The fistulae measure 2.9 × 0.5 cm (length × diameter approximately). The internal opening in the mucosal plane is at 2.2 cm from the external anal orifice. No secondary tracts. No evidence of curved tract.

Preparation of Kshara Sutra

Snuhi Ksheera = 11 coatings

Snuhi Ksheera + Eranda Kshara = 7 coatings

Snuhi Ksheera + Haridra Churna = 3 coatings

The surgical linen thread was autoclaved and mounted on the hangers. The thread was smeared with *Snuhi Ksheera* using a gauze piece dipped in *Snuhi Ksheera*. Then this wet threaded hanger was placed inside *Ksharasutra* cabinet after that it was dried for a day. Next day, dried thread was again smeared with latex of *Snuhi*. The process was repeated for 11 days. On 12th day again thread was smeared with *Snuhi Ksheera* then in the wet condition the thread was spread with *Eranda Kshara*. The thread was dried and the same procedure repeated for 7 times for 7 days. On 19th day the dry thread was smeared with latex of *Snuhi*, and then in wet state immediately with *Haridra Churna*. The procedure was repeated for 3 days continuously. In this way the thread has total 11 coatings of *Snuhi Ksheera*, 7 coatings of *Snuhi Ksheera + Eranda Kshara* and 3 coatings *Snuhi Ksheera + Haridra Choorna*. The

prepared *Sutras* were then stored in *Ksharasutra* cabinet.

Pre-operative

Patient is advised to do routine investigations like CBC, ESR, CT BT, RBS, HIV, HbSAg, urine routine and all reports were found to be within normal limit. Then patient consent was taken and posted for the *Khsara Sutra* application.

Kshara Sutra prepared with *Eranda* as per standard protocol was kept ready. Part preparation was done. Injection T.T. 0.5 ml and plain 2% xylocaine test dose were given.

Operative Procedure

Patient was made to lie in lithotomy position. Under all aseptic precautions, painting and draping of part done. Per rectal examination was done. A suitable malleable probe lubricated with lignocaine jelly was forwarded along the path of least resistance and guided by the finger in the anal canal to reach into its lumen. Then the tip was directed to come out of the anal orifice through the internal opening in the anal canal. A suitable length of linen thread was taken which was sterilized and threaded in the eye of the probe. Thereafter the probe was pulled out through the anal orifice, to leave the thread behind in the fistulous tract. The two ends of plain thread were then tied together with a moderate tightness outside the anal canal. This procedure is called primary threading. On the 3rd day primary thread was replaced by *Eranda Ksharasutra* by adopting rail – road method.

Post-operative

Sitz bath with warm *Panchavalkala Kwatha* twice daily was advised.

Triphal Choorna 5-10 gms with warm water at bed time was prescribed.

Follow up

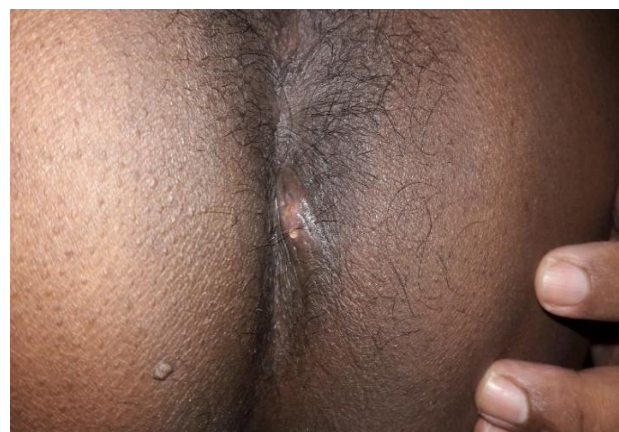
Ksharasutra change was done at weekly interval. The same procedure was followed for successive changes.

OBSERVATION

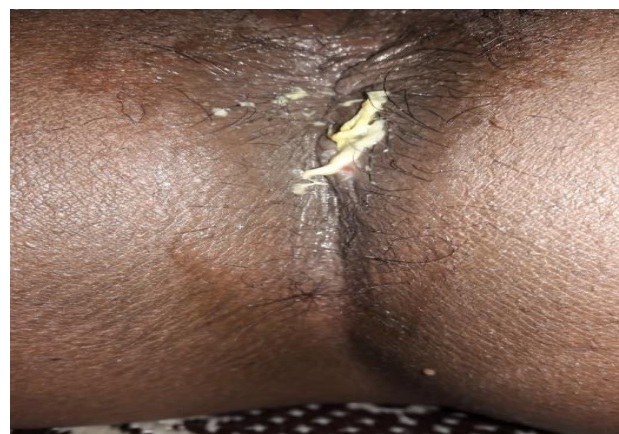The initial length of track was 3cm, which got cut in 3 weeks and got healed in 1 week. Pain reduced after

every successive sitting and there was no burning sensation which was common with *Apamarga Ksharasutra*. After complete cutting of tract patient came for follow up for 3 months. No signs and symptoms of recurrence were observed.

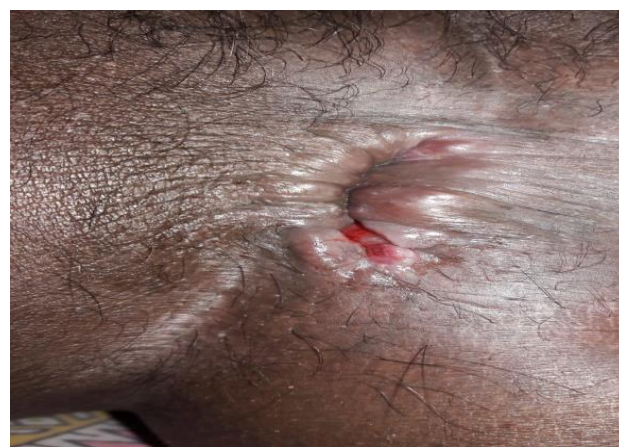Before treatment

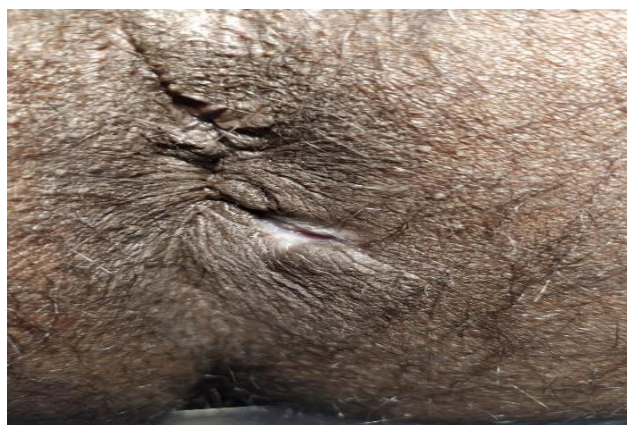
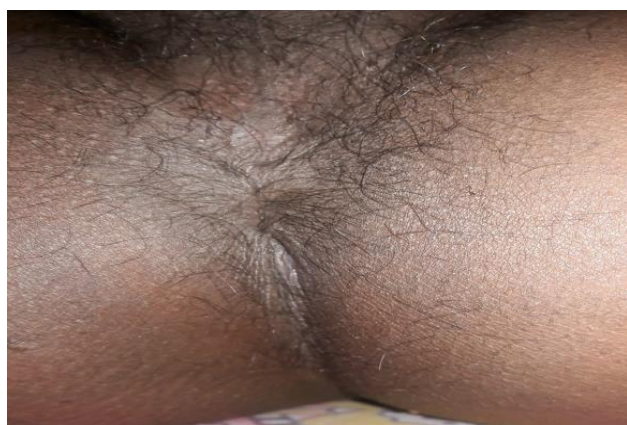
On Ksharasutra application



Track Has Been Cut



Healed track**After treatment****CONCLUSION**

Ksharasutra has now become the foremost treatment choice for ano rectal disorders especially Fistula in ano. The main advantage of *Ksharasutra* is, it can save the sphincters without leading to incontinence. *Kshara Sutra* therapy is the minimal invasive Parasurgical procedure which can be performed with minimal equipment's and instruments. Complications and recurrence followed by *Kshara Sutra* therapy is very

minimal. Along with cutting of the tract *Ksharasutra* also heals the wound by promoting the drainage of tract and formation of healthy granulation tissue. In the present study *Eranda Kshara Sutra* have found be as effective as *Apamarga Ksharasutra* in cutting rate, healing and pain management. So *Eranda Kshara Sutra* can be used as better alternative for *Apamarga Kshara Sutra* in Ano rectal disorders especially in Fistula in ano.

REFERENCES

1. Acharya Sushruta: sushruta samhitha with Nibandhasangraha commentary of Sri Dalhanacharya, Edited by Vaidya Yadavji Trikamji Acharya, Chaukhamba Surbharati Prakashanam, Varanasi, reprint 2008, Sutra Sthana, Chap.33, Verse 4, Pp 824, Pg-144
2. Acharya sushruta: sushruta samhitha with Nibandhasangraha commentary of Sri Dalhanacharya, Edited by Vaidya Yadavji Trikamji Acharya, Chaukhamba Surbharati Prakashanam, Varanasi, reprint 2008, Chikitsa Sthana, Chap.8, Verse 12, Pp 824, Pg-439
3. Susrutha Samhita – English translation of text and Dalhana' s commentary along with critical notes by P.V.Sharma. Chaukhamba Vishwabharati.2005 vol 2 Nidanasthana 4/3,5
4. Shenoy K Rajgopal, Shenoy Anita, Manipal Manual of Surgery, 4th edition 2014, New Delhi, CBS publishers, p- 799

How to cite this article: Amala J. Tharesa, Srinivas Masalekar. Eranda Kshara an effective alternative for Apamarga Ksharasutra - A Case Study. J Ayurveda Integr Med Sci 2022;1:371-374.

Source of Support: Nil, **Conflict of Interest:** None declared.
