



ISSN 2456-3110

Vol 2 · Issue 2

Mar-Apr 2017

Journal of
**Ayurveda and Integrated
Medical Sciences**

www.jaims.in

JAIMS



Charaka
Publications

Indexed

Understanding of Calveria *Marmas* w.s.r. *Sirogata Marmas* - An Modern Prospective

Bhosgikar Anup,¹ Kundu Debasis,² Waghmare Ashwinikumar,³ N. G. Mulimani.⁴

¹Assistant Professor, ²Post Graduate Scholar, ³Assistant Professor, ⁴Professor and HOD, Department of Shareer Rachana, N.K. Jabshetty Ayurvedic Medical College and P G Centre, Bidar, Karnataka, India.

ABSTRACT

The word *Marma* (vital area) was first time described in the Hindu scripture Atharvana Veda. During the Vedic period, the knowledge of the human body was important part of military science. The knowledge was applied in war, medicine and surgery. The science of *Marma* was developed by physicians and surgeons of Vedic period to prevent death and treat the people suffering from trauma and also to attach on enemy in war. However, there are some narration in Ayurvedic texts which indicates the therapeutic fact of marma such as, The effect of massage and medicines applied to foot sole are carried by special *Siras* to nourished the eyes, therefore one willing to get good eyesight and health should protect the sole. Urdhavajatrugata part is a very important part of the body and *Shiro* (head) is most important part as told by Acharya Charka and referred as Uttamanga because it contains all the five intellectual senses and seat of *Prana* (vital energy). *Sirogata Marmas* are either *Vaikalyakara* (causes deformity) or *Sadhyapranahara* (lead sudden death), so it is important to know the constituents and position of *Marma* to protect from injury with the help of modern anatomy expertise. In this article it has been tried to explore structure forming the vital point for better understanding about marma pathology and treatment in present scinerio.

Key words: *Sirogata Marma, Sadhayapranahara, Vaikalyakara.*

INTRODUCTION

A *Marma* is defined as “*Maryanteitimarmani*” means there is serious damage to health after injury to these vital places. *Marma* is also defined as an anatomical area where arteries, tendons, vein, bones and joints meet together as location of life. The anatomical areas where structures pulsate and where pain exists can be named as *Marma*.^[1] Acharya Sushruta has

classified these *Marmas* on the basis of their location in the body, dimension and the effect of injury (prognosis).

Etiopathogenesis ^[2]

There are four *Siras* which carry *Vata, Pitta, Kapha* and *Rakta* situated in *Marmas* and nourishes the whole body. If there is any damage to these *Siras* resulting into excessive loss of *Raktadhatu* (blood) consequently aggravation of *Vayu* takes place causes intens pain. Later on, it aggravates the *Pitta Dosha*. Due to increase of *Pitta Doshas* there are symptoms like thirst, dryness, lack of concentration, giddiness, sweating, latharginess and weakness felt in the body, which further leads into death.

Marmas are such a vital point where least infliction gives intense pain. If any disease affect the *Marma* point, then it became troublesome to treat provided giving the prompt and the best treatment by physician. Major injury at non- *Marma* point of body would not lead to death but if it affect

Address for correspondence:

Dr. Bhosgikar Anup

Assistant Professor, Department of Shareera Rachana.
N. K. Jabshetty Ayurvedic Medical College and Hospital and P G
Centre, Bidar (Karnataka) - 585403
E-mail: anoop.kulkarni9@gmail.com

Submission Date : 02/04/2017 Accepted Date: 28/04/2017

Access this article online

Quick Response Code



Website: www.jaims.in

DOI: 10.21760/jaims.v2i2.7729

Sadhyapranaharamarma will definitely lead to death but can be save if it is patially affected and prompt treatment given by the skilled physician with some deformity remained. Therefore while providing the treatment over *Marma* point *Kshara* (Alkali), *Visha* (Poison), *Agni* (Cautery) and *Siravedha* (venesection) should be prohibited.^[3]

Description of Siro-Gata Marma

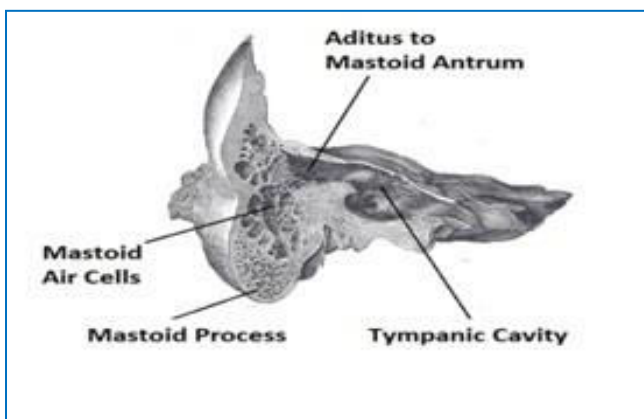
There are 37 *Urdhajatrugata*^[4] *Marma*, 6 found in Siro-gata region that is domain of *Ashtanga Ayurveda*. In this article main emphasis has given on these *Marmas* and detailed are as under:

1. Vidhura Marma

This is *Snayumarma* situated behind and below the ear (Retroauricular) on either side of the head measuring half angula (finger) in width. Injury at this point lead to deafness.

Underlying structures

This is located at point, postero-inferior to Auricle (Pinna), anterior to mastoid process and tendon of sternocleidomastoid muscle and above to angle of mandible. The related structures^[5] are facial nerve, stylo-mastoid artery, Ant. Tympanic artery, deep auricular artery, styloid process and vestibulocochlear nerve on very deep and remote level.^[7] The trauma at this site, damages the above said nerve, vessel, rupture of tympanum and dislocation of ear ossicle resulting into deafness.

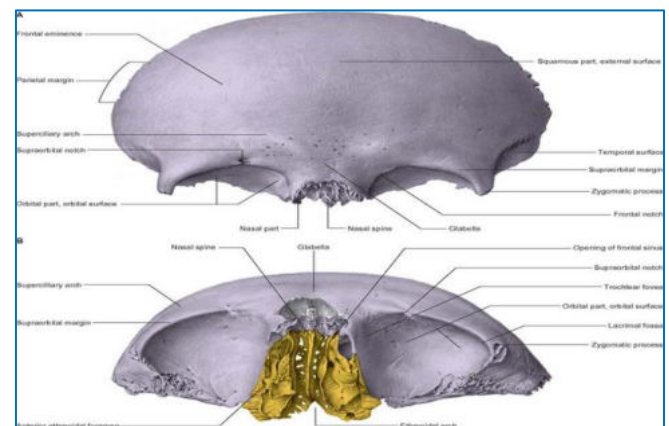


2. Sthapani Marma

It is *Siramarma*, located in between the eyebrow measuring half angula in width. The effect of injury is just like *Utkshepamarma*.

Underlying structures

It is correspond to area between two eye brows on saggital line. The structure related to this *Marma* is frontal sinuses and anterior cranial fossa separated by cribriform plate. The venous drainage of frontal sinuses occurs through supraorbital and supra ophthalmic veins into cavernous sinus. So injury at this site, through foreign body or fractured sinuses bone cause excessive bleeding or infection to anterior cranial fossa or cavernous sinus may cause death.^[7]



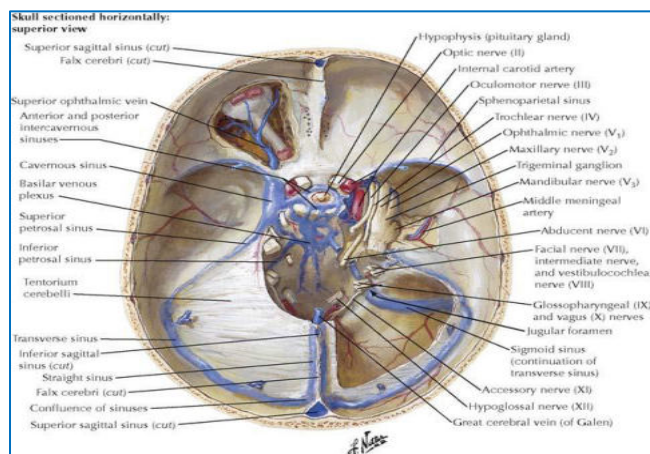
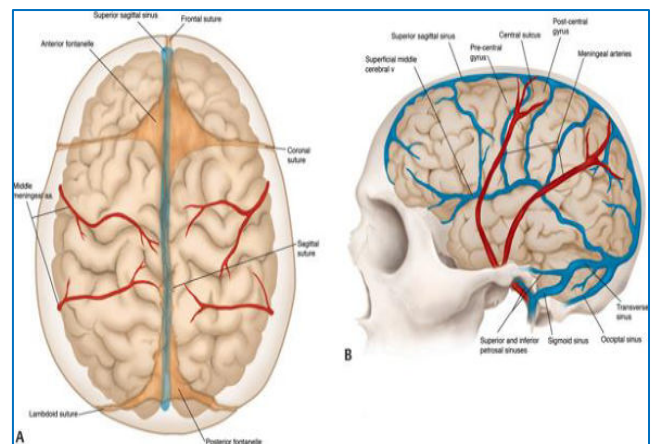
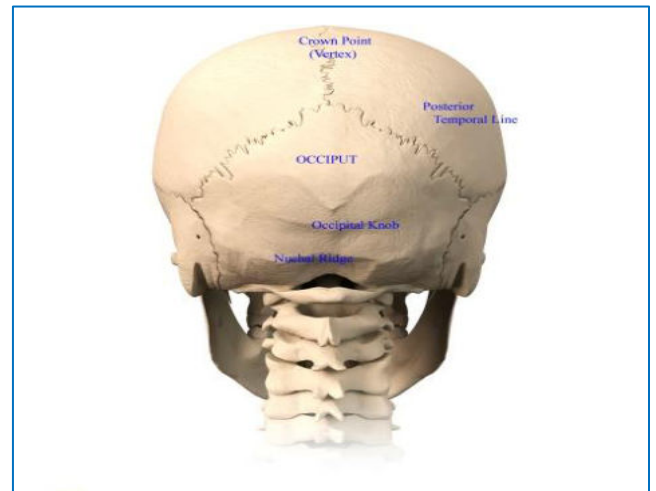
3. Shankha Marma

It is a *Asthimarma* situated above the end of eyebrow (*Bhruvopuchchhantapura*) and between ear and forehead (*Karnalalatomadhye*), Measuring to a length of half *Angula* in width. Injury to this *Marma* result into death.

Underlying structures

The site of *Shankhamarma* can be correspond to Pterion part of temporal fossa is the thin part of the skull where four bones frontal, parietal, greater wing of sphenoid and temporal adjoin each other. It lies 4 cm above the midpoint of the zygomatic arch and 2.5 cm behind the frontozygomatic suture. Deep to the pterion lays the middle meningeal vein, the anterior division of the middle meningeal artery, and the stem of the lateral sulcus of brain. Injury at this site or in road side accidents, the anterior division of middle meningeal artery may be ruptured, leading to clot formation between bone and dura mater or extradural haemorrhage. The clot compress the motor area of brain, leading to paralysis of opposite side.^[7]

Deeper and remote structure at this site is middle cranial fossa. Deep force at temporal fossa can cause middle cranial fossa fracture, the most commonly fractured fossa. The fracture line usually follows a definite course. It begins at the parietal tuber which usually the site of injury and passes through the parietal bone, the squamous temporal, and the petrous temporal bones usually involving the tegmen tympani, and frequently involving the internal acoustic meatus and the foramen ovale. Fracture of middle cranial fossa produces bleeding and discharge of CSF through ear, bleeding through nose or mouth if sphenoid bone is involved and damaged of seventh and eight cranial bone if fracture passes through internal acoustic meatus.



4. Adhipati Marma

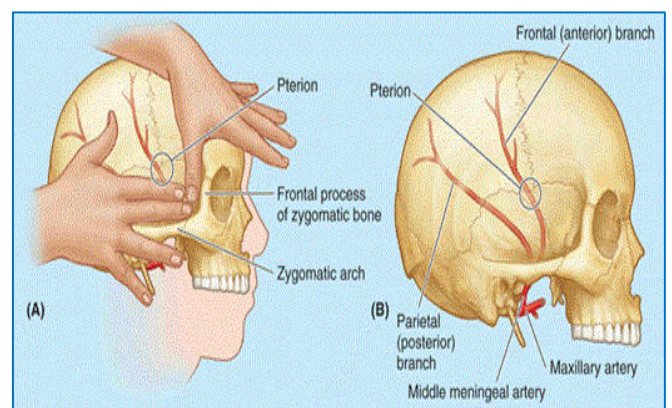
It is a *Sandhimarma* measuring half angula in width, located at the skull top as a cap. This is corresponding to *Brahma Randhara* through which the soul leaves the body can be considered. Inside the forehead and superiorly the conglumeration of *Sirasandhi* is located, which is representing outwardly by spiral of hairs on the top of the skull, where injury may leads to death.

Underlying structures

This is region of anterior fontanelle on the vertical groove of frontal bone. Underneath this, sagittal sinus of brain and sulcus between two hemispheres of cortex are found. This fall interiorly on the line passing through the mid brain, brain stem and spinal cord.^[7] Injury due to deep force may cause fracture of anterior cranial fossa and intracranial haemorrhage, ultimately can lead to death.

5. Shringataka Marma

It is located at the union of sira supplying to the nose, eyes, ears and tongue in *Talupradesh* of *Mukha* (base of skull) and measuring a length of four *Angula* in width. This is also found in context of *Nasyakarma*.



Underlying structures

This invariably corresponds to anterior fossa at base of skull i.e. cavernous sinus where venous drainage from eyes, nose, ears and tongue are reached. Here the course of cranial nerve 3rd, 4th and 6th are also

found. Injury at this place while performing surgery or foreign body or infection from these organ may cause cavernous sinus thrombosis or thrombophlebitis, is a fatal condition.^[9]

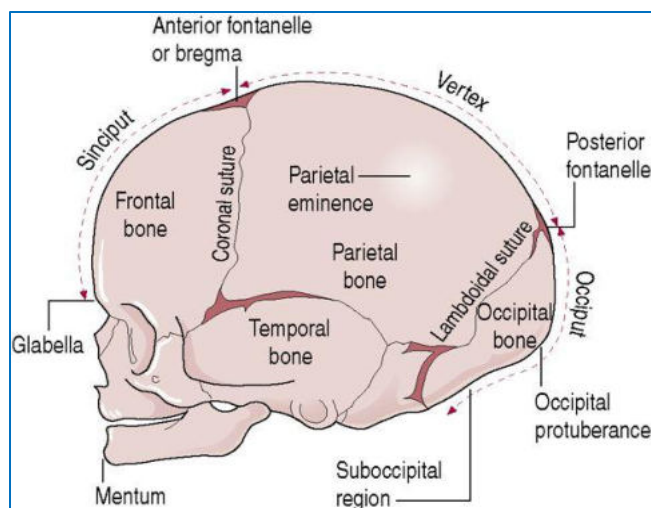
6. Simanta Marma

The word *Simanta* means the place of union or suturing. They are located on all the four side of head and five in number measuring four *Angula* in width.

Underlying structures

This is the cranial sutures of the skull not weakest point of skull, but injury at this point cause depression fracture of skull bone or diastasis of cranial suture with or without skull fracture and may be the only evidence of skull damage following head injury. Fracture of skull bone or diastasis of suture can cause concussion, contusion and contra-coup type damage to brain. Diastasis of skull sutures may give a rough guide as to the maximum site of skull trauma.

It may be particularly useful in drawing attention to injuries of the posterior cranial fossa. This may be particularly valuable when injury is of the contra-coup type. A blow to the head can cause bleeding in brain or sub dural haematoma. Haemorrhage or damage to the cortex or inside structure of the brain can disturb the normal pattern of neuron, also after injury there is inadvertently generate abnormal nerve connection consequently lead to giddiness, lack of consciousness, confusion and seizures etc. and in case severe haemorrhage and damage of brain can cause death.^[9]

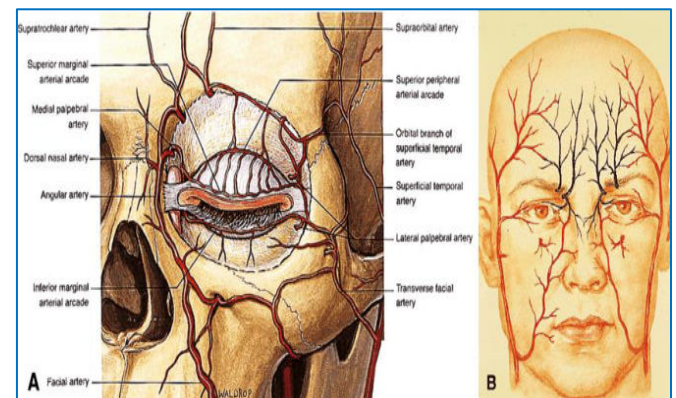


7. Apanga Marma

The *Apangamarmas* are *Siramarmas* measuring half *Angula* (finger) in width. It is located behind and below the tail of eyebrow on either side of head near outer canthus. Injury to this *Marma* can lead to visual disturbance to complete loss of vision (blindness).

Underlying structures

Apangamarma is located behind lateral ridge of orbit formed by zygomatic process. As such no blood vessels are found at this place but injury through *Gada* in ancient time, punch, cricket or tennis ball etc. now a days at this site will cause fracture of zygomatic process involving the greater wing of the sphenoid bone or external force transfer through these bone at optic foramen will cause compression or damage to optic nerve, ophthalmic nerve, ophthalmic artery. External force at this site may directly affect to eye ball and its inner structure like rupture of eye globe, torn retina, dislocation of lens etc will lead to visual disturbance, partial visual loss to blindness.



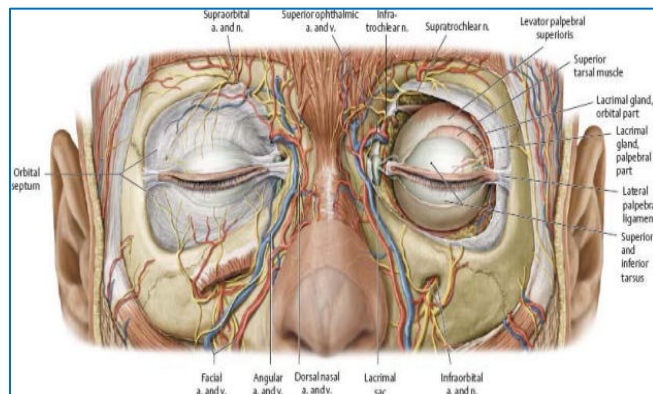
8. Avarta Marma

It is a *Sandhimarma* measuring half *Angula* in width. The term *Avarta* literally indicates the twisting to the curve. As they are located on the curve of eyebrow so called *Avartamarma*. Injury at this site leads to disabled vision to blindness.

Underlying structures

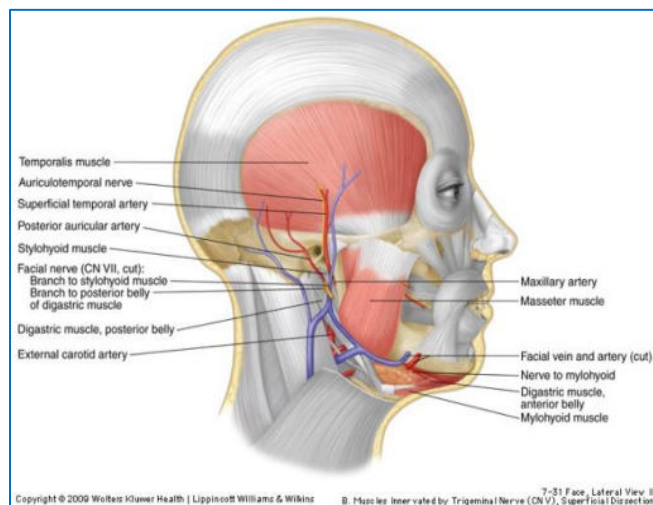
This is in the supraorbital region around supraorbital foramen containing supraorbital nerve and vessels.^[9] Injury at this site will transfer the force through frontal bone to opticnerve, ophthalmic artery at optic foramen and also directly to eye ball after fracture of

base of frontal bone which may cause concussion and injury to optic nerve and eyeball which lead to visual disturbance, partial loss of vision to blindness. Injury to supraorbital nerve, vessels will cause paralysis of lid muscle or haematoma to lid will also cause visual disturbance.



9. Utkshepa Marma

It is situated above the *Shankha Pradesh* (temple region) near the ending of hairs on the scalp (*Keshantah*). It is *Snayumarma* measuring half *Angula* in width. The name of the *Marma* is probably derived from its surgical importance as it belongs to *Vishalyaghana* categories generally means to come out or extract. Immediate removal of the *Shalya* (foreign body) leads to death.



Underlying structures

This correspond to tendon of temporalis muscle underneath this there is superficial temporal artery a branch of external carotid artery and emissary vein which connected to extra cranial vein with intra cranial venous sinuses.^[9] Infection can reach to

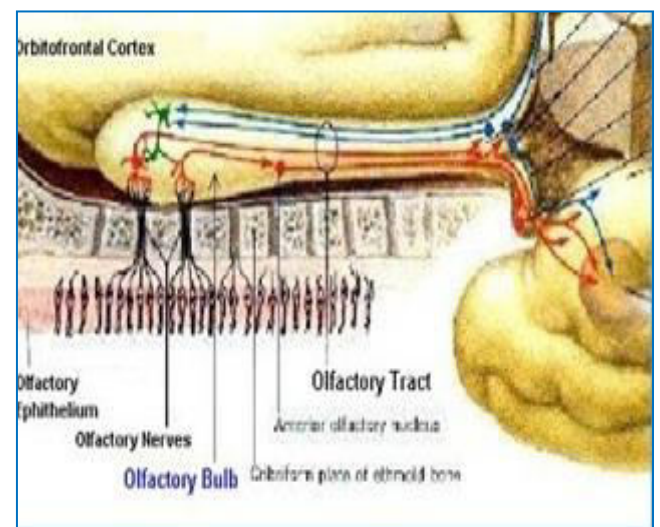
intracranial venous sinuses causing venous thrombosis, ultimately may lead to death.

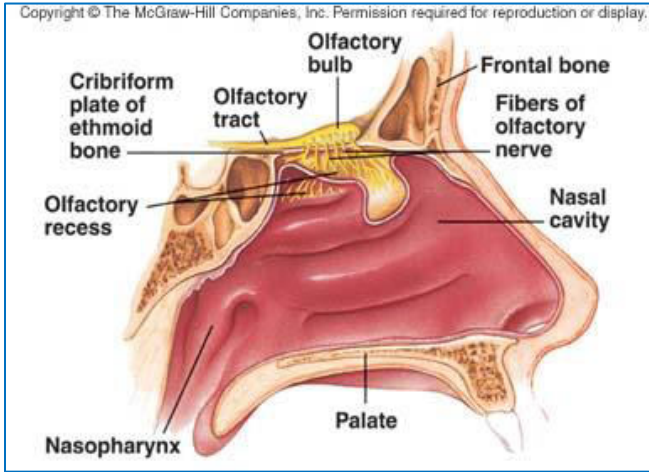
10. Phana Marma

Acharya Susruta, Bhavaprakash and Vagbhatta mentioned that Literal meaning is expanded hood of the serpent and its localised at both side into the nostril. It measures *Ardhaangula* and it is one of the *Vaikalyakaramarma* and its *Viddhalaxana* is *Gandhaagyana*.

Underlying structures

Phanamarma is the conglomeration of *Mamsa, Sira, Snayu, Asthi, Sandhi* i.e. procures and frontal belly of occipito-frontalis muscle, supra trochlear artery, anterior ethmoidal artery and vein, medial palpebral ligament, nasal bone and join between the nasal and lower part of frontal bone which is also named as nasion. Injury to the nasal mucosa, olfactory nerve fibres, olfactory bulbs, or the olfactory tracts may cause impaired smell. In severe head injury, the olfactory bulbs may be torn away from the olfactory nerve fibres, may be torn as they pass through a fractured cribriform plate. If all the nerve bundles on one side are torn, a complete loss of smell will occur on that side consequently. Acharya Sushruta and Vagbhata also said that injury to this *Marma* leads to *Gandhaaganana*.





CONCLUSION

Out of 107 *Marma*, about 37 *Marmas* (34.5 percent) are found above the clavicle (*Urdhawajatrugata*) in neck and head. In these 10 are *Sirogata Marmas*. These are mainly *Vaikalyakara*, *Sadhyapranahara*, in nature and constituted of *Sira*, *Snayu* and *Sandhi*. Injury at these vital points may lead disability of sense organ to death. Therefore head is assigned as *Uttamanga*. Every day peoples come in contact of some accidental injury leading to musculo-skeleton and neurological deformity to death which are dealt with Trauma center in Allopathy science. By knowing the site and constituents of *Marmas*, one can tell about prognosis of damage and also the site of injury by knowing the consequence. It is also important to know while performing surgery or parasurgical procedure. Although there is not much description about exact site, etiopathogenesis of *Marmaghata* in Ayurvedic text so, it is very difficult to predict more over it. But here tried level best to explain the things on the basis of evidence seen in Chinese Medicine, Martial arts, *Marma* massage therapy and Modern Medical Science literature.

REFERENCES

1. Vagbhata, Ashtanga Hridaya, commentary by Brahmananda Tripathi, *Marma* vibhaga sharira chapter

4, Shloka no. 37-38, Chaukhambha Sanskrita Pratishthan, Delhi Re-edition 2012. Pp427

2. Vagbhata, Ashtanga Hridaya, commentary by Brahmananda Tripathi, *Marma* vibhaga sharira chapter 4, Shloka no. 63-65, Chaukhambha Sanskrita Pratishthan, Delhi Re-edition 2012. Pp431

3. Vagbhata, Ashtanga Hridaya, commentary by Brahmananda Tripathi, *Marma* vibhagasharira chapter 4, Shloka no. 68, Chaukhambha Sanskrita Pratishthan, Delhi Re-edition 2012 pp432

4. Sushruta, Sushruta samhita, dalhana commentary by Kaviraj P.V. Sharma, Pratek marma nirdesha sharira chapter 6, shloka no. 27, Chaukhambha Sanskrita Pratishthan, Delhi Re-edition 2012. Pp195

5. Krishna garg, mohini kaul, indrabahl, Textbook of Neuro-Anatomy, CBS Publishers & Distributors New Delhi, Third Edition: 2006. Pp204

6. Gray Henery, Gray Anatomy, Descriptive and applied, longman's, green and co. Ltd., london 29 th Edition. Pp494-496

7. B. D. Chaurasia, Human Anatomy (Head, Neck and Brain part) volume - 3 osteology of head and neck, CBS publishers and Distribution Pvt. Ltd New Delhi, Fifth Edition 2010. pp3-49

8. B. D. Chaurasia, Human Anatomy (Head, Neck and Brain part) volume - 3, cranial cavity, CBS publishers and Distribution Pvt. Ltd New Delhi, Fifth Edition 2010. Pp97-111

9. Keith L. Moore, Arthur F. Dalley, clinical oriented anatomy, 5th edition, Lippincott Williams & Wilkins publishers, pp915,919

How to cite this article: Bhosgikar Anup, Kundu Debasis, Waghmare Ashwinikumar, N. G. Mulimani. Understanding of Calveria *Marmas* w.s.r. *Sirogata Marmas* - An Modern Prospective. J Ayurveda Integr Med Sci 2017;2:206-211.

<http://dx.doi.org/10.21760/jaims.v2i2.7729>

Source of Support: Nil, **Conflict of Interest:** None
