



ISSN 2456-3110

Vol 2 · Issue 2

Mar-Apr 2017

Journal of
**Ayurveda and Integrated
Medical Sciences**

www.jaims.in

JAIMS



Charaka
Publications

Indexed

Multiple Fistula-In-Ano treated by *Kshara Sutra* - A Case Report

Rajesh Yadav,¹ Prashantha K.,² K. R. Ramchandra.³

¹Post Graduate Scholar, ²Associate Professor, ³Professor and Head, Department of PG Studies in Shalyatantra, S.D.M. College of Ayurveda, Kuthpady, Udupi.

ABSTRACT

Fistula-in-ano is a chronic and troublesome disease encountered in general practice. It consists of 1.6% of all surgical admissions and leads to physical, psychological and social problems. The management includes various treatment modalities with variable outcomes. *Ksharasutra* is a medicated thread used in ano-rectal disorders particularly for the management of fistula-in-ano in Ayurveda. In this study *Ksharasutra* was prepared by *Apamarga Kshara* (Ash of *Achyranthus aspera* Linn.), *Snuhi Ksheera* (*Euphorbia neriifolia* Linn.) and turmeric powder (*Curcuma longa* Linn.). A patient with multiple fistula-in-ano was treated by application of *Ksharasutra*. This case study demonstrates the utility of *Ksharasutra* in Multiple Fistula-in ano.

Key words: *Apamarga Kshara, Bhagandara, Snuhi Ksheera, Multiple fistula-in-ano, Ksharasutra.*

INTRODUCTION

Bhagandara (Fistula-In-Ano) is considered one among *Ashtamahagada* (8 dreadful diseases) by Acharya Sushruta and Vagbhata.^{[1],[2]} *Bhagandara* is a disease which causes *Daarana* (mutilation) of *Bhaga*, *Guda* and *Basti* (pelvis and perineum). When it is *Apakva*, it is called as *Pidaka* and when *Pidaka* gets *Pakva* and burst open, the condition is called *Bhagandara*.^[3] This condition is correlated with Fistula-In-Ano which is an inflammatory tract having external opening in perianal skin and internal opening in anal canal or rectum lined by unhealthy granulation tissue or fibrous tissue.^[4]

Fistula may also occur secondary to tuberculosis, carcinoma, Crohn's disease, ulcerative colitis, lymphogranuloma venereum, hidradenitis suppurativa. For reasons that are unknown, non-specific anal fistulae are more common in men than women. The overall incidence is about nine cases per 100000 population per year in Western Europe, and those in their third, fourth and fifth decades of life are most commonly affected.^[5]

Clinical features

Patients usually complain of intermittent purulent discharge (which may be bloody) and pain (which increases until temporary relief occurs when the pus discharges). There is often, but not invariably, a previous episode of acute anorectal sepsis that settled (incompletely) spontaneously or with antibiotics, or which was surgically drained. External opening can be single/multiple with pouting granulation tissue, may discharge blood. Internal opening may be felt as a 'button hole' defect inside the rectum. Tuberculous fistulae do not have induration, will have pale granulation tissue with watery discharge and most often multiple. A horse-shoe fistula may occur when both the ischio-rectal fossae are involved in the disease process.^[6]

Address for correspondence:

Dr. Rajesh Yadav

Post Graduate Scholar, Department of PG Studies in Shalyatantra, S.D.M. College of Ayurveda, Kuthpady, Udupi.

E-mail: rajeshyadav1211@gmail.com

Submission Date : 09/04/2017

Accepted Date: 22/04/2017

Access this article online

Quick Response Code



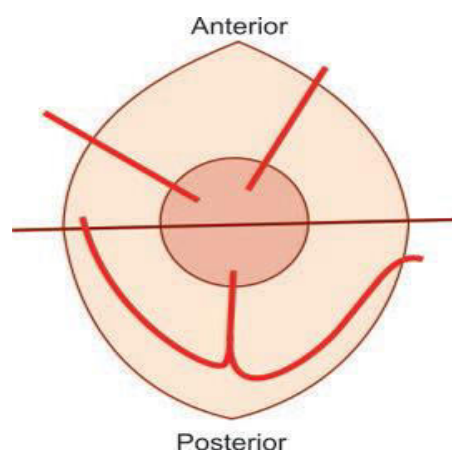
Website: www.jaims.in

DOI: 10.21760/jaims.v2i2.7739

Classifications^[7]

- **Low fistula** - these fistulae open into the anal canal below the anorectal ring.
- **High fistula** - these open into the anal canal at or above the anorectal ring.

Standard classification ^[8]	Park's classification ^[9]
Subcutaneous	Intersphincteric
Submucous	Trans-sphincteric
Low anal	Suprasphincteric
High anal	Extrasphincteric
Pelvirectal	

**Goodsall's rule**

Fistulae with an external opening in relation to the anterior half of the anus is usually of direct type. Fistulae with external openings in relation to posterior half of the anus, have a curved track may be of horseshoe type, open in the midline posteriorly and may present with multiple external openings all connected to a single internal opening. P/R examination shows indurated internal opening usually in the midline posteriorly. Most of the fistulae are on posterior half of anus. Probing in the ward and fistulogram in the ward before surgery using Lipiodol is not advisable as it may cause recrudescence of inflammation.^[10]

Investigations

Chest X-ray, MR fistulogram, Endorectal ultrasound, ESR and Barium enema X-ray.

CASE REPORT

A male patient aged 46 years was referred to Shalyatantra OPD of SDM Ayurveda Hospital, Udupi. The patient had complaints of intermittent parianal pain with blood mixed pus discharge since 3 years. He had approached local practitioner and was taking medicines which used to give him temporary relief. Few months after the medications the episodes of pain and discharge used to recur with increasing severity. During the course of the disease, he complained of development of multiple painful nodules near the anal region. Patient's routine work was affected due to the disease. No associated complaints like fever, debility, weight loss, mucus discharge or abdominal pain was present. He had a normal bowel pattern. Past history was not significant for any medical illness or surgical intervention.

General Examination revealed no pallor, icterus, clubbing, cyanosis, lymphadenopathy or edema. His vitals were BP - 120/80 mmHg, Pulse - 72/min, RR- 20/min, Temp. - 98.4 F. His systemic Examination was unremarkable for cardiorespiratory system, CNS and abdomen.

Local examination

Perineal examination revealed 5 external fistulous openings where 3 external openings on the right side connecting internally at 11 o'clock position and 2 external openings forming a separate fistulous track radially situated at 2 o'clock position. Fistula at 2 o'clock position was measuring 7cm and 3cm from the anal verge on the left buttock and a long fistula tract of 13cm having 3 external openings was seen at 8cm, 5cm, 3cm from the anal verge at 11 o'clock position on the right side. Internal opening was palpated at 11 o'clock position below anorectal ring.

A clinical diagnosis of *Bhagandara*/Low fistula with multiple openings was made and admitted in the hospital for *Ksharasutra* treatment.

MRI REPORT (23-10-2016)

Simple intersphincteric fistulae on the left side. Trans-sphincteric perianal fistulae on the right side with a sinus tract extending into right perineal soft tissues.

Blood Report (23-10-2016)

HB % -14.75gm%, TC - 8.75cells/cu mm, DLC- N-61%, L-34%, E-04%, M-0%. B-0%, ESR-16, Platelet count-2.4lakhs/cu mm, RBC count -5 millions/cu mm, BT-2 min 10 sec, CT-4min 50 sec, RBS - 139mg/dl, Blood group and Rh type-B Positive, HBSAG -Negative, HIV-Negative, Urine Test Report - Urine albumin - nil, Urine Sugar - nil. Microscopic Examination - Epithelial cell - 2-3/HPF, Pus cells - 2-3/HPF, RBC'S - 0-1/HPF, Casts, Crystals, Others - nil.

ECG Report - NAD

Biopsy Report: Gross - Specimen consists of single nodular grey white tissue bit weighs <1gm measures 1.5*1*0.5 cm. Cut section shows grey white area and haemorrhagic areas. Entire specimen submitted in 2.

Microscopic

Section shows hyperkeratotic and acanthotic epidermis elongated rete ridges and intraepidermal neutrophils overlying and adjoining a fistulous tract lined by granulation tissue with adjoining fibrocartilaginous stroma showing dense lymphoplasmocytic infiltrate and congested vessels. No granuloma seen.

Diagnosis - Consistent with non specific Fistulae.

Method of Primary threading**Operative Procedure**

1. Patient under spinal anaesthesia was put in lithotomy position.
2. Part prepared and draped.
3. Through the external opening at 2 o'clock 4 cm from anal canal, a threaded probe was introduced and brought out through another external opening 11 cm from the anal verge.
4. Through the external opening at 11 o'clock position about 5cm from the anal canal, a

threaded probe was introduced and brought out through the internal opening in the anus.

5. A tissue sample from the track was excised for biopsy and through the external opening at 11 o'clock, 5 cm from anal verge, probing was done to get the thread out through another external opening at 13cm from anal verge. Haemostasis secured by pressure.
6. Bandaging was done and patient was shifted to post operative ward.

Post Operative

1. NBM till 4hr
2. IV fluids
3. Foot end elevation for 5 hours
4. Inj. Gentamycin 80 mg bd for 3 days
5. Sitz bath with Panchavalkala kwatha twice daily followed for 3 days in his hospital stay.

Discharge medications : follow up

1. *Triphala Guggulu* - 1 tid
2. *Gandhak Rasayana* - 1 tid
3. *Pancha Tikta Ghrita Guggulu* - 1 tid
4. *Triphala Churna* - 1tsf HS

Subsequent change of Ksharasootra

Ksharasutra was changed by rail- roading method on weekly interval by knotting a fresh *Ksharasutra* to the old thread in the tract and pulling out the old thread. During each subsequent change of thread, length of *Ksharasutra* was measured. Subsequent changing of the *Ksharasutra* continued every week till the tract is completely cut and the *Ksharasutra* fell off.

Duration of treatment

Another external fistulous opening at 1 o'clock position 4 cm from anal verge also developed after previous fistulous track healed. It was also treated by *Ksharasutra*.

Total 80 days for 1st thread (external to external) length 7 cm with unit cutting time 11.42 days/cm, 68 days for second thread (external to internal) length

5cm with unit cutting time 13.6 days/cm, 3 months for third (external to external) length 8cm with unit cutting time 11.25 days/cm and 1 month for 4th thread (external to internal) length 4cm with unit cutting time 7.5 days/cm required for complete cutting and healing of fistulous tracts. The time taken for complete cut through of track differs due to length of track and patient's pain tolerance. The unit cutting time (UCT) = Total no. of days taken for cut through/Initial length of track in cms.

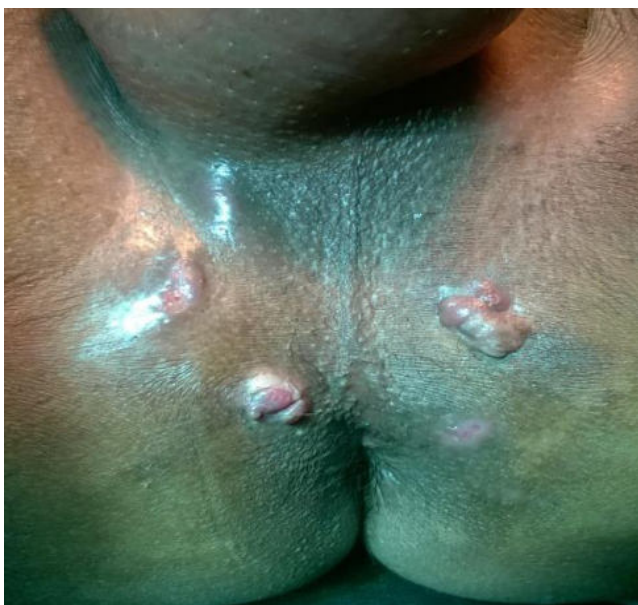

Fig. 1: Before Treatment

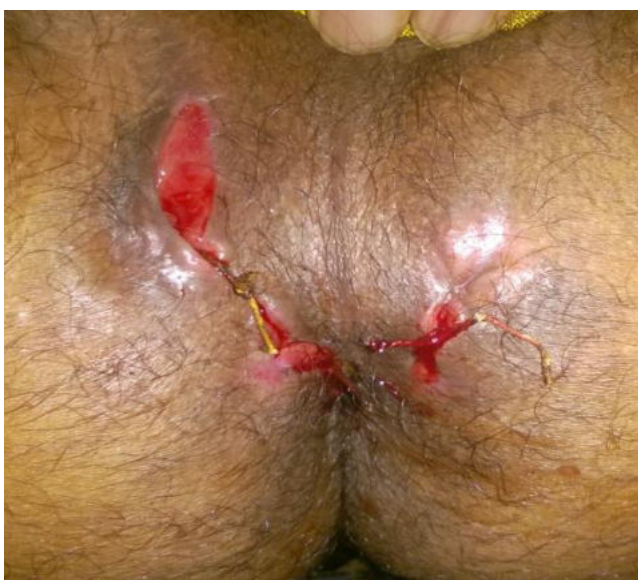

Fig. 2: During Treatment

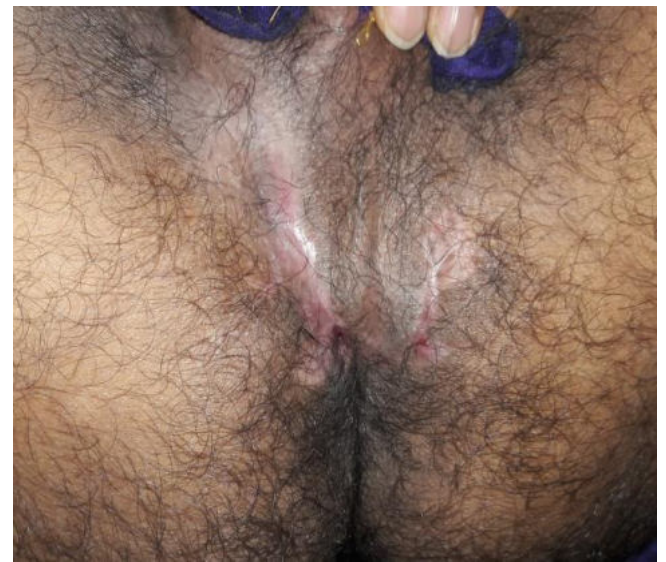

Fig. 3: After Treatment

DISCUSSION

Sushruta advocated different treatment modalities to treat *Bhagandara* (fistula-in-ano) according to *Doshic* types of the fistula. Acharya Sushruta has mentioned 5 types of *Bhagandara* like *Parisravi*, *Shataponaka*, *Shambhukavrat*, *Ushtragreeva* and *Unmargi*. All varieties of *Bhagandara* are difficult to treat.^[11]

Fistula-in-ano, or anal fistula, is a chronic abnormal communication, lined by granulation tissue, which runs outwards from the anorectal lumen (the internal opening) to an external opening on the skin of the perineum or buttock (or rarely, in women, to the vagina).^[12] ICMR (Indian Council of Medical Research) has made an extensive study on *Ksharasutra* in fistula in-ano and concluded that this treatment is better than conventional fistulectomy / fistulotomy with minimum recurrence rate.^[13] *Ksharasutra* is prepared from three herbal drugs (*Apamarga Kshara*,^{[14],[15]} *Snuhi ksheera*,^[16] *turmeric*^{[17],[18]}) and said to be a unique drug formulation for cutting as well as healing of a fistulous tract.

The applied *Apamarga Kshara* on thread has qualities like *Katu*, *Tikta Rasa*, *Laghu*, *Ruksha*, *Tikshna Gunas*, *Ushna Veerya*, *Katu Vipaka*. These properties of the drugs create an unfavourable condition for the progression of the disease. It relieves painful inflammatory condition of the skin. It cleanses

fistulous tract from debris and unhealthy granulations. *Apamarga Kshara* which has *Shodhana* and *Ropana* properties and facilitates the *Vilayana* of the *Pooya* thereby helps in the cleansing of the track.

Snuhi Ksheera^[19] has *Laghu*, *Tikshna Guna*, *Katu Rasa*, *Usna Virya*, *Katu Vipaka*, *Rakta Shodhaka*, *Vedana Sthapana*, *Shothahara*.

Curcuma longa or turmeric powder^{[20],[21]} has quality likes *Ruksha*, *Laghu Guna*, *Tikta*, *Katu Rasa*, *Katu Vipaka*, *Usna Virya*. It is *Shothahara*, *Vedanasthapana*, *Vrana Shodhana*, *Vrana Ropana*, *Lekhana*, *Varnya*. It has antibacterial action on *Staphylococcus aureus*, *Staphylococcus albus* and *Bacillus hyphosus*.

In this case, *Ksharasutra* was applied first time under spinal anesthesia and kept in situ and then *Ksharasutra* was changed after every week. The length of *Ksharasutra* was noted and found decreased on every change which suggested the cutting of fistulous tract. Patient was advised to consult regularly on every week and after 6 months, patient was free from all symptoms of fistula with normal scar and without any complications.

CONCLUSION

This single case study demonstrated that Multiple Fistulae can be effectively treated by *Apamarga Ksharasutra* without any adverse effects. Tissue mutilation being minimum, no bowel incontinence, good thin scar are the end results of the treatment. Another advantage of the treatment is, even with complex fistulae, except for the primary threading requiring a brief stay in the hospital, further course of the treatment can be carried out on OPD basis and patient would be ambulant throughout the course of the treatment and could carry out his duties with tolerable discomfort.

REFERENCES

1. Acharya Sushruta, Sushruta Samhita, Dalhana, Nibandhasangraha commentary, Edited by Jadavji Trikamji Acharya and Naarayana Ram Acharya; Reprint 2013; Sutrasthana, chapter-33, sloka-4, Chaukhamba Sanskrit Sansthan Varanasi. 2013;p.144.

2. Acharya Vagbhata, Ashtanga Hrudaya; Sarvangasundara of Arunadatta & Ayurvedarasayana of Hemadri commentaries, Edited by Pandit Hari Sadasiva Sastri Paradakara; Reprint 2012, Nidanasthana chapter-8,sloka-30, Chaukhamba Sanskrit Sansthan Varanasi, 2012;p.497.
3. Acharya Sushruta, Sushruta Samhita, Dalhana, Nibandhasangraha commentary, Edited by Jadavji Trikamji Acharya and Naarayana Ram Acharya; Reprint 2013; Nidanasthana ,chapter-4,sloka -3, Chaukhambha Sanskrit Sansthan Varanasi; 2013;p.280.
4. S. Das, A Concise Textbook of Surgery. 7th edition January 2012, Published by Dr.S.Das, 13 Old Mayors' Court, Kolkata, 2012;p.1071.
5. Michael J.Earley "Wounds, tissue repair and scars" Chapter 3 in Bailey and Love's short practice of Surgery 73th edition 2008, edited by Norman S.Williams, Christopher JK. Bulstrode and P.Ronan O'Connell, published by Hodder Arnold, Hachette, 2008;p.1259-60.
6. Michael J.Earley "Wounds, tissue repair and scars" Chapter 3 in Bailey and Love's short practice of Surgery 73th edition 2008, edited by Norman S.Williams, Christopher JK. Bulstrode and P.Ronan O'Connell, published by Hodder Arnold, Hachette, 2008;p.1259-60.
7. S. Das, A Concise Textbook of Surgery. 7th edition January 2012, Published by Dr.S.Das, 13 Old Mayors' Court, Kolkata, 2012;p.1072.
8. Sriram Bhat M, SRB's Clinical method in Surgery, Jaypee Brothers Medical Publishers (P) Ltd, 3rd edition, 2009;25:p.917.
9. Bailey & Love's, Short Practice of Surgery; Edited by Norman S Williams, Christopher J K Bulstrode, P Ronan O'Connell; 25th Edition; UK: Hodder Arnold; 2008;p.1263.
10. Sriram Bhat M, SRB's Clinical method in Surgery, Jaypee Brothers Medical Publishers (P) Ltd, 3rd edition, 2009;25:p.917.
11. Sushruta, Sushruta Samhitha, Nibandhasamgraha commentary of Dalhanacharya and NyayachandrikaPanchika commentary of Gayadasa, editor Yadavji Trikamji Acharya, ed. 2014, chikitsa sthana 8th chapter, sloka-3, Chaukhamba Sanskrit Sansthan, 2014;p.438.

12. Bailey & Love's, Short Practice of Surgery; Edited by Norman S Williams, Christopher J K Bulstrode, P Ronan O'Connell; 25th Edition; UK: Hodder Arnold; 2008;p.1262.
13. Shukla NK, Narang R, Nair NG, Radhakrishna S, Satyavati GV. Multicentric Randomized controlled clinical trial of Ksharasootra (Ayurvedic Medicated thread) in the management of Fistula in ano. Indian J Med Res 1991;94:177-85.
14. Gyanendra Pandey. Dravyaguna Vijnana. Vol. 1, 3rd edition. Chaukhambha Krishnadas Academy Varanasi, 2005;p.154-161.
15. D Shanth Kumar Lucas. Dravyaguna Vijnana. Vol. 2, 1st edition, Chaukhambha Vishvabharati Academy, Varanasi, 2008;p.354-358.
16. Acharya Priyavrata Sharma, Dravyaguna Vidnyana, Volume 2, Chaukhamba Publications, Varanasi, October 2013;p.430-432,
17. Gyanendra Pandey. Dravyaguna Vijnana. Vol. 1, 3rd edition. Chaukhambha Krishnadas Academy Varanasi, 2005;p.737-746
18. D Shanth Kumar Lucas. Dravyaguna Vijnana. Vol. 2, 1st edition, Chaukhambha Vishvabharati Academy, Varanasi, 2008;p.411.
19. Acharya Priyavrata Sharma, Dravyaguna Vidnyana, Volume 2, Chaukhamba Publications, Varanasi, October 2013;p.430-432,
20. Gyanendra Pandey. Dravyaguna Vijnana. Vol. 1, 3rd edition. Chaukhambha Krishnadas Academy Varanasi, 2005;p.737-746
21. D Shanth Kumar Lucas. Dravyaguna Vijnana. Vol. 2, 1st edition, Chaukhambha Vishvabharati Academy, Varanasi, 2008;p.411.

How to cite this article: Rajesh Yadav, Prashantha K., K. R. Ramchandra. Multiple Fistula-In-Ano treated by *Kshara Sutra* - A Case Report. J Ayurveda Integr Med Sci 2017;2:247-252.
<http://dx.doi.org/10.21760/jaims.v2i2.7739>

Source of Support: Nil, **Conflict of Interest:** None
