



ISSN 2456-3110

Vol 7 · Issue 10

November 2022

Journal of  
**Ayurveda and Integrated  
Medical Sciences**

*www.jaims.in*

**JAIMS**

An International Journal for Researches in Ayurveda and Allied Sciences



**Maharshi Charaka**  
Ayurveda

Indexed

# The effect of *Yasthimadhu Ghrita Pichu* in Cervical Erosion - A Case Study

Silpa VS<sup>1</sup>, Savita S. Patil<sup>2</sup>

<sup>1</sup>Post Graduate Scholar, Department of Prasuti Tantra and Stree Roga, Sri Sri college of Ayurveda Science and Research, Bengaluru, Karnataka, India.

<sup>2</sup>Professor & HOD, Department of Prasuti Tantra and Stree Roga, Sri Sri college of Ayurveda Science and Research, Bengaluru, Karnataka, India.

## ABSTRACT

Cervical erosion is a physiological state after menarche; the columnar epithelium within the endocervical canal grows and everts exposing the glandular epithelium on the ecto-cervix. The exposed glandular epithelium is gradually replaced by squamous epithelium. Mostly occurs during child bearing age with the symptoms like vaginal discharge, itching, pelvic pain, post coital bleeding dyspareunia. If it is not treated properly leads to cervical cancer. This case study is of a female patient who complained of cervical erosion which was treated with *Ayurvedic Stanika Chikitsa - Yonidhavana* with *Nimba Patra Prakshalana* and *Yasthimadhu Ghrita Pichu* for 7 days. In the present study, *Pichu* with *Yasthimadhu Ghrita* is proved to give good results in cervical erosion. Hence the clinical trial can be done in large number of patients to see further results.

**Key words:** *Yasthimadhu Gritha, Cervical Erosion, Pichu*

## INTRODUCTION

In a fast developing country like India, the female population plays a major role in its human resource at multiple strata of development; hence gynaecological health is an important factor for women's health status. Disease which causes physical or psychological concern to a woman should be immediately taken care of and so equally weighed in medical science. Certain diseases may not be life threatening but it may cause irritations and troublesome to an individual's day today activities. Among them Cervical Erosion is a benign

condition if left untreated may lead up to infertility and predispose to malignancy which is seen in all women and in all age groups.

Cervical erosion is a common gynaecological condition seen in different age groups, of which incidence is 50 - 85 % in females of childbearing age, which needs special attention.<sup>[4]</sup> It is more common in illiterate and women with low literacy status as compared to women with higher education. So, it is very necessary to impart awareness.

In Ayurvedic classics there is no direct reference which explains the erosion of the cervix, but *Vrana* has been dealt with in detail by Sushrutacharya. Here, *Vrana* of *Garbhashaya Mukha* can be closely correlated to cervical erosion. In *Chikitsa Sthana*, *Sushruta* mentions the *Lakshanas* of *Vrana* are classified under *Vedana*, *Srava*, *Akriti*, *Gandha* and *Vaivarnya* all of these can be seen in cervical erosion as well. Hence, *Chikitsa Siddhanta* of *Vrana* can be used to treat cervical erosion.<sup>[5]</sup> Hence an effective, less invasive treatment for cervical erosion devoid of adverse effects which improves women's health is a need of the hour.

### Address for correspondence:

Dr. Silpa VS

Post Graduate Scholar, Department of Prasuti Tantra and Stree Roga, Sri Sri college of Ayurveda Science and Research, Bengaluru, Karnataka, India.

E-mail: drsilpa1018@gmail.com

Submission Date: 13/09/2022 Accepted Date: 22/10/2022

### Access this article online

Quick Response Code



Website: [www.jaims.in](http://www.jaims.in)

Published by Maharshi Charaka  
Ayurveda Organization, Vijayapur,  
Karnataka (Regd) under the license  
CC-by-NC-SA

**CASE REPORT**

**Case description**

A 30 year old married female patient visited OPD with the complaints of P/V whitish discharge since 3 week associated with itching around the vulva and lower abdominal pain since 2 weeks. Patient came here for further management.

Past medical history: No H/O DM /HTN / Thyroid

Past surgical history: No H/O any surgical illness.

Family history: Nill

**General Physical Examination**

Built: Poorly built

Height: 153 cms

Weight: 46.1 kg

Pallor: Absent

Edema: absent

Icterus: absent

Cyanosis: absent

Lymphadenopathy: Absent

**Menstrual history**

<b>Menarche</b>	13 years
<b>LMP</b>	15/3/2021
<b>Menstrual cycle</b>	Regular
<b>Raja Srava</b>	3-4 days 28 –30 days No of pads : D1 : 2 pads 50 % soakage D2 - D3: 100% D4 - Spotting Clots: Absent No foul smell

	Pain: absent Colour: Maroon Consistency: watery Staining of cloth: absent
<b>Obstetric history</b>	Marital life: 2 years Non consanguineous marriage PO AO LO DO
<b>Coital history</b>	3 time/ week
<b>Contraceptive History</b>	Duration: Before 6 months Method: Barrier methods

**On examination**

P/S Vaginal: Vaginal wall congested

Cervix: Erosion +++, Whitish discharge

Foul smell ++

P/V: uterus is anteverted, anti-flexed normal sized, Fornix - free

Assessment

**Vaginal Discharge**

No discharge	
Slight discharge	
Moderate discharge	++
Severe discharge	
Pad using	

Grade: 4

**Colour of Area**

Normal Tissue	
Pink/ Granulation tissue complete	

Red /No granulation	++
Deep red / No granulation	

Grade: 3

**Itching**

Absent	
Occasional	+
Disturbed	
Constant	

Grade: 1

**Backache**

No pain	+
Occasional	
Mild pain	
Moderate pain	
Severe pain	

Grade: 0

**Gandha:** Present

**Contact Bleeding:** Present

**Size: Area of percentage of erosion**

UL - 80%

UR - 45%

LL - 30%

LR - 25 %

Grade: 3

Size measured by using IMITO App<sup>[6]</sup>

Length: 58.57cm

Area: 2008.22cm

Width: 49.28 cm

Circumference: 167.0 cm

**Laboratory findings**

**Pap smear for cervical cytology**

Inflammatory Smear

Negative for intraepithelial lesion or malignancy

**Urinary routine and microscopy**

Albumin - Trace

Sugar: Nill

Microscopy: Pus cell – 30-40

Epi cell – 10-15

**Blood examination**

Hb: 13 gm%

CBC:

TC: 11500 cells/cumm

Neutrophils: 70%

Lymphocytes: 23%

Eosionophils: 06%

Monocytes: 01%

ESR: 15 mmhr

Platelet count: 3.0 lakhs/cumm

HIV: Negative

VDRL: Negative

HbSAg: Negative

**Chikitsa**

Duration: 7 days

Treatment: *Nimba Patra Kashaya Prakshalana* and *Yastimadhu Ghrita Pichu*

Result after 7 days

**Vaginal discharge**

No discharge	+
Slight discharge	

Moderate discharge	
Severe discharge	
Pad using	

Grade 1

**Colour of area**

Normal Tissue	
Pink/ Granulation tissue complete	+
Red /No granulation	
Deep red / No granulation	

Grade 1

**Itching**

Absent	+
Occasional	
Disturbed	
Constant	

Grade: 0

**Back ache**

No pain	+
Occasional	
Mild pain	
Moderate pain	
Severe pain	

Grade: 0

**Gandha:** Absent

**Contact bleeding:** Absent

**Area of Erosion**

Area	UR	UL	LR	LL	Grade
0-25 %	25%	20%	15%	10%	
26-50%					
51-75%					
76-100%					

Size measured by using IMITO App

Length: 51.38cm

Area: 1311.52cm

Width: 51.38cm

Circumference: 141.75 cm

**Follow up on 15<sup>th</sup> day**

P/S: Cervix healthy

No Cervical erosion

No white discharge

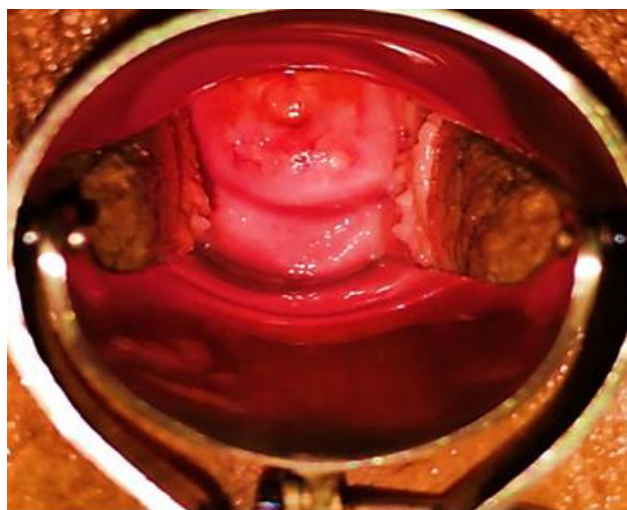
No itching and lower abdominal pain

**DISCUSSION**

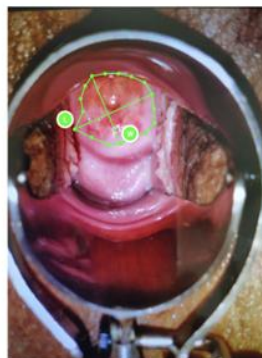
*Yasthimadhu* has *Madhura Rasa*, *Guru Snigdha Guna*, *Sita Virya Madhura Vipaka* which makes it *Vata Pithahara*. As *Yasthimadhu* is *Madhura* in *Rasa* and *Vipaka* it can pacify vitiated *Vata* directly, because of its *Guru Guna* it is capable of reducing the *Laghu Guna* of *Vata* and *Pitta* also the *Snigdha Guna* of the *Dravya* reduces the *Rukshata* of *Vata*. *Yasthimadhu Ghrita* is anti-inflammatory, antibiotic, antiviral, antioxidant, antiulcer in action. Apart from properties like *Daha Samana*, *Shulahara* and *Rakta Sthambaka*. *Yasthimadhu Ghrita* is *Vrana Ropaka* and *Shothagna*. This only indicates the involvement of *Vata* and *Pitta Dosh*a in cervical erosion. *Yasthimadhu* contains glycyrrhizin acid and ammonium salt [GA] which has proven activity of ulcer healing. It contains chemical constituent like glabridin which has the property of anti-oxidant, anti-inflammatory properties. It contains sterols which plays a vital role in cell signalling by

helping regulate then process of development. Licochalcone A is a flavonoid found in liquorice root (*Glycyrrhiza glabra*) having anti-microbial activity. It reduces number of inflammatory cells, and enhanced fibroblasts maturation and tissue alignment and on ulcer healing show increase in the percentage of ulcer contraction and epithelization. As a whole *Yasthimadhu* helped to relief the cervical erosion and symptoms like, *Yoni Srava*, *Yoni Kandu*, and *Gandha*. *Nimba Patra Kashaya* for *Prakshalana*, is explained in *Gadanigraha* under *Yonigaadikarana Adhyaya*. *Nimba* is having *Tikta* and *Kashaya Rasa*, *Kaphahara*, *Krimighna*, *Kandughna* and *Grahi* properties. Quercetin and  $\beta$ -sitosterol were first polyphenolic flavonoids purified from fresh *Neem* and were known to have antifungal and antibacterial activities. Plants parts shows antimicrobial role through inhibitory effect on microbial growth/potentiality of cell wall breakdown. *Nimbidol* and *edunin* are present in leaf which has anti-fungal and anti-microbial property. The *Grahi* property of *Nimba* helped in *Yoni Srava*. *Nimbin* in *neem* leaf has the property of anti -pyretic, thus it acted on *Yoni Kandu* and rashes in the vulva. *Nimbidin* suppresses the functions of macrophages and neutrophils relevant to inflammation and also shows analgesic effect. Thus, it helped in the symptoms of splash dysuria and dyspareunia. As a whole, *Nimba* leaf *Kashaya* helped in relieving the symptoms of like *Yoni Srava*, *Yoni Kandu* and *Yoni Vedana*.

**Before Treatment**

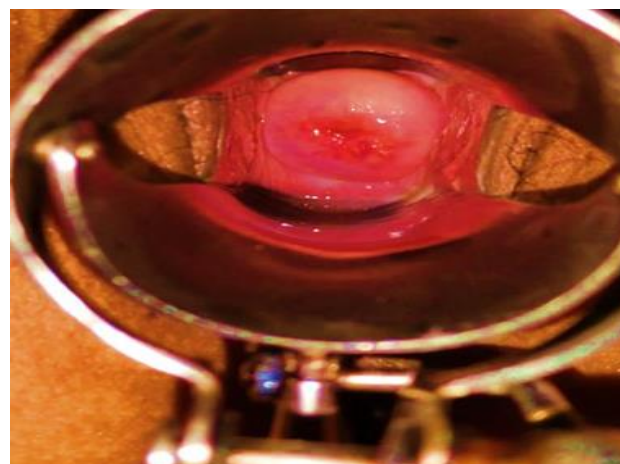


Measurement Report

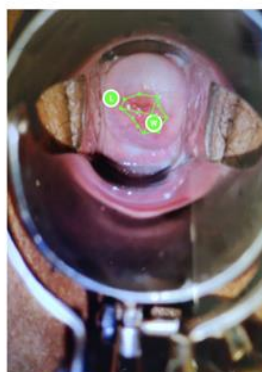

Date: 2022-02-19 07:14  
 Area: 2008.22  
 Width: 49.28  
 Length: 58.57  
 Circumference: 167.0

**After Treatment**



Measurement Report



Date: 2022-02-19 07:18  
 Area: 1311.52  
 Width: 39.71  
 Length: 51.38  
 Circumference: 141.75

**CONCLUSION**

Cervical erosion is the interplay between two epithelia. It is the development of a reddened area on the portio-vaginalis around the external os of the cervix. The

squamous covering of the vaginal part of the cervix is replaced by columnar epithelium, which is usually continuous with that lining of the endocervix. Even though there is no direct reference in Ayurveda, the signs and symptoms of cervical erosion can be categorized under *Pancha Lakshanas* of *Vrana*. Such as *Srava*, *Akriti*, *Gandha*, *Vaivarnya*, *Vedhana*. In this case study the patient had considerable relief from cervical erosion symptoms of cervical erosion is completely resolved. *Yasthimadhu Ghrita Pichu* having *Madhura Rasa*, *Vatapittahara*, *Vrana Shodhana* and *Vranaropana* properties and *Nimba Patra Prakshalana* which has *Tikta* and *Kashya Rasa*, *Krimigna* and *Vrana Ropana* properties above said intervention have directly acted on the vaginal mucosa and enabled easier target specific action and helped to reduce number of inflammatory cells, and enhanced fibroblasts maturation and tissue alignment. On ulcer healing result shows increase in the percentage of ulcer contraction and epithelization. It is also acted on the symptoms i.e., *Yoni Srava*, *Yoni Kandu* and *Yoni Vedana*. The study may be carried out in large number of subject with longer duration to evaluate and analyse the result.

## REFERENCES

1. Anekkalilil S. Gopalapillai: Sharangadhara Samhita Hridayapriya Vyakhyasahitam (malayalam) Madhymakhanda Ch 9. 10th ed. Kodungallur: Devi Books Stall; 2016. p.215.
2. Shah N. Chaganlal, Barath Baishajya Ratnakara, Chadurthabaga, Yakarathi Grita Prakarana, Ver5795, ed 2nd, New delhi: B Jain Publisher;303.
3. Anekkalilil S. Gopalapillai: Sharangadhara Samhita Hridayapriya Vyakhyasahitam (malayalam) Madhymakhanda ch 2. 10th ed. Kodungallur: Devi books stall;2016. p.124.
4. Usha V.N.K. Streeroga Vijnan. New Delhi: Chaukhamba Sanskrit Pratishthan; 2016.p.292-5.
5. Susrutha, Susrutha Samhita, edited by Vaidhya Jadavaji Trikamji Acharya, Narayan Ram Acharya 'kavyatirtha'. Chikitsasthana.Ch.1, Ver.34, Varanasi: Choukhambha Sanskrit Sansthan; 2019. p.46.
6. London, European Wound Management Association" "[date unknown]" Available from <https://ewma.org/resources/>.

**How to cite this article:** Silpa VS, Savita S. Patil. The effect of Yasthimadhu Ghrita Pichu in Cervical Erosion - A Case Study. J Ayurveda Integr Med Sci 2022;10:220-225.

**Source of Support:** Nil, **Conflict of Interest:** None declared.

\*\*\*\*\*