



ISSN 2456-3110

Vol 2 · Issue 3

May - June 2017

Journal of  
**Ayurveda and Integrated  
Medical Sciences**

*www.jaims.in*

JAIMS



Charaka  
Publications

Indexed

# Management of Fistula In Ano (Current Practices)

Vachanashruti,<sup>1</sup> Shashikant Kannade.<sup>2</sup>

<sup>1,2</sup>Physician, Bhagirathi Hospital Main Road Hulsoor, Bidar, Karnataka, India.

## ABSTRACT

Fistula in ano is a disease known to the humanity since ancient times. It is a chronic illness which is, though not fatal but quite discomforting and troublesome to the patient and often puts deep impact on the quality of life of a patient. Despite many advances in medical field, it still poses a big challenge to the surgeon as there is no suitable curative treatment available so far. For the same reason, *Sushruta* has aptly described this disease as one of the *Ashtamahagada*. He was first person to describe the etiology, clinical features and management. So in present article an attempt has been made to enlighten the different treatment methods of *Bhagandara*.

**Key words:** *Bhagandara, Fistula in ano.*

## INTRODUCTION

*Ayurveda* derives its origin from *Atharvaveda* and is also considered as the fifth *Veda* itself. Since the time immortal till today, *Ayurveda* has been serving mankind with its rich traditional resources to allay the sufferings of the society and to preserve the health of people.

Surgical practice has been an inseparable part of *Ayurveda*. *Sushruta* is father of surgery, described *Bhagandara* as one among the *Ashtamahagada*. Which is one of the most burning problem or disease in present era. It is highest commonest disease of ano rectal next to *Arshas* or Hemorrhoids. The management of fistula in ano still remains a surgical challenge. The ideal treatment of a fistula would be effectively close the track with the lowest recurrence rate and fewest complications.

### Address for correspondence:

**Dr. Vachanashruti**

Physician, Bhagirathi Hospital Main Road Hulsoor, Bidar, Karnataka, India.

E-mail: vachanashruti@gmail.com

Submission Date : 05/06/2017

Accepted Date: 24/06/2017

### Access this article online

Quick Response Code



Website: [www.jaims.in](http://www.jaims.in)

DOI: 10.21760/jaims.v2i3.8239

## Management methods (modern approach)<sup>[1],[2],[3]</sup>

1. Fistulotomy
2. Seton
3. Fibrin glue
4. Anal fistula plug
5. Endorectal advancement flap
6. Anocutaneous advancement flap
7. Fistulectomy
8. LIFT (Ligation Of Intersphincteric Fistulous Track)
9. VAAFT (Video Assisted Anal Fistula Treatment)

### 1. Fistulotomy:

The best treatment in terms of absolute cure is to lay open the fistula i.e., fistulotomy. Initially described by John Anderen. Very high fistula should not be laid open where as it is having good result in low fistula.

### Procedure:

Procedure is done in Lithotomy position. After internal and external opening has been identified, the track is laid open with the use of electrocautery or knife between the internal and external opening. The track is defined with a blunt end probe and tissue overlying the probe is divided along its entire length. Granulation tissue along the track is curetted. Portion of the track may be excised and sent for histopathological examination. The cut end of the anal

mucosa may be sewn to the underlying internal sphincter to achieve hemostasis. The wound is left open and gently packed with povidone iodine soaked gauze. In opst operative period sitz bath and daily dressing of wound is required.

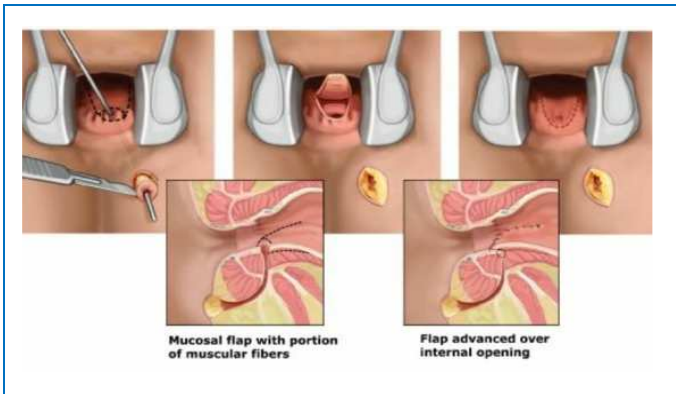


Figure 1: Probing

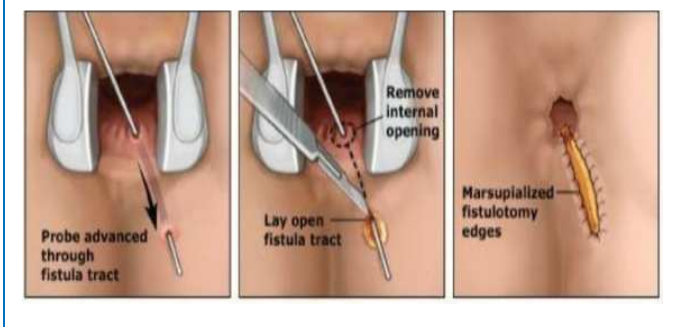


Figure 2: Fistulotomy

## 2. Seton

Seton is a thread of foreign material that is placed in fistulous track. 2 types of seton techniques are used a) the cutting seton, b) the two-staged fistulotomy. In cutting seton method, seton is tied tightly around the track, gradually transect the muscle by pressure necrosis and the fibrosis fixed and prevents retraction of sphincter. In two staged seton method, seton is tied loosely for 2-3 months, followed by fistulotomy is performed in second stage. High complicated fistula are treated by this method.

### Procedure:

This procedure can be done in general anaesthesia according to necessity. After identifying the internal and external opening, the index finger of one hand is passed into the anal canal and a silver malleable probe is passed into fistulous track gradually with seton. After withdrawing probe seton is tied. Cutting

seton is to be tighten where as two staged is to be kept loose.

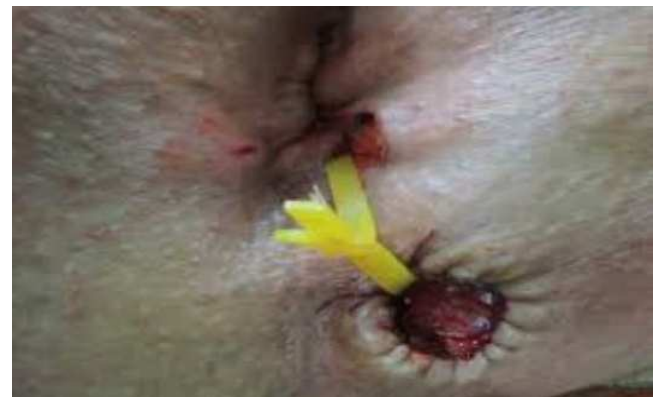

Figure 3: Seton tied

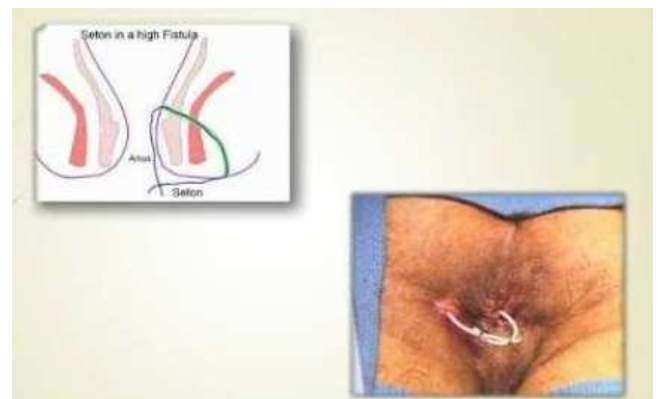


Figure 4: Seton tied

## 3. Fibrin Glue

It helps in the treatment of fistula by two ways. First, the occlusion of the fistulous track with sealant immediately stops the ongoing contamination of the track with the stool, mucous, blood, pus. Along with human proteins in the sealant serves as chemotactic agent, attracting fibroblast and other cells required for wound healing.

### Procedure:

Patient should be given enema. Then positioned in lithotomy position. Internal opening is identified as it is mandatory, because a catheter has to be passed all the way through track upto internal opening. Track is debrided with un folded guaze piece, then curettage is done with curette. Aggressive curettage is avoided to maintain narrowness of track. Further cleaned by using hydrogen peroxide or saline. Avoid usage of povidone iodine as it destabilizes fibrin clot. Thread is tied to catheter and pulled into fistula and drags the

catheter with it.the sealant is then injected at internal opening and allowed to set. Once clot is stabilizes, catheter is withdrawn. Sealant being injected.

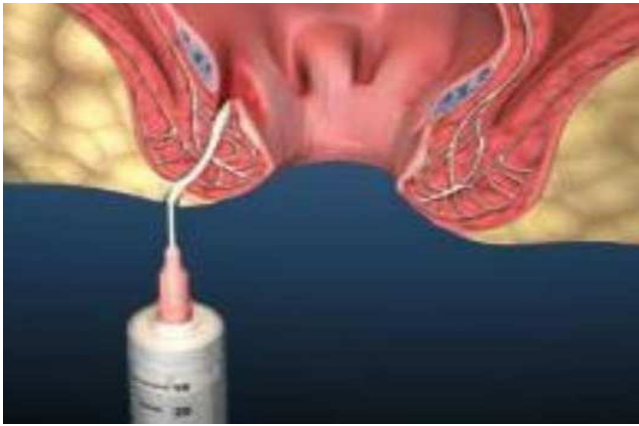

Figure 5: Fibrin Glue method

#### 4. Anal Fistula Plug

It is one of the newest therapy. It is cone shaped bioprosthetic plug made from porcine small intestine submucosa, introduced by Armstrong.

##### Procedure:

Procedure can be performed under local, regional and general anesthesia. A probe is introduced through track.a suture seton is placed and subsequently tied to the narrow end of the anal fistula plug for pulling it into the track. Anal fistula plug is drawn into the internal opening and through fistula track until slight resistance is felt, mean while plug securely blocks the internal opening. Both ends of plug are sutured in place with suitable reabsorbable suture to adjacent tissue. Where as plug in ext.opening is sutured to the skin. Ext.opening is kept open for drainage.

#### Fistula Plug

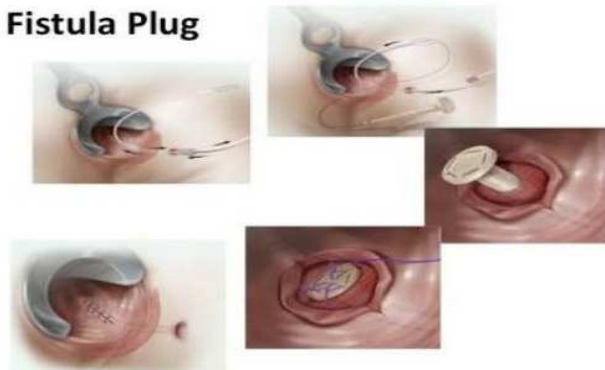

Figure 6: Fistula plug

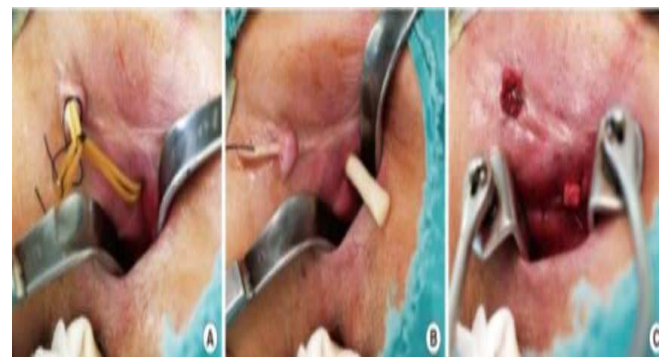

Figure 7: Fistula plug

#### 5. Endorectal Advancement Flaps

Mucosal advancement flaps are used particularly for extra sphincteric and suprasphincteric fistulae. The principle of technique is; to cover the internal opening by internal sphincter and rectal mucosa is advanced from above and, at the same time opening external component of fistula and draining any coexisting sepsis.

##### Procedure:

It is done under general anaesthesia and urinary catheterization, in lithotomy position. The first stage involves careful dissection of the primary track i.e, coring out procedure. The creation of flaps is started just below the dentate line and proceeded in the cephaland direction (upward). The flap should include mucosa and full thickness internal sphincter. The flap should be mobilized generously to allow the caudate fixation of the flap without tension. Distal part of the track including the internal fistulous opening is then trimmed. Defect in the internal and external sphincteric muscle closed with absorbable suture after removing flap. Caudate fixation of flap done, ext. wound left open.

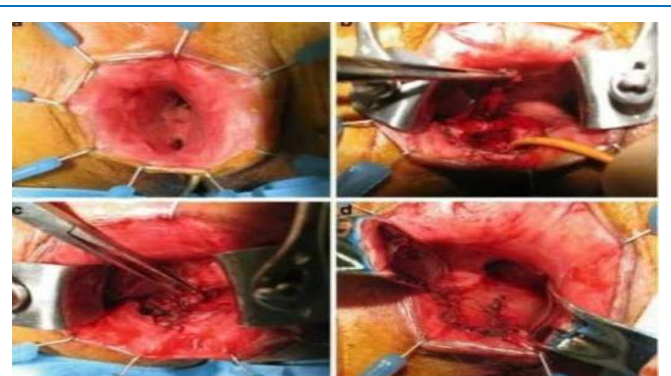


Figure 8: Endo rectal flap

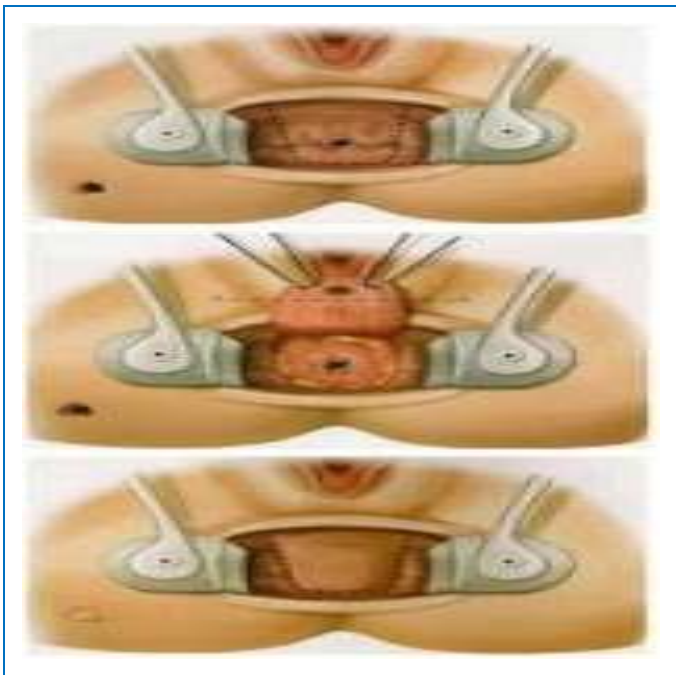


Figure 9: Endo rectal flap

**6. Anocutaneous Advancement Flap**

The fistula crossing the external sphincter in middle or upper 1/3<sup>rd</sup> especially in patients undergone one or more previous repairs. Anal anatomy is not altered.

**Procedure:**

Done under prone jack knife position. Internal opening of the fistula is exposed using lone star retractor system. The crypt bearing tissue around the internal opening and track from the external sphincter is excised. The defect in the internal sphincter is closed with absorbable suture, a 'U' shaped flap is advanced and sutured to mucosa and underlying int.sphincter using interrupted single layer suture. Perianal wound is left open and advised to take Sitz bath frequently.

**7. Fistulectomy**

Excision of fistulous track is done. Careful dissection around fistulous track through to its internal opening, if side track is present excised similarly. Defect in external sphincter requires close . Even though technique preserves anal sphincter function, there is high recurrence rate. Because of breakdown of the closure site.

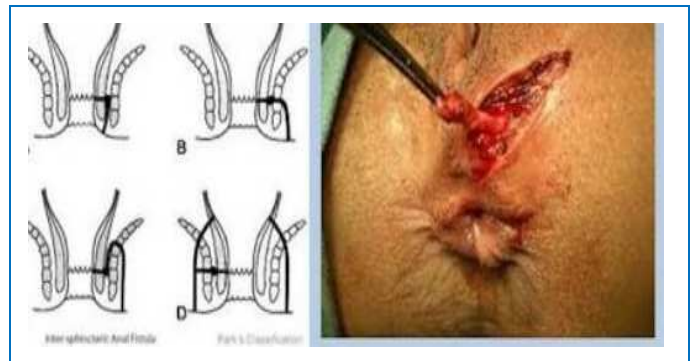


Figure 10: Fistulotomy

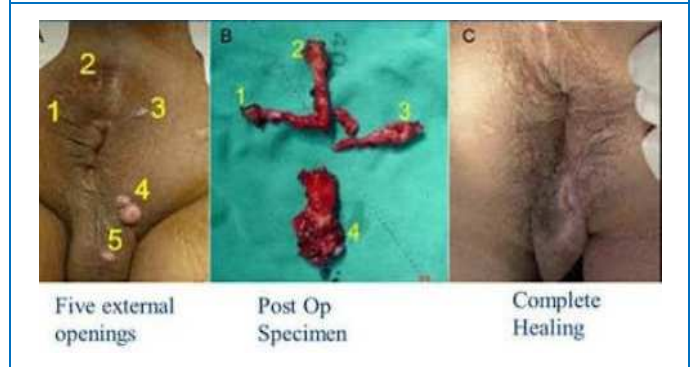


Figure 11: Fistulotomy

**8. LIFT ( Ligation of Intersphincteric Fistulous Track):**

This procedure aims at total anal sphincteric preservation and is applicable especially in fistula of intersphincteric variety. It involves 2 steps. Removal of infected crypts and secured closure of internal opening. Internal opening identified. Incision at intersphincteric groove. Intersphincteric track identification. Scrapping out all unhealthy granulation tissue. Removal of infected crypts. Suturing of defects. Procedure prevents entry of faecal material into fistula and eliminates formation of septic sinus in intersphincteric space allowing healing of anal fistula.

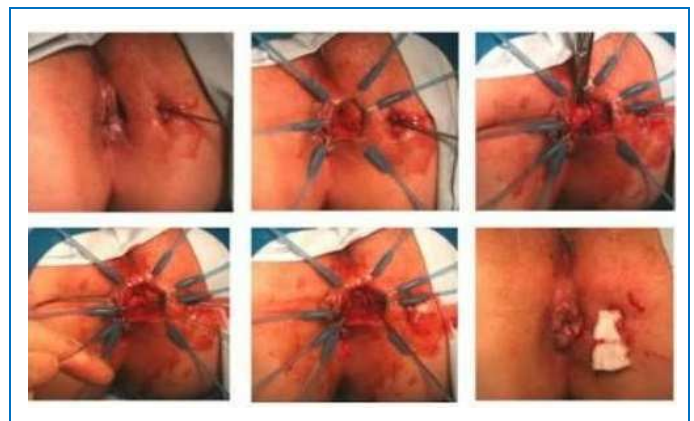


Figure 12: LIFT

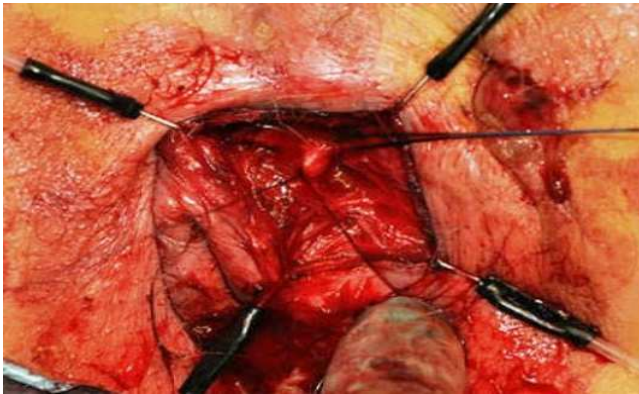


Figure 13: LIFT

### 9. VAAFT (Video Assisted Anal Fistula treatment)

This procedure involves use of an endoscope or fistuloscope. Fistuloscope is introduced through ext. opening of fistula and int. opening is identified where light is reflected. Purse string suture is taken around internal opening so as to close it snugly. A semicircular or linear stapler can also be used for this purpose. Then fistulous track is debrided with fistula brush and scrapping is sent to histopathological examination. A fibrin is injected near the inner end coagulation of whole wall is done with electrode. In this procedure localization of internal opening is done and no surgical wound postoperatively.

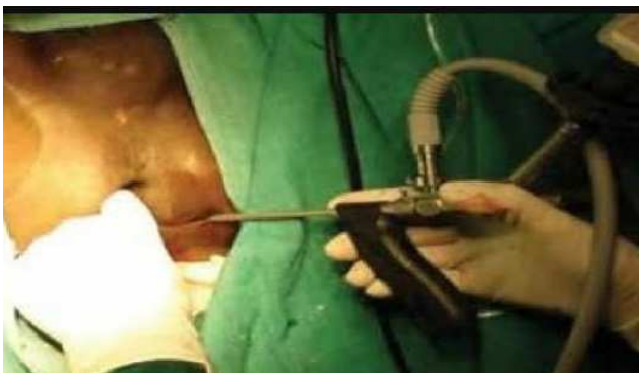

Figure 14: VAAFT

### Bhagandara Chikitsa Ayurvedic approach<sup>[3],[4],[5]</sup>

Management of *Bhagandara*

1. Preventive
2. Curative - Medical, Surgical and Parasurgical.

#### Preventive Measures

Diet: *Guru* (heavy food), *Madya* (excess of alcohol), *Asatmyaahara* (unwholesome food), *Virudhaahara*

(antagonist to each other), *Vishamaahara* (incompatible foods).

Life style: strenuous exercise, excessive coitus, anger, uncomfortable riding, suppression of natural urge.

#### Curative Measures

##### Medical management

*Chedana* is choice of treatment in *Bhagandara*, but medical manage have also its own importance. As it helps in localizing inflammatory and suppuration, facilitates spontaneous drainage of pus in fistulous abscess, post operative care of the patient, wound management. Some of classical preparations being used orally are - *Narayana Rasa*, *Navakarshika Guggulu*, *Saptavinshako Guggulu*, *Saptanga Guggulu*, *Vidangadileha* etc. which acts as both systemic and local.

##### Application of *Vartee* (medicated wick)

*Vartee* made up of *Ksharadravya* are used. By virtue of *Ksharana* (liquefying) property of *Kshara*, it removes the slough and cleans the fistulous track, thus facilitates drainage. It is commonly used in blind tracks. And is also before fistulogram to clean the track. Eg: *Vartee* made up of latex of *Snuhi* (*Euphorbia nerifolia*), *Arka* (*Calotropisprocera*) along with *Daruharidra* (*Berberis aristata*).

##### Application Of *Kalka* (medicated paste)

*Kalka* made up of drugs like *Tila* (*Sesamum indicum*), *Haritaki* (*Terminalia chebula*), *Lodhra* (*Symplocos racemosa*), *Reeta* (*Sapindus trifoliatus*), *Haridra* (*Curcuma longa*), *Vacha* (*Acorus calamus*) etc. are used.

##### Application of *Kashaya* (decoction)

*Kashaya* are use for washing purpose and also it reduces inflammation, pain. Eg: *Triphala Kashaya*, *Kashaya* made up of *Khadira*, *Triphala*, *Guggulu*, *Vidanga*.

##### Application of *Taila* (medicated oil)

These are useful in controlling wound infection and promotes healing. Eg: *Vishyanadana Taila*, *Karaviradi Taila*, *Nishadi Taila*, *Saindavadi Taila*.

##### Surgical management

General principle of management of *Bhagandara* are;

- a) *Virechana* (enema for bowel expulsion)
- b) *Eshana* (probing)
- c) *Chedana* (excision) / *Patana* (laying open of the track)
- d) *Margavishodana* (cleansing of fistulous track)
- e) *Dahana* (cauterization)
- f) *Vranachikitsa* (post op wound management)
- g) *Ksharasutra* therapy (laying open of track using *Ksharasutra*, for those persons who are not willing for surgery).

**Purvakarma:** patient is asked to be nil by mouth, *Koshtashuddi* (enema) and part preparation are done.

**Pradhanakarma:** Identification of internal opening and excision of fistulous track is of prime importance in management of *Bhagandara*. Depending on type of *Bhagandara* different types of incisions are taken.

- a) **Management of *Shataponaka Bhagandara*:** It is characterized by multiple tracks, also known as 'Watering can perineum'. Laying open of all tracks at a time may lead to damage to anal canal and rectum, excessive damage of perianal area, severe pain, infection, delayed healing, other complications. So one or two tracks are layedopen .choice for incision are- *Langalaka*(T, $\gamma$ , $\lambda$ , $\perp$  shaped incisions) , *Ardhalangalaka* (r, L shped incisions), *Goteerthaka* (incision resembling cow's hoof or semicircular incision along with central extention).
- b) **Management of *Ushtragreeva Bhagandara*:** No specific type of incision has been described and incisions can be planned as needed to remove unhealthy tissue or excise the fistulous track.
- c) **Management of *Parisravi Bhagandara*:** The fistulous track along with the cavity should be identified and excised or layed open. Type of incision – *Karjurapatraka* (V shaped incision), *Ardhachandra* (semilunar incision), *Chandrachakra* (circular incision), *Suchimukha* (cone shaped incision with the tip towards anal margin), *Awangmukha* (same as *Suchimukha* but tip of cone is away from anal margin).
- d) **Management of *Unmargi Bhagandara*:** It arises due to impaction of foreign body in *Guda* and

requires removal of foreign body by appropriate surgical intervention.

- e) **Management of *Arshabhagandara*:** A type of fistula in ano secondary to fissure bed infection and associated with sentinel tag. Here, it is advised to excise the tag and fissure bed prior to *ksharasutra* therapy. Otherwise the tag may get inflamed during therapy and causes significant discomfort to patient.

**Pashchat Karma:** Post operative care is aimed to achieve - pain management, wound management, bowel regulation, prevention of recurrence.

#### Parasurgical Measure

- a) *Raktamokshana*
- b) *Agnikarma*
- c) *Kshrakarma*

**Rakamokshana:** *Jaloukavachrana* is one of common method of *Raktamokshana*. It prevents suppuration of *Bhagandarapidaka*. Minimizes inflammation and infection in post operative period.

**Agnikarma:** It is adopted in all kind of *Bhagandara* except *Ushtragreeva*. It prevents recurrence and during procedure act as haemostatic.

**Ksharakarma:** It can done by using *Sutra*, *Vartee*, *Pichu*, local application in the form of paste is done. Helps in management of wound by removing unhealthy tissue from track, cleanses track, promotes wound healing.

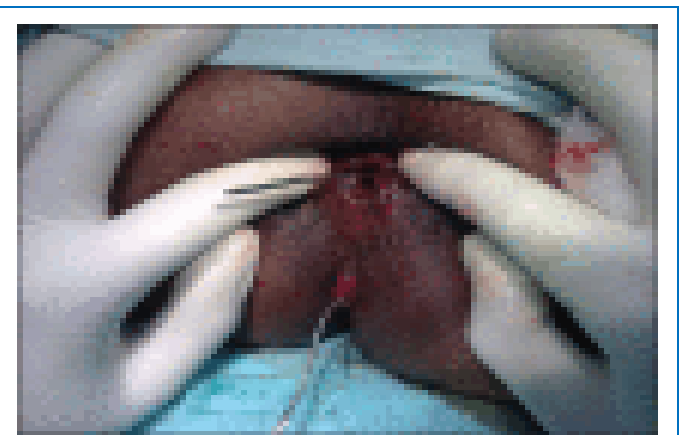

Figure 15: Probing

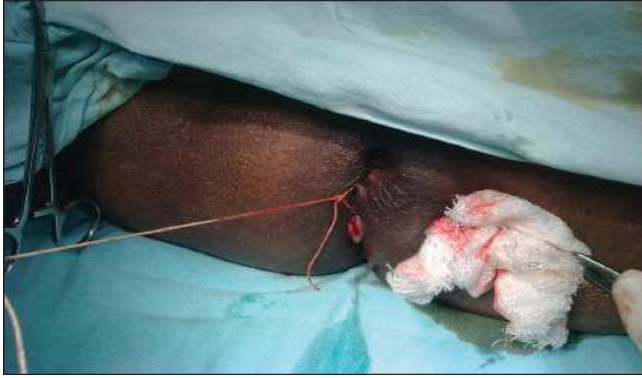

Figure 16: Ksharasutra tied

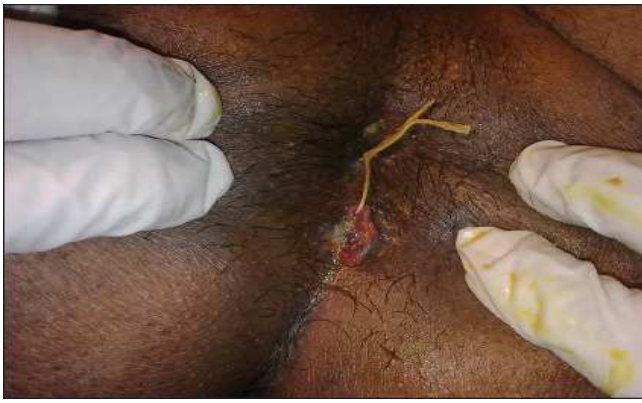

Figure 17: Ksharasutra changed

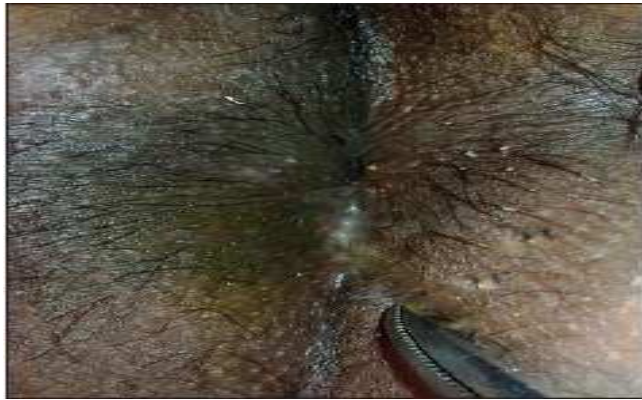

Figure 18: Complete healing of track

## REFERENCES

1. Endorectal Advancement Flap Repair Of Rectovaginal And Other Complicated Anorectal Fistula;;Kodnerlj, Mazor A, Shemeth GI .Surgery 1993;114:682-690.
2. Seton Treatment Of High Anal Fistula. Williams JG, Macleod CAH, Goldberg SM.Br J Surg 1991;78: 1159-1161.
3. A Manual On Fistula In AnoAnd Ksharasutra Therapy. Dr M Sahu, 2015, 95-113.
4. SushrutaSamhita,Kaviraj Ambikadatta Shastri, Purvaardha, choukhamba sanskrit sansthan vaarnasi, chikitsa sthana 8 chup,p.57.
5. Sushrut Samhita, with Darshana Commentry by Vaidya Jadavji Trikamji Acharya, Choukhamba Surabharati Prakashan, Varanasi, Chikitsa Sthana 8 chup, 2010;p.438.

**How to cite this article:** Vachanashruti, Shashikant Kannade. Management of Fistula In Ano (Current Practices). J Ayurveda Integr Med Sci 2017;3:252-258. <http://dx.doi.org/10.21760/jaims.v2i3.8239>

**Source of Support:** Nil, **Conflict of Interest:** None declared.

\*\*\*\*\*