



ISSN 2456-3110

Vol 2 · Issue 4

July - Aug. 2017

Journal of
**Ayurveda and Integrated
Medical Sciences**

www.jaims.in

JAIMS



Charaka
Publications

Indexed

Management of Pilonidal Sinus (*Nadi Vrana*) with *Palasha Kshara Sutra* prepared in *Arka Ksheera* - A Case Study

Leena Nayak,¹ Ganapathi Rao,² Ashok Naikar,³ Jyothi Rajole⁴

^{1,2}Post Graduate Scholar, ³Associate Professor, ⁴Assistant Professor, Department of Shalya Tantra, N.K.J Ayurvedic Medical College & P.G.Center, Bidar, Karnataka, India.

ABSTRACT

Pilonidal Sinus is a common chronic disorder mainly seen in the sacrococcygeal region, especially in young males. Different surgical methods have been described for this disorder. The most commonly used are excision and primary closure and excision with reconstructive flap. However the risk of recurrence or developing an infection of the wound after the operation is high. The patient requires longer hospitalization and the procedure is expensive. There is a similarity between pilonidal sinus and *Shalyaja Nadi Vrana* described in *Susruta Samhita*. *Susruta* has advocated a minimally invasive parasurgical treatment, viz., *Kshara Sutra* procedure, for *Naadivrana*. Hence this procedure was tried in Pilonidal Sinus. This treatment not only minimizes complication and recurrence, but also enables the patient to resume work quicker and with less discomfort.

Key words: Pilonidal Sinus, Nadi Vrana, Ksharasutra, Palasha Kshara.

INTRODUCTION

Ayurveda the indigenous system of medicine is an integral part of Indian culture. The ancient *Acharyas* from centuries had used polyherbal and herbomineral formulations for prevention and treatment of various ailments. In the present era, there is noted insurgence demand among the consumers because of holistic approach.^[1]

Pilonidal sinus is a common condition which we see in current surgical practice, which is raising problem and challenge to practicing surgeon, it is a sinus track which commonly contains hair. It occurs under the

skin between the buttocks (the natal cleft) at a short distance above the sinus. The sinus track goes in a vertical direction between the buttocks.^[2]

Most cases occur in young male adults. The origin of pilonidal disease is not fully understood, although presence of hair, friction and infection are often implicated. The most commonly used therapy is surgery including wide excision and healing by secondary intention. However, post operative recurrence following surgery is high, leading to frequent and time consuming wound care.^[3]

Hence there is a need to evaluate the role of the other alternative techniques for the management of this disease, so as to minimise recurrence, make it effective, with improved acceptability and minimum hospitalization. *Susruta Samhita*, describes a condition *Shalyaja Nadi Vrana* which is similar to pilonidal sinus. *Shalyaja Nadi Vrana* is a track which is described to be due to presence of pus, fibrosed unhealthy tissue and hair etc. inside left unnoticed. *Susruta* has advocated a very unique minimally invasive treatment i.e. *Kshara Sutra* procedure for management of *Nadi Vrana*.^[4] *Ksharasutra* is a medicated thread coated with herbal drugs and rendered alkaline. The introduction of *Kshara Sutra* into the fistulous tract gradually

Address for correspondence:

Dr. Leena Naik

Post Graduate Scholar, Department of PG Studies in Shalya Tantra, N. K. Jabshetty Ayurvedic Medical College & PG Centre, Bidar, Karnataka, India.

E-mail: leenanayak43@gmail.com

Submission Date : 13/08/2017

Accepted Date: 27/08/2017

Access this article online

Quick Response Code



Website: www.jaims.in

DOI: 10.21760/jaims.v2i4.9368

dissolves the fibrous tissue, drain the pus and enhance the granulation in the tract.^[5]

CASE HISTORY

A 21 year old male patient present with complaints of pain and foul smelling discharge from low back region between the buttocks since 1 year. Initially he noticed mild swelling at natal cleft with intermittent dull aching pain which was there for one week. Later he noticed foul smelling pus discharge associated with mild itching in that area. He used to feel discomfort in this region during sitting and bending. He neglected it even though it used to interfere with his daily activities. Whenever there was little injury to the area, pain and bleeding was noticed for which he consulted a local physician to get rid of pain.

Again he noticed mild swelling in natal cleft with intermittent dull aching pain and pus discharge since 6 months. Symptoms used to aggravate by travelling on his bike and profuse sweating. For the above said complaints he consulted our opd in S.R.T.A.M.C on 9 october 2015.

On examination

- Well built, moderately nourished, PEIC- absent and L nodes - no enlargement noticed
- Vitals are stable
- RS - NAD, CVS - NAD, GS - P/A- soft, non tender, BS++, PR - NAD

Examination of sinus

Inspection

- Number - 2 sinuses
- Position of sinus - 2 openings in the midline of natal cleft just above the buttocks.

Opening of the sinus

- Presence of tuft of hairs seen
- Margin - normal

Discharge

- Pus discharge present with foul smell and inflamed surrounding skin

Table 1: Properties of Kshara^[5]

| | |
|----------|--|
| Rasa | Katu |
| Veerya | Ushna |
| Varna | Shukla |
| Guna | Soumya, Tikshna, Agneya |
| Doshagna | Tridoshaghna |
| Karma | Dahana, Pachana, Darana, Vilayana, Shodhana, Ropana, Shoshana. |

In the preparation of *Palasha Ksharasutra* three herbal drugs had been taken namely;

- Arka Ksheera - 11 coatings
- Arka Ksheera + *Palasha Kshara* - 7 coatings
- Arka Ksheera + *Haridra Churna* - 3 coatings

This was prepared in the hospital using Barbour's thread number 20. One coating was applied each day and kept for drying in the *Ksharasutra* cabinet. A total of 21 days was needed to complete the preparation of the thread.

After this the threads were cut in 2 sizes; Medium length - 25cm, small length - 16cm and packed in a sterile sealed pack after placing in the UV cabinet with a small pack of silica inside to absorb moisture. All of these were then packed in air tight container and stored keeping it away from contact with any moisture.

Sinus probing

- Two sinuses (p1 and p2) were inter connected with a depth of 3 cms directed downwards. There was blood mixed pus discharge and hair on withdrawal of the probe.
- Laboratory investigations are within the normal limits

Application of Ksharasutra^[6]

Pre-operative

The written inform consent was taken for the procedure as well as for publication of this case in Journal.

The *Ksharasutra* prepared with *Palasha* as per standard protocol was used. Before application of *Kshara Sutra*, patient was advised to maintain proper local part preparation and general hygiene.

Operative

Patient was placed in prone position and under aseptic precaution probing was done. Probe was passed onto the p1 opening; gradually extended to the other opening and before taking it out, a sterile plain surgical linen thread Barbour number 20 was threaded into the eye of probe, present at tail end and then probe was taken out through p2.

Post operative

From next morning, sitz bath/*Avagaha Sweda* (warm water + *Panchavalkala* decoction) was advised for two times. Diets like green vegetables, fruits was advised. Patient was advised not to consume non-vegetarian, spicy and oily food, Junk foods, alcohol. Patient was advised to avoid long sitting and riding/travelling. Haritaki 5gm + Saindhav Churna 1gm with luke warm water two times a day was prescribed if patient felt constipated.

One week later, the old thread was replaced by new *Ksharsutra* by railroad technique. After replacement of the *Kshara Sutra*, the patient advised to continue his normal routine work. And the *Kshara Sutra* was changed weekly.

RESULTS

There was considerable changes found on various parameter which was as follows,

Table 2: Assessment during treatment.

| SN | Date of thread change | Discharge | Pain | Tenderness | Itching |
|----|-----------------------|-----------|------|------------|---------|
| 1. | 9 October 2015 | +++ | +++ | +++ | +++ |
| 2. | 14 October 2015 | ++ | ++ | ++ | + |

| | | | | | |
|----|-----------------|---|---|---|---|
| 3. | 21 October 2015 | + | - | - | - |
| 4. | 27 October 2015 | - | - | - | - |

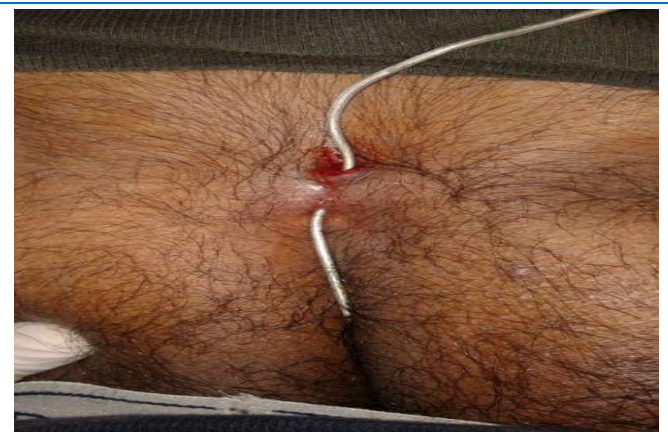

Fig. 1: Probing of Pilonidal sinus

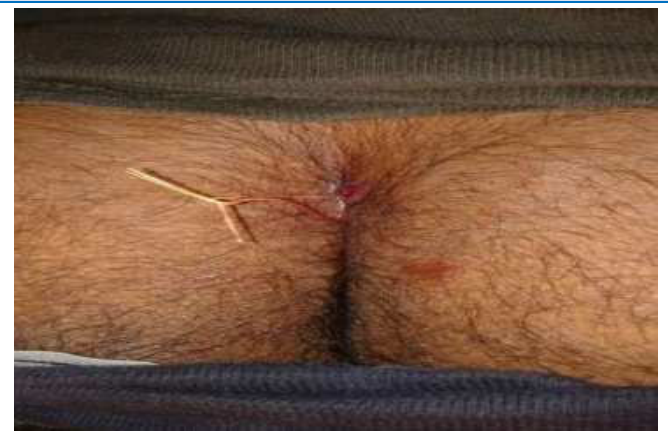


Fig. 2: Kshara Sutra ligation

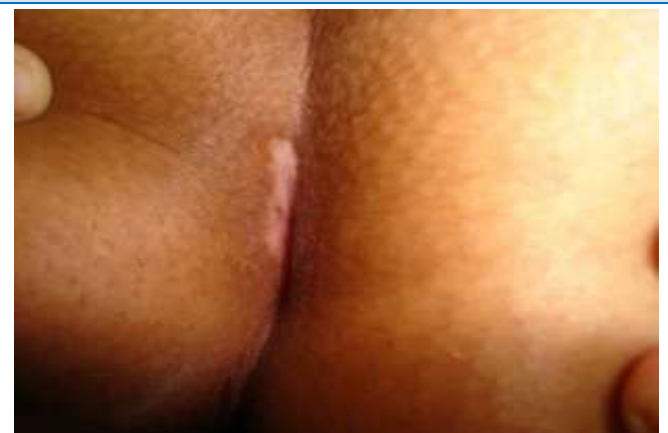

Fig. 3: After complete healing scar formation

CONCLUSION

The management of pilonidal sinus in an effective manner has been a challenge to the surgeon world over. The conventional operative treatment of pilonidal sinus is to lay open or completely excise the fistulous track and allow healing by open granulation. Pilonidal sinus is known to be predominantly a jeep drivers disease. The *Kshara Sutra* therapy in pilonidal sinus can be considered as preferable method of treatment for the following reasons, It is technically easy, safe, simple and does not require any special hospitalisation. It can be carried out in the outpatient department, as most of cases do not require any anaesthesia also, it is considered as cost effective treatment as compared to others. The rate of recurrence after the treatment is negligible. No systemic side effects are encountered with *Kshara Sutra* therapy and post operative tissue damage and scarring are minimal.

REFERENCES

1. Dr. Das S. A Concise Text Book of Surgery, Publisher Dr.Das S. 5th edition, reprinted 2009:11;p.133.
2. Bailey and Love's Short Practice of Surgery, 24th edition. edited by R C G Russell, Norman S.Williams, P-1249-1252
3. Sri Ram Bhat. M. S R B'S Manual of Surgery , 4th edition, Jaypee Publication. Chapter 25 rectum and anal canal p.1036-1038
4. Shashtri KAD, Sushruta Samhitha, Edition 2014, Choukambha Sanskrit Sansthan Publishers, Varanasi, 2014;p.57-62
5. Deshpande P.G., Pathak SN, The Treatment of Fistula in Ano with Ksharasutra treatment, Nagarjuna Edition, Varanasi, 1965;p.361-367
6. Shastri Kaviraj Ambikadatta, Sushruta Samhita, Choukhamba Sansthan Publishers, Varanasi, Edition 2014;p.47

How to cite this article: Leena Nayak, Ganapathi Rao, Ashok Naikar, Jyothi Rajole. Management of Pilonidal Sinus (Nadi Vrana) with Palasha Kshara Sutra prepared in Arka Ksheera - A Case Study. J Ayurveda Integr Med Sci 2017;4:284-287.
<http://dx.doi.org/10.21760/jaims.v2i4.9368>

Source of Support: Nil, **Conflict of Interest:** None declared.
