

## Ayurvedic management of Vaipadika - A Case Study

Nataraj HR<sup>1</sup>, Akarsha Krishna S<sup>2\*</sup>, Ashwin Kumar S Bharathi<sup>3</sup>, Soniya MP<sup>4</sup>, Niranjan RN<sup>5</sup>

DOI:10.21760/jaims.10.1.35

<sup>1</sup> Nataraj HR, Associate Professor, Department of Agada Tantra, Sri Dharmasthala Manjunateshwara College of Ayurveda and Hospital, Hassan, Karnataka, India.

<sup>2\*</sup> Akarsha Krishna S, Post Graduate Scholar, Department of Agada Tantra, Sri Dharmasthala Manjunateshwara College of Ayurveda and Hospital, Hassan, Karnataka, India.


<sup>3</sup> Ashwin Kumar S Bharathi, Professor, Department of Agada Tantra, Sri Dharmasthala Manjunateshwara College of Ayurveda and Hospital, Hassan, Karnataka, India.

<sup>4</sup> Soniya MP, Post Graduate Scholar, Department of Agada Tantra, Sri Dharmasthala Manjunateshwara College of Ayurveda and Hospital, Hassan, Karnataka, India.

<sup>5</sup> Niranjan RN, Post Graduate Scholar, Department of Agada Tantra, Sri Dharmasthala Manjunateshwara College of Ayurveda and Hospital, Hassan, Karnataka, India.

Vaipadika is one among eleven Kshudra Kushtas characterized by Pani Pada Sputana (cracking of palms and soles), Teevra Vedana (intense pain), Manda Kandu (mild itching) and Saraga Pidaka (reddish lesions). It is a Vatakapha predominant condition. Palmoplantar psoriasis effecting hand and foot shares similar clinical features as that of Vaipadika. It causes itching, pain, and rashes on the palms of the hands, sides of the fingers or on the soles of the feet. As Kushta is a Bahudoshaja Vyadhi, it requires Shodhana Chikitsa (purificatory therapies). But Kshudra Kushtas like Vaipadika respond well to OP based Shamana Chikitsa (pacification therapy). The current case report is an attempt to appreciate the effect of Shamana Chikitsa in the management of Vaipadika Kushta (Palmoplantar psoriasis). A sixty-three-year-old female patient approached the outpatient department with complaints of cracked left palm associated with itching, burning sensation and pain in the last one year. Though it is a chronic case, the patient was able to get relieved within four visits which created a promising faith towards Ayurvedic treatment.

**Keywords:** Ayurveda, Kshudra Kushta, Palmoplantar psoriasis, Vipadika

Corresponding Author	How to Cite this Article	To Browse
Akarsha Krishna S, Post Graduate Scholar, Department of Agada Tantra, Sri Dharmasthala Manjunateshwara College of Ayurveda and Hospital, Hassan, Karnataka, India. Email: <a href="mailto:drakarshakrishna@gmail.com">drakarshakrishna@gmail.com</a>	Nataraj HR, Akarsha Krishna S, Ashwin Kumar S Bharathi, Soniya MP, Niranjan RN, <a href="#">Ayurvedic management of Vaipadika - A Case Study</a> . J Ayu Int Med Sci. 2025;10(1):233-235. Available From <a href="https://jaims.in/jaims/article/view/3967">https://jaims.in/jaims/article/view/3967</a>	

Manuscript Received  
2024-12-10

Review Round 1  
2024-12-21

Review Round 2  
2024-12-31

Review Round 3  
2025-01-13

Accepted  
2025-01-26

Conflict of Interest  
None

Funding  
Nil

Ethical Approval  
Not required

Plagiarism X-checker  
12.54

Note



© 2025 by Nataraj HR, Akarsha Krishna S, Ashwin Kumar S Bharathi, Soniya MP, Niranjan RN and Published by Maharshi Charaka Ayurveda Organization. This is an Open Access article licensed under a Creative Commons Attribution 4.0 International License <https://creativecommons.org/licenses/by/4.0/> unported [CC BY 4.0].



## Introduction

Skin has always played a significant role in aesthetics. Healthy skin never fails to increase a person's confidence. However, because skin disorders are so evident, they not only diminish self-confidence but also lead to mental distress. *Vipadika* or *Vaipadika* is explained as one among Eleven *Kshudra Kushtas* which has the features of *Paani Paada Sputana* associated with *Teevra Vedana* as explained by *Acharya Charaka*.<sup>[1]</sup> Based on the features the major Dosh involved is *Vata* along with *Pitta* and *Kapha*.<sup>[2]</sup> *Acharya Sushruta* also explains it under *Kshudra Kushta* but with a different name called *Padadaari*.<sup>[3]</sup> Palmoplantar psoriasis is a condition that affects the palms and soles. It can manifest as pustular lesions, thick scaly plaques, or painful plaques.<sup>[4]</sup> Palmoplantar psoriasis accounts for around 3-4% of all psoriasis cases.<sup>[5]</sup> The present case has a one-year history. Based on the clinical symptoms, such as cracks and peeling of skin over her hands linked with itching, as well as the clinical results, the underlying dosha can be identified, and a specific course of treatment can be implemented, and her condition improved.

## Case Report

A 63 years old female patient visited skin opd of SDM college of *Ayurveda* Hassan with complaints of cracks and peeling of skin over left palm in last one year. Associated with extreme itching, which hampered her normal activities. She initially ignored problem, but when it worsened, she sought help from a nearby allopathic hospital. They suggested topical applications and drugs (details unknown), but symptoms persisted. There is no history of prolonged illness or associated symptoms. There is no surgical history, no previous record of such an incident.

### Clinical Findings

On the day of first visit the general examination of the person was of normal built without any pathological presentation. On local examination, there were cracks and peelings on palms associated with itching.

### Local Examinations

The patient has cracks and peeling of skin over palms associated with itching. There was no any discharge.

## Management

### First visit: 15/11/2023 - 29/11/2023

1. *Pancha Thiktha Gritha* 10gm early morning in empty stomach
2. *Gandhaka Malahara* ointment external application morning hours
3. *Patola Katurohinyadi Kashaya* 10ml twice daily before food with equal quantity of warm water
4. *Laghu Suthashekara Vati* two tablets twice daily before food
5. *Nalpamaradi Taila* external application at night
6. *Nimbadi Guggulu* one tablet twice daily after food

### Second visit: 29/11/2023 - 14/12/2023

1. *Pancha Thiktha Gritha* 10gm early morning in empty stomach
2. *Nalpamaradi Taila* external application at night
3. *Laghu Suthashekara Vati* two tablets twice daily before food
4. *Patola Katurohinyadi Kashaya* 10ml twice daily before food with equal quantity of warm water
5. Grab capsule one tablet twice daily after food
6. Atrisor ointment external application morning hours
7. *Dooshivishari Gulika* one tablet twice daily after food

### Third visit: 10/1/2024 - 25/2/2024

1. *Laghu Suthashekara Vati* two tablets twice daily before food
2. Atrisor ointment external application morning hours
3. *Shiva Gulika* one tablet in the morning before food
4. *Khadirarista* 10ml twice daily after food with equal quantity of warm water
5. Mark psora capsules one tablet twice daily after food

### Fourth visit: 14/2/2024 - 29/2/2024

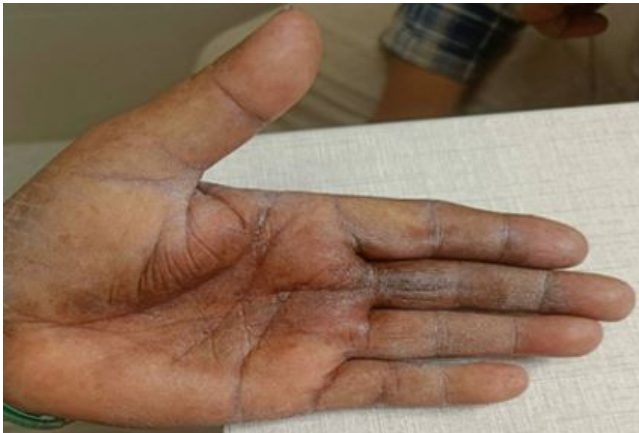1. *Laghu Suthashekara Vati* two tablets twice daily before food
2. *Shiva Gulika* one tablet in the morning before food
3. *Khadirarista* 10ml twice daily after food with equal quantity of warm water
4. Trichoderma ointment external application morning hours
5. *Nimbadi Guggulu* one tablet twice daily after food

## Observations and Results

On first visit patient had severe itching, peeling of skin and cracks over palms. Over subsequent visits itching, peeling and cracks reduced drastically.



**Figure 1: Before Treatment**



**Figure 2: After treatment**

## Discussion

*Shamana Chikitsa* is being opted in this case as a line of treatment. Considering the potent action of *Pancha Tiktha Gritha* for its *Tridosahara* and *Kanduhara* properties it has been opted for *Shamana Chikitsa*. *Patola Katurohinyadi Kashaya*, which is *Vishaghna*, *Kapha Pitta Shamaka* in nature. Local application of *Gandhaka Malahara* is highly effective in treating chronic cases of *Vaipadika*.<sup>[6]</sup> *Nalpamaradi Taila* local application acts as *Kustaghna*. *Nimbadi Guggulu*, which is *Kapha Vatahara*. *Laghu Suthashekara Vati* is *Pitta Shamaka* and helps in reducing *Kandu*. *Dooshivishari Gulika* which is a potent immune modulator, has *Vishaghna*, *Kustaghna*, properties. <sup>[7]</sup> *Khadirarista* which is a potent *Kustaghna*, which helps in reducing the symptoms of *Vaipadika*.

## Conclusion

The present case study concludes that *Vaipadika* has been effectively treated with *Shamanoushadhi* inspite of its chronicity and severity with Ayurveda medicines.

## References

1. Jadavji Trikamji, editor. Charaka Samhita of Agnivesha, Chikitsasthana; Kushtachikitsa Adhyaya. 1st ed. Varanasi, India: Chowkambha Prakashan; 2013. Chapter 7, Verse 21-26. p. 451 [Crossref] [PubMed][Google Scholar]
2. Jadavji Trikamji, editor. Charaka Samhita of Agnivesha, Chikitsasthana; Kushtachikitsa Adhyaya. 1st ed. Varanasi, India: Chowkambha Prakashan; 2013. Chapter 7, Verse 31-32. p. 451 [Crossref] [PubMed][Google Scholar]
3. Jadavji Trikamji, editor. Sushruta Samhita of Sushruta, Nidanasthana; Kshudraroga Nidana Adhyaya. 6th ed. Varanasi: Chowkambha Orientalia; 1997. Chapter 13, Verse 29. p. 321 [Crossref] [PubMed][Google Scholar]
4. Engin B, Aşkın Ö, Tüzün Y. Palmoplantar psoriasis. Clin Dermatol. 2017;35(1):19-27. [Crossref][PubMed][Google Scholar]
5. Engin B, Aşkın Ö, Tüzün Y. Palmoplantar psoriasis. Clin Dermatol. 2017;35(1):19-27. [Crossref][PubMed][Google Scholar]
6. Apaturkar NC, Deshpande A, Kothari N, Karare P. Effect of Gandhaka Malahara on Padadari: A Case Study. World J Pharm Med Res. 2018;4(10):148-151. [Crossref][PubMed][Google Scholar]
7. Deepa P, Nataraj HR, Anushree CG, Shirwar AK. A Critical Review on Dooshivishari Agada: A Herbo Mineral Formulation. Int J Ayurveda Pharma Res. 2022 Nov 13:70-77. [Crossref][PubMed][Google Scholar]

Disclaimer / Publisher's Note: The statements, opinions and data contained in all publications are solely those of the individual author(s) and contributor(s) and not of Journals and/or the editor(s). Journals and/or the editor(s) disclaim responsibility for any injury to people or property resulting from any ideas, methods, instructions or products referred to in the content.