



ISSN 2456-3110

Vol 3 · Issue 4

July-Aug 2018

Journal of  
**Ayurveda and Integrated  
Medical Sciences**

*www.jaims.in*

JAIMS



**Charaka**  
Publications

Indexed

# Effectiveness of Ayurvedic intervention in Primary Open Angle Glaucoma (*Kaphaja Adhimantha*) - A Case Study

Dr. Ratheesh P<sup>1</sup>, Dr. Abhayadev A<sup>2</sup>, Dr. Varsha Sumedhan<sup>3</sup>, Dr. Meghna P P<sup>4</sup>, Dr. Srinivasan M<sup>5</sup>,  
Dr. Sudhakar D<sup>6</sup>, Dr. Sunil kumar .S<sup>7</sup>, Dr. Kannadas C. S<sup>8</sup>

<sup>1,2,3,4</sup>Research Officer(Ayurveda),<sup>5</sup>Research Officer(Biochemistry),<sup>6</sup>Assistant Director (In-charge), Regional Ayurveda Research Institute for Life Style related Disorders, Poojappura, Trivandrum, Kerala, <sup>7</sup>Professor, <sup>8</sup>Professor & Head Department of Shalakyatantra, Govt. Ayurveda College Trivandrum, Kerala, INDIA.

## ABSTRACT

Glaucoma is a diverse group of disorders affecting the eye with a common characteristic potentially progressive optic neuropathy that is determined by both structural changes and functional deficit in which IOP is a key modifiable factor. In Primary Open Angle Glaucoma (POAG), IOP independent mechanisms of glaucomatous nerve damage and visual field loss with unobstructed angle of anterior chamber is observed. The patient has reported gradual diminution of peripheral aspect of visual field (Rt. eye - 6/12 and Lt. eye - 6/12 on Snellen's distant vision chart) in both eyes for 2 years. There was marked peripheral field defect on both confrontation test and perimetry visual field analysis test. The disease shows clinical similarity with *Kaphaja Adhimantha*, a disease affecting the whole eye mentioned in *Susruta Samhita* and *Ashtanga Hrudaya*. It is a chronic disease comes under life style related disorder. *Dukhena Roopam Pasyathi* (distorted image or constricted visual field), *Sirodukha* (headache), *Srava* (watering), *Kandu* (itching), *Pamsupoornatha* (foreign body sensation), *Aviladarsana* (diminished vision) and *Gourava* (heaviness of eye and head) are the clinical findings explained in the context of *Kaphaja Adhimantha*. These clinical findings mentioned in classical literature show resemblance with POAG. The meticulous deployment of *kaphaja Abhisyantha-Adhimantha* treatment protocol can be used to prevent the progression of ganglionic damage and preservation of eye sight. The logical interpretation on the basis of both subjective and objective clinical findings concluded the diagnosis as *Kaphaja Adhimantha* and treatment principle adopted was *Apatharpana*, *Kaphahara*, *Abhisyanthahara* and *Srothovisodhana*. After treatment his vision has improved as 6/6 in both eyes and remarkable change in visual field analysis. The study discusses about the effectiveness of Ayurvedic management in POAG.

**Key words:** *Kaphaja Adhimantha*, *Kaphaja Abhisyantha*, *Primary Open Angle Glaucoma*.

## INTRODUCTION

Glaucoma continues to be a major public health

### Address for correspondence:

**Dr. Ratheesh P.**

Research Officer(Ayurveda),  
Regional Ayurveda Research Institute for Life Style related  
Disorders, Poojappura, Trivandrum, Kerala, India.

E-mail: drprateesh524@gmail.com

Submission Date : 12/06/2018 Accepted Date: 05/08/2018

### Access this article online

Quick Response Code



Website: [www.jaims.in](http://www.jaims.in)

DOI: 10.21760/jaims.v3i4.13314

problem. It is the second leading cause of blindness worldwide after cataract. Glaucoma can be regarded as a group of diseases that have a common end-point as characteristic optic neuropathy which is determined by both structural change and functional deficit.<sup>[1]</sup> There are mainly two types of glaucoma, in which more common is Primary Open Angle Glaucoma (POAG), having an insidious onset, and Angle Closure Glaucoma (ACG), which is less common and tends to be more acute.<sup>[2]</sup> In glaucoma, the neuroretinal rim of the optic nerve becomes progressively thinner, thereby enlarging the optic-nerve cup. Its cause is the loss of retinal ganglion cell axons, along with supporting glia and vasculature. Retinal ganglion cell death in glaucoma occurs

predominantly through apoptosis (programmed cell death) rather than necrosis. It involves a cascade of events results in astrocyte and glial cell proliferation and alterations in the extracellular matrix of the lamina cribrosa, with subsequent optic nerve head remodelling. Multiple factors are likely to be involved, but the mechanisms remain relatively speculative.<sup>[3]</sup>

There are multiple proposed mechanisms of optic nerve head damage, some of which are IOP-dependent, and others are IOP-independent. The precise mechanism of increased resistance to aqueous outflow remains unclear and is currently an active focus of research.<sup>[4]</sup> The process of glaucomatous damage and the relationship with IOP and other potential influences is still poorly understood. One or both of the following mechanisms may be involved: Direct mechanical damage to retinal nerve fibres at the optic nerve head, perhaps as they pass through the lamina cribrosa; Ischaemic damage, possibly due to compression of blood vessels supplying the optic nerve head. Both mechanisms might lead to a reduction in axoplasmic flow, interference with the delivery of nutrients or removal of metabolic products, deprivation of neuronal growth factors, oxidative injury and the initiation of immune-mediated damage. Typically, patients are only symptomatic in later stage of disease, when they may become aware of constricted visual field or blurred vision. Patients with glaucoma typically lose peripheral vision and may lose all vision if not treated.

More frequently, patients are usually diagnosed as part of a routine eye test or as an incidental finding when presenting with another ophthalmic condition. POAG is mainly adult-onset disease affects about 1 in 100 of general population above the age of 40 years.<sup>[5]</sup> In the review of open-angle glaucoma, in which the iridocorneal angle is open (unobstructed) and normal in appearance but aqueous outflow is diminished. On the basis of the available data, there are approximately 11.2 million persons aged 40 years and older with glaucoma in India. Primary open angle glaucoma is estimated to affect 6.48 million persons. Most of those with disease are undetected and there exist major challenges in detecting and treating those

with disease.<sup>[6]</sup> Management of the disease focuses on lowering intraocular pressure (IOP) with current classes of drugs like prostaglandin analogues, beta-blockers, alpha-agonists and carbonic anhydrase inhibitors. New views have surfaced about other pathophysiological processes such as oxidative stress, vascular dysfunction and retinal cell apoptosis being involved in POAG progression and adjunctive treatments with drugs like memantine, bis(7)-tacrine, nimodipine, mirtogenol, (bis(7)-tacrine, nimodipine and vitamin E have been advocated.<sup>[7]</sup> These treatments have not helped all patients. Other treatment options include surgical correction or laser therapy to regulate aqueous flow in the anterior segment of eye.

The disease shows clinical similarity with *Kaphaja Adhimantha*, a disease affecting the whole eye mentioned in *Susruta Samhita* and *Ashtanga Hrudaya*. It is a chronic disease comes under life style related disorder. *Dukhena Roopam Pasyathi* (distorted image or constricted visual field), *Sirodukha* (headache), *Srava* (watering), *Kandu* (itching), *Pamsupoornatha* (foreign body sensation), *Aviladarsana* (diminished vision) and *Gourava* (heaviness of eye and head) are the clinical findings explained in the context of *Kaphaja Adhimantha*.<sup>[8]</sup> These clinical findings mentioned in classical literature show resemblance with POAG. The meticulous deployment of *Kaphaja Abhisyandha- Adhimantha* treatment protocol can be used to prevent the progression of ganglionic damage and preservation of eye sight.

## CASE REPORT

### Presenting complaints with duration

1. Gradual diminution of peripheral aspect of visual field in both eyes for 2 years
2. Heaviness of head and both eyes for 1 years
3. Watering from both eyes for 1year
4. Itching in both eyes for 1year
5. Foreign body sensation in both eyes for 1 year

**History of presenting complaints**

3 years back patient aged 63 year/male was diagnosed as having high intraocular pressure during routine medical check-up and he was advised to instil the eye drop Combigan one drop twice daily in each eyes. He had continued the medication for 8 months until he experienced giddiness and after that he has stopped the same without medical advice. For the last 2 years he observed gradual diminution of peripheral aspect of visual field in both eyes without any noticeable pain in eyes. For the last 1 year he has observed heaviness of head and both eyes and watering, itching and foreign body in both eyes. He made recurrent spectacle correction but there was no improvement noted in the vision. He approached Regional Ayurveda Research Institute for Life Style related Disorders, Trivandrum, Kerala for better management.

**History of past illness**

1. Type II Diabetes Mellitus (6yr)
2. Hypertension (6yrs)
3. Dyslipidaemia (6yrs)

**Medicine history**

1. Wosulin inj (28U-0-28U)
2. Tab. Glykind one tab once daily
3. Tab. Olmesartan one tab once daily
4. Tab. Atorvin one tab once daily

**General examination**

1. Pallor : Absent
2. Icterus : Absent
3. Cyanosis : Absent
4. Clubbing : Absent
5. Lymph nodes : Non palpable
6. Swelling over both foot : Absent

**Vital data**

1. BP : 120/80 mm of Hg
2. Pulse : 76/min
3. Resp. Rate : 20/min
4. Height : 156cm
5. Weight : 68kg

**Systemic Examination**

Central Nervous System, Respiratory System, Gastro-Intestinal Tract, Cardiovascular System, Integumentary system, locomotor system and Genito-urinary system: No abnormality noted

**Eye Examination**

1. **Head posture** : No signs of squint or ptosis.
2. **Forehead and facial symmetry**: No signs of facial palsy or ptosis, both eyebrows and eyelids are at the same level, Symmetrical nasolabial folds, Symmetrical angle of mouth in both sides
3. **Eye brows (Rt. & Lt)**: Cilia present, level of eye brows are normal, Curved with convexity upwards
4. **Eyelids (Rt. & Lt)**:
  - a. **Position**: Within normal limits, Upper eyelid covers 1/6 of cornea, Lower lid touches the lower border of cornea
  - b. **Movement**: No lagophthalmosis, no blepharospasm, no abnormal movements noted
  - c. **Margin**: No entropion, no ectropion, no scales present, no swelling noted
  - d. **Eye lashes**: No trichiasis, no poliosis.
  - e. **Skin**: No skin lesion noted.
  - f. **Aperture**: No ptosis, no lagophthalmosis
5. **Lacrimal apparatus (Rt.&Lt)**: No signs of epiphora, no signs hyperlacrimation, no signs of dacryocystitis, No signs of dacryoadenitis

**6. Eye ball (Rt.&Lt)**

- a. **Position:** No signs of exophthalmos, no signs of enophthalmos
- b. **Visual axis:** No squint
- c. **Size:** No abnormality noted
- d. **Movement:** No signs of extra-ocular muscle palsy, Uniocular and binocular movements are possible

**7. Conjunctiva (Rt.&Lt):**

**Bulbar and palpebral :** No congestion of vessels, no chemosis, no follicle, no pterygium

- 8. **Sclera (Rt.&Lt):** No discoloration and no inflammatory changes

**9. Cornea (Rt.&Lt):**

- a. **Size:** No signs of micro or megalocornea
- b. **Shape (curvature):** No signs of keratoglobus/keratoconus
- c. **Surface:** Smoothness is present
- d. **Sheen:** No signs of dry eye
- e. **Transparency:** Hazy [corneal oedema]
- f. **Vascularization:** Nil
- g. **Sensations:** No abnormality detected [ no fifth nerve involvement]
- h. **Endothelium, back of cornea (Rt.&Lt):** No deposits present

- 10. **Anterior chamber (Rt.&Lt):** No Foreign body, no aqueous flare.

(Shallow in both eyes - torch light method)

**11. Iris (Rt.&Lt):**

**Colour and pattern:** Crypts, ridges and collarette present, No cyst, No nodules

**12. Pupil (Rt. & Lt.)**

- a. **Number:** One in number
- b. **Size:** No mydriasis, No miosis
- c. **Shape:** Round

- d. **Location:** Centrally placed

- e. **Colour:** Greyish white [Immature senile cataract] in both eyes

**f. Reaction:**

- Direct Light Reflex : Sluggish reaction
- Consensual Light Reflex : Within normal limits
- Swinging Flash Light Test: No Relatively Apparent Pupillary Defect
- Near Reflex : Within normal limits

- 13. **Lens (Rt. & Lt.) :** Phakic eye with immature senile cataract

- a. **Position:** No dislocation, No subluxation

- b. **Shape:** Within normal limits

- c. **Colour:** Greyish white, no deposits on the anterior lens surface

**AYURVEDIC INTERVENTION PROVIDED**

**First step (Amapachana, Deepana and Vatanulomana)**

**A. Internal medicines****Amapachana:**

1. **Gandharvahasthadi Kashaya** 60 ml twice daily one hour before food for 7 days.
2. **Vaiswanara Choorna** 12 g. with hot water just before lunch for 7 days.

**B. External treatments**

1. **Thalam** (Application of medicine over vertex) for 7days by using *Ksheerabala Thaila* and *Rasnadhi Choorna* (two times daily)
2. **Mukhalepa** (application medicines over face) for 7days by using *Thriphaladhi Choorna* mixed with *Thriphaladhi Kashaya* (once daily)
3. **Nethraseka** (pouring medicated decoction over the eyes) for 7 days by using *Thriphaladhi Kashayam* (4.5min in each eye) (twice daily)
4. **Aschothana** (instilling of medicine in the eyes) for 7 days by using *Pasupatha Gulika* and rose water (7 drops in each eye) (twice daily)

**Second step**

1. **Internal treatment** - *Avapidaka Snehapana* with *Thiktaka Ghruta* for seven days
2. **External treatment** - *Ushnambu Snanam*(bath in warm water) for 2 days
3. **Jalaukavacharana** (blood letting by medicinal leech) - Both forehead and palpebral conjunctiva of upper and lower eyelid of each eye (one sitting in each side)
4. **Virechanam** with *Gandharvahasthadhi Eranda Taila* - 25ml with hot milk at morning empty stomach after getting proper appetite.

**Third step****1. Internal medicines**

- a. *Pathyasadangam Kashaya* 60 ml twice daily one hour before food daily
- b. *Chandraprabha Vatika* 1 tab two times before food with *Kashaya* daily
- c. *Gandharvahasthadhi Eranda Taila*- 10 drops with 50 ml hot milk at 4pm daily

**2. External treatments**

- a. **Nasya** (transnasal drug administration) for 7days by using *Anuthaila* 8 *Bindu* in each nostrils; **Thalam** (Application of medicine over vertex); along with *Nasya* by using *Ksheerabala Taila* and *Rasnadhi Choorna*; **Urdwabhaga-abhyangam** and **Mrudusweda**: external application of medicated oil over upper part of body as a part of pre-operative to *Nasya* by using *Ksheerabala Taila* followed by mild sudation of upper part of body after proper eye covering with lotus petals.
- b. **Anjana (collyrium)** for 7 days by using *Elaneer Kuzhambu* once daily followed by *Kshalana* (wash the eye) with *Triphala Kashaya* after the irritation of eyes getting subsided (once daily).
- c. **Siropichu** (Keeping medicated oil on the head for prescribed time) for seven days using *Ksheerabala Taila*.

**Fourth step**

1. **Tarpana** for 5 days: Medicated ghee is kept in the eyes for a prescribed time. The procedure helps to stabilize the layers of eye. The prescribed drug is *Thikthaka Ghrutha*.
2. **Putapaka** for 1 day: Specially prepared juice of herbal combination is kept in eyes for a prescribed time. This procedure helps to overcome the weakness of eyes due to the other *Netra Kriya Kramas* (eye treatments). *Jeevaniya Choorna* purchased as per quality assured standards and goat's liver grinded with ghee and milk and make into a round mass. This mass is covered by *Eranda (Recinus communis)* leaves which is covered by mud. This is dried and subjected to heat till it reaches red hot. Break the mass after getting cooled, remove mud and leaves and the mass is squeezed and filtered. This juice is used for the purpose of *Putakaka*.<sup>[9]</sup>

**Follow up (2 weeks)**

1. *Pathyasadangam Kashaya* 60 ml twice daily one hour before food daily
2. *Chandraprabha Vatika* 1 tab two times before food with *Kashaya* daily
3. *Gandharvahasthadhi Eranda Taila* - 10 drops with 50 ml hot milk at 4pm daily
4. *Anu Tailam* 2 *Bindu* in each nostril once daily - evening

**RESULTS**

We have observed the patient has showed improvement in following aspects;

1. Objective findings
  - a. Vision improved as 6/6 in both eyes without glass as per Snellen's distant vision chart (Table 3, 4, 5, 6, 7)
  - b. Intraocular pressure reduced (Table 8)
  - c. Visual field improved (Fig. 1, 2, 3, 4)

## 2. Subjective findings

- Gradual diminution of peripheral aspect of visual field in both eyes has improved.
- No heaviness of head and both eyes
- No watering from both eyes
- No itching in both eyes
- No foreign body sensation in both eyes

**Table 1: Blood parameters checked during Admission**

Blood test	08/06/2018
Haemoglobin (gm%) (11-16)	15.8
Total WBC count	7000
Polymorph(%) (50-70)	54
Lymphocytes (%) (20-40)	36
Eosinophil (%) (1-6)	10
ESR (mm/hr) (5-10)	5
FBS (mg/dl) (70-105)	125
PPBS (mg/dl) (80-110)	243
Blood urea (mg/dl) (10-55)	21
Serum creatinine (mg/dl) (0.7-1.4)	0.8
Serum uric acid (mg/dl) (3.2-7)	3.5
Serum calcium (mg/dl) (8.8-10.2)	8.1
Serum Cholesterol (mg/dl) (150-220)	206
HDL (mg/dl) (35-55)	50
LDL (mg/dl) (above 150)	143
Serum Triglycerides (mg/dl) (65-165)	65

**Table 2: Fundus examination - 07/06/2018**

Fundus findings	Rt. Eye	Lt. Eye
<b>Fundal glow</b>	Positive	Positive
<b>Media</b>	clear	clear
<b>Optic disc</b>	Round with CDR = 0.7 (deep cup), peripapillary atrophic changes around the disc, Thin neuro-retinal rim.	Round with CDR = 0.7 (deep cup), Peripapillary atrophic changes around the disc, Thin neuro-retinal rim.
<b>Macula</b>	FR - Present	FR - Present
<b>Blood vessels</b>	Attenuated arterioles, crossing over changes, micro aneurysms in the macular area, dilated veins	Attenuated arterioles, crossing over changes, micro aneurysms in the macular area, dilated veins.
<b>General background</b>	Mild tessellations	Mild tessellations
<b>Diagnosis</b>	Mild NPDR and Hypertensive Retinopathic changes with Glaucomatous fundus changes	Mild NPDR and Hypertensive Retinopathic changes with Glaucomatous fundus changes

**CHANGE IN OBJECTIVE PARAMETERS NOTED****Changes in visual acuity****Table 3: Vision test - 07/06/2018**

Visual acuity	Right eye	Left eye
Without glass	6/12	6/12
With glass	No improvement with glass	No improvement with glass
Near vision	N-36	N-36

**Table 4: Vision test - 19/06/2018**

Visual acuity	Right eye	Left eye
Without glass	6/9	6/9
With glass	6/6	6/6
Near vision	N-36	N-36

**Table 5: Vision test - 25/06/2018**

Visual acuity	Right eye	Left eye
Without glass	6/6 - partial	6/6
With glass	6/6	6/6
Near vision	N-18	N-18

**Table 6: Vision test - 02/07/2018**

Visual acuity	Right eye	Left eye
Without glass	6/6	6/6
Near vision	N-18	N-18

**Table 7: Vision test - 30/07/2018 (after inpatient treatment)**

Visual acuity	Right eye	Left eye
Without glass	6/6	6/6
Near vision	(+3.00)N-6	(+3.00)N-6

**Table 8: Changes in Intraocular pressure**

**Intraocular pressure (IOP) by Schiottz Tonometer**

IO P	07/06/2018	19/06/2018	25/06/2018	02/07/2018	30/07/2018
Rt. Eye	22.4 mm of Hg(5.5 gmwt) at 10	17.3 mm of Hg(5.5 gmwt) at 10	17.3 mm of Hg(5.5 gmwt) at 10	17.3 mm of Hg(5.5 gmwt) at 10	17.3 mm of Hg(5.5 gmwt) at 10

	am	am	am	am	am
Lt. Eye	22.4 mm of Hg(5.5 gmwt) at 10 am	17.3 mm of Hg(5.5 gmwt) at 10 am	17.3 mm of Hg(5.5 gmwt) at 10 am	17.3 mm of Hg(5.5 gmwt) at 10 am	17.3 mm of Hg(5.5 gmwt) at 10 am

**Table 9: Changes in visual field (confrontation test)**

Date	Eye	Visual field
07/06/2018	Right Left	Patient cannot see the object keeping a distance one metre with extreme angle in different directions.
30/07/2018	Right Left	Patient can see the object keeping at a distance of one metre with maximum angle in different directions.

**1. Changes in Visual field analysis (Perimetry - Central 24 - 2 Threshold test)**

**Fig. 1: Field Analysis - 29/05/2018 - Rt. eye (before treatment)**

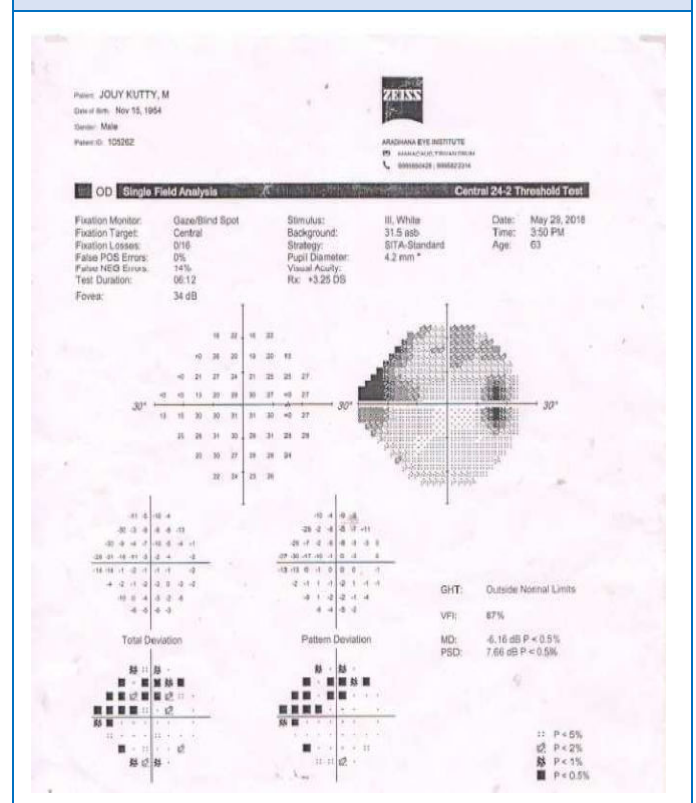




Fig. 2: Field Analysis - 29/05/2018 - Lt. eye (before treatment)




Fig. 3: Field Analysis - 25/07/2018 - Rt. eye (After treatment)

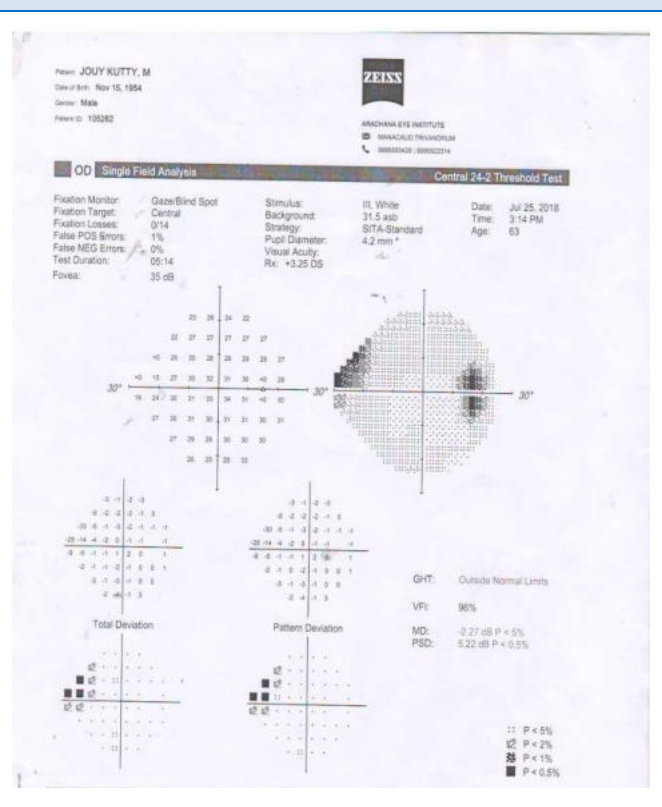



Fig. 4: Field Analysis - 25/07/2018 - Lt. eye (After treatment)



DISCUSSION

Glaucoma can be regarded as a group of diseases that have a common end-point as characteristic optic neuropathy which is determined by both structural change and functional deficit. POAG is a commonly bilateral disease of adult onset. POAG also known as chronic simple glaucoma of adult onset, is typically characterized by slowly progressive raised intraocular pressure associated with open normal appearing anterior chamber, optic disc cupping and visual field defects. Here the primary clinical assessment was carried out with subjective clinical findings, intraocular pressure measurement, direct ophthalmoscopic examination (Table 2) and confrontation test. Further the patient was advised to undergo perimetry field analysis (Fig. 1, 2) also. The subjective clinical findings such as *Dukhena Roopam Pasyathi* (distorted image or constricted visual field), *Srava* (watering), *Kandu* (itching), *Pamsupoornatha* (foreign body sensation) and *Gourava* (heaviness of eye and head) were reported by the patient. These

clinical findings mentioned in Ayurvedic classical literature show resemblance with POAG. The treatment protocol mentioned in *Kaphaja-Adhimantha* can be used to prevent the progression of ganglionic damage and preservation of eye sight. *Rookshana*, *Kaphaharatwa*, *Chakshusya*, *Vatanulomana* and *Abhishyandhahara* are the main concept adopted to tackle the pathological condition associated with POAG. *Kaphapittaharatva* along with *Vatanulomana* is the ideal method employed to control the progression of the disease.<sup>[10]</sup>

In the first step *Amapachana* and *Deepana* type of medicines prescribed for internal administration. External treatment provided in the first step is to regulate the microcirculation nearer to eyes. Second step of treatment started when the patient reached to the metabolic stage of reduced *Kapha Dosha* and increased *Vatapitta Dosha* stage that means patient shows the indication of good appetite and good bowel clearance. Second step is mean for cellular level repair by internal medicated ghee therapy. In the end of second step *Jalaukavacharana* (medicinal leech therapy) for improving the arterial supply and reducing the stagnated blood in the venous system near the eyes. *Virechana* therapy (therapeutic purgation) is planned to cleanse the elementary system of the body. Third step of treatment involves trans-nasal drug administration, collyrium and keeping medicated oil over the head to nourish the deeper layer structures of visual apparatus. Fourth step of treatment includes *Tarpana* (keeping medicated ghee in the eye for a prescribed time) and *Putapaka* (keeping specially prepared medicated juice in the eye for a prescribed time) is arranged to strengthen the eyeball and adnexa.

During treatment period visual acuity (Table 3, 4, 5, 6, 7) and IOP (Table 8) were monitored and observed that both the parameters were improved. The perimetry visual field analysis (Fig. 3, 4), IOP, visual acuity (Snellen vision chart), Confrontation analysis (Table 9) and subjective clinical findings after follow up was observed meticulously. The final assessment stated that the Ayurvedic intervention is effective in managing POAG.

## CONCLUSION

The great majority of patients with POAG will not become blind in their lifetime, but the incidence of blindness varies considerably depending on multiple factors such as the presence of advanced damage at diagnosis, non-compliance with treatment. The main properties of drugs selected for the treatment are *Rooksha*, *Laghu* which is *Srotovisodhana* and reduce *Kapha Dosha*. The prescribed management executed meticulously considering the subjective and objective parameters. The result of the treatment protocol ensures the credibility of traditional Ayurvedic clinical management. The prognosis may have been significantly improved with newer treatment strategies. Here an attempt made to improve the prognosis of POAG with classical Ayurvedic treatment. It is observed that the Ayurvedic management is effective in controlling both structural as well as functional deficit associated with primary open angle glaucoma.

## ACKNOWLEDGEMENT

The authors gratefully acknowledge the Director General, CCRAS, Ministry of AYUSH, Govt of India, New Delhi, India for providing all the necessary facilities to carry out the case study

## REFERENCES

1. Facts about Glaucoma search by [www.who.int/blindness/causes/priority/en/index6.html](http://www.who.int/blindness/causes/priority/en/index6.html)
2. Kanski JJ, Clinical Ophthalmology, Elsevier publication; 8<sup>th</sup> edition, 2016; p.307
3. Kuehn MH, Fingert JH, Kwon YH. Retinal ganglion cell death in glaucoma: mechanisms and neuroprotective strategies. *Ophthalmol Clin North Am* 2005; 18 (3): 383–95
4. Johnson M. What controls aqueous humour outflow resistance? *Exp Eye Res.* 2006;82(4):545–57.[PMC free article] [PubMed]
5. Khurana A.K, Comprehensive Ophthalmology, 6<sup>th</sup> edition, New Delhi: New Age International, 2017; p.229

6. George R, Ve RS, Vijaya L. Glaucoma in India: Estimated burden of disease. J Glaucoma. 2010; 19:391–7. [PubMed]
7. Beidoe G, Mousa SA. Current primary open-angle glaucoma treatments and future directions. Clin Ophthalmol. 2012; 6:1699–1707. [PMC free article] [PubMed]
8. Susrutha with the Nibabdhasangraha commentary of Sri Dalhanacharya. Uttaratantra 6th chapter 16-17 sloka. Vaidya Jadavji Trikamji Acharya (ed). *Susrutha Samhitha*, re-print edition ed. Varanasi: Krishnadas Academy; 2015. pp. 603.
9. Vagbhata. Sutrasthana 24th chapter-16th sloka. Bhisagacharya Harisastri Paradakara Vaidya (ed). *Ashtanga Hridayam* with commentaries of (Sarvangasundara) of Arunadutta and (Ayurveda Rasayana) of Hemadri, Reprint tenth edition ed. Varanasi: Chaukhambha orientalia; 2011. pp. 309.
10. Susrutha with the Nibabdha Sangraha commentary of Sri Dalhanacharya. Uttaratantra 11th chapter 1-4 sloka. Vaidya Jadavji Trikamji Acharya (ed). *Susrutha Samhitha*, re-print edition ed. Varanasi: Krishnadas Academy; 2015. pp. 615

**How to cite this article:** Dr. Ratheesh P, Dr. Abhayadev A, Dr. Varsha Sumedhan, Dr. Meghna P P, Dr. Srinivasan M, Dr. Sudhakar D, Dr. Sunil kumar .S, Dr. Kannadas C. S. Effectiveness of Ayurvedic intervention in Primary Open Angle Glaucoma (Kaphaja Adhimantha) - A Case Study. J Ayurveda Integr Med Sci 2018;4:210-219.  
<http://dx.doi.org/10.21760/jaims.v3i4.13314>

**Source of Support:** Nil, **Conflict of Interest:** None declared.

\*\*\*\*\*