



ISSN 2456-3110

Vol 3 · Issue 5

Sep-Oct 2018

Journal of
**Ayurveda and Integrated
Medical Sciences**

www.jaims.in

JAIMS



Charaka
Publications

Indexed

Ayurvedic management of Corneal Foreign Body - A Case Report

Dr. Apoorva MN,¹ Dr. Hamsaveni V.²

¹Post Graduate Scholar, ²Professor, Department of Post Graduate Studies in Shalaky Tantra, Shri Kalabyraveshwara Swamy Ayurvedic Medical College, Hospital and Research Centre, Bengaluru, Karnataka, INDIA.

ABSTRACT

Foreign bodies represent a common cause of eye related complaints for adult and paediatric patients presenting to primary care physicians and ophthalmologists. Corneal foreign body is defined as any microscopic or macroscopic material from the external environment which may lodge in the cornea - the anterior transparent part of the eye that overlies the anterior chamber. Patient of corneal foreign body is frequently self-evident by history that is foreign body sensation, pain, photophobia and lacrimation. Decreased vision may also be reported in few patients. The *Lakshanas* explained under *Sashalya Netra* in Ayurveda can be correlated with the Corneal foreign body. Here is a case report of Corneal foreign body which was successfully treated with Ayurvedic treatment principles with *Mahatriphaladi Ghrita Aschyotana* and *Yashtimadhu Ksheera Paka Seka* for 6 days after its removal. There was a complete relief in Signs and Symptoms after the treatment. Hence the treatment protocol can be adopted in cases of corneal foreign body.

Key words: Corneal Foreign Body, *Sashalya Netra*, *Mahatriphaladi Ghrita*, *Aschyotana*, *Yashtimadhu Ksheera Paka, Seka*.

INTRODUCTION

A corneal foreign body is an object either superficially adherent to or embedded in the cornea which has to be treated as an emergency as cornea is an important structure of optical media, damage of which may cause vision loss.^[1] A successful patient outcome in the setting of such emergencies depends on correct diagnosis, treatment and disposition of patients including pain management and referral. The symptoms of corneal foreign body include severe

pain, ciliary and conjunctival congestion, lacrimation, photophobia, reflex blepharospasm and defective vision.^[2] In later cases if the condition is ignored it may lead to complications and may even cause vision loss. *Sashalya Netra Lakshanas* explained in *Nayanabhighata Pratishedha Adhayaya* can be correlated with the signs and symptoms of corneal foreign body that is,

स्रवत्यश्रुचयन्नेत्रं वृत्तं लोहितराजिभिः निमेषोन्मेषणाशक्तिंसशै
ल्यंतं विनिर्दिशेत् ।^[3] Thus, here an attempt is made to understand the corneal foreign body through Ayurveda.

OBJECTIVES

1. To manage the corneal foreign body through Ayurvedic treatment modalities.
2. Understanding of Corneal foreign body with respect to *Nayanabhighata* mentioned in classics.

MATERIALS AND METHODS

A 28 years old male Patient electrician by occupation came to Shalaky Tantra OPD of SKAMCH & RC

Address for correspondence:

Dr. Apoorva MN

Post Graduate Scholar, Department of PG Studies in Shalaky Tantra, Shri Kalabyraveshwara Swamy Ayurvedic Medical College, Hospital and Research Centre, Bengaluru, Karnataka, India.

E-mail: apoorvamn86@gmail.com

Submission Date : 20/08/2018

Accepted Date: 27/09/2018

Access this article online

Quick Response Code



Website: www.jaims.in

DOI: [10.21760/jaims.v3i5.13844](https://doi.org/10.21760/jaims.v3i5.13844)

Bengaluru on 27/12/2017 with a complain of foreign body sensation, redness and watering from the left eye from past 3 days. On taking history he revealed that on 25/12/2018 evening while doing machine work he felt as if a particle of metal entered his left eye, soon he rubbed the eye for few seconds and ignored though there was discomfort and continued his work. On 26/12/2018 morning he experienced mild pain in the left eye and also developed redness by afternoon and he did not consult any physician, on same day evening he developed watering from the left eye with severe pain, redness and there was mild blurring of vision. On 27/12/2018 he was not able to open his left eye as there was a severe pain, redness, watering, blurriness and noticed particle in the left eye and came to SKAMCH& RC for treatment.

On examination through Slit Lamp Bio-microscopy

OBSERVATION

| Date | Treatment Given | Observation |
|--------------------------|---|--|
| 27/12/2017 | Foreign body was removed under topical anaesthesia with xylocaine 2%. <i>Aschyotana</i> with <i>Mahatriphaladi Ghrita</i> for every 2hrs | Foreign body sensation, Pain and discomfort was reduced. |
| 28/12/2017 to 01/01/2018 | <i>Seka</i> with <i>Yashtimadhu Ksheerapaka</i> and <i>Aschyotana</i> with <i>Mahatriphaladi Ghrita</i> every 2 nd hourly. | Redness, Watering and Blurriness of vision got reduced |

Fig. 1: Before removal of foreign body

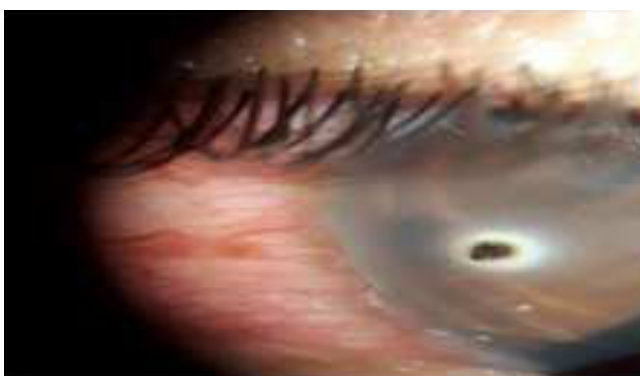

Fig. 2: After removal of foreign body

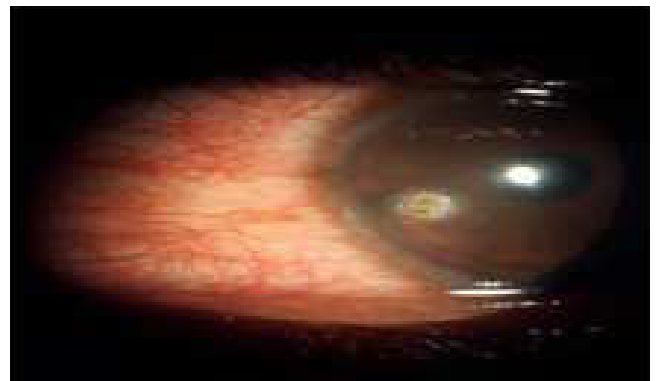
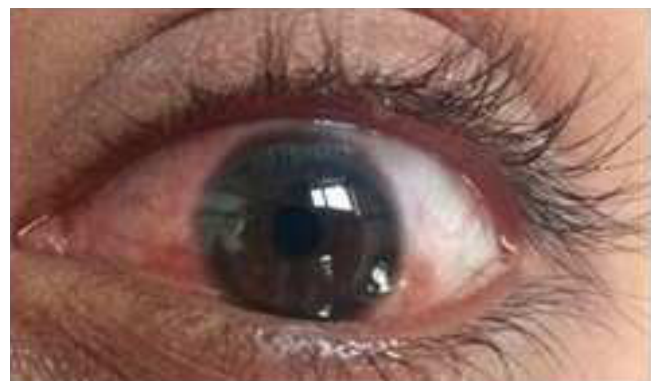

Fig. 3: After 5 days of treatment



RESULTS

| | Before Treatment | After Treatment |
|-----------------|-----------------------------|-----------------|
| Symptoms | Foreign body sensation +++ | Absent |
| | Redness +++ | Absent |
| | Watering of eyes ++ | Absent |
| Signs | Conjunctival congestion +++ | Reduced |

DISCUSSION

Eyes are considered as an important sense organ in our body utmost care should be taken in managing any injury, in present study the foreign body was removed under aseptic measures followed by *Mahatriphaladi Ghrita Aschyotana* and *Yashtimadhu Ksheerapaka Seka*. The probable mode of action of these drugs is discussed below.

Mahatriphaladi Ghrita Aschyotana

Aschyotana is indicated in *Purva Rupavastha* of *Netra Roga* where *Toda, Kandu, Gharsha, Daha, Raga, Paka* and *Sopha* will be present.^[4] In this case patient had severe pain, redness, foreign body sensation along with watery discharge from the eye. So *Mahatriphaladi Ghrita Aschyotana* was done every two hourly after removing the foreign body and was asked to close the eyes. It acts as best *Vrunaropaka* caused by *Shastraghata*. *Ghrita* is said to be best *Yogavahi, Vatapitta Shamaka* and *Rasayana*, hence it is the best choice of drugs in the *Netra Rogas*.^[5] Most of the ingredients of *Mahatriphaladi Ghrita* are having *Madhura Rasa, Sheeta Veerya* and *Vatapitta Shamaka* and acts as *Vruna Ropana*.^[6] *Ghrita* having lipophilic property easily facilitates transportation of active principles of medicine to a target cells as cell membrane also contains lipid.^[7] Thus, it has helped in relieving the symptoms.

Seka with Yashtimadhu Ksheerapaka

Yashtimadhu Ksheerapaka Seka was done for 6 days. *Yashtimadhu* alleviates *Vata* and *Pitta Dosha*.^[8] It is *Vedanasthapana, Shothahara. Madura Rasa* and *Sheeta Veerya* thus gives soothing effect on the wound, while describing the *Karma* of *Madura Rasa, Acharyas* have clearly mentioned the word *Vranagna, Dathu Vardana*.^[9] Chemically *Yashtimadhu* is composed of saponins, alkaloids, flavonoid, hydro-methanolic which acts as anti-bacterial.^[10] *Ksheera* having *Madhura Rasa, Sheeta Veerya* also alleviates *Vata, Pitta* and *Rakta Doshas*, it is *Vedanasthapaka* and *Chakshushya*.^[11] Chemically lactoferrin, lactoperoxidase present in *Ksheera* acts as anti-microbial thus helps in relieving the symptoms and promotes wound healing.

CONCLUSION

Eye being a delicate organ even small trauma may have devastating effects, hence physician should implement required treatment as early as possible. From *Acharya Sushruta's* description on *Nayanabhighata Pratishedha* it is evident that ocular injuries were quite common during olden days and is

common even today. *Chikitsa* explained for *Abhighataja Vruna* of various parts of the body can also be employed for *Netra* and its *Avayava*. Here *Mahatriphaladi Ghrita Aschyotana* and *Yashtimadhu Ksheerapaka Seka* adopted after removal of the foreign body have helped in minimizing the signs and symptoms with the help of their *Vruna Ropaka, Chakshushya, Vedana Sthapana* etc. Property, also *Madhura Rasa* and *Sheeta Veerya* of most of the drugs have promoted wound healing. *Acharya Charaka's quote* on importance of *Netra* describes, if an individual is endowed with all other sensory faculties, strength, beautiful appearance etc. but without eye sight he will be as useless as an insect.^[12] Hence, Eyes should be protected as it helps an individual to perceive the nature through vision. And vision is a primary factor which helps us to connect with the surrounding and keeps us safe.

REFERENCES

1. Anonymous <https://emedicine.medscape.com/article/82717-overview>.
2. A K Khurana, Comprehensive Ophthalmology, edition 2015, 6th edition, Jaypee Brothers Medical Publishers.
3. Hariharaprasad Tripathi, Vangasena, Nertarogadhikara, Chapter 36th, Chaukamba Samskrita Samsthana, Varanasi.
4. Acharya Vagbhata, Ashtanga Hrudaya, edited by Bhisagacharya Harishastri Paradakara Vaidya, Sutra Sthana, Aschyotanaanjanavidhi Adhayayaedition, Chapter 23rd, edition 2014, Chaukamba Orientalia, Varanasi.
5. Acharya Vagbhata, L C Vaidya, Ashtanga Hrudaya, Sutra sthana, 5/73, 2nd edition.
6. Dr. Rajesh L Gadhiya, "Pharmacological and Pharmaceutical Analysis of Mahatriphaladi Ghrita – A Polyherbal Ayurvedic Formulation. European Journal of Pharmaceutical and Medical Research, 2017, 4(2), 765-768. www.ejpmr.com.
7. Swapna Kumary, Mrutyunjaya Panda, Kamdev Das, "Yashtimadhu Ghrita in Sadyovruna- A Review, Anweshana Ayurvedic Journal, 2015, Issue 4, Volume 1, ISSN: 2395-4159, www.aamj.in.

8. Swapna Kumary, Mrutyunjaya Panda, Kamdev Das, "Yashtimadhu Ghrita in Sadyovruna- "Yashtimadhu Ghrita in Sadyovruna- A Review, Anweshana Ayurvedic Journal, 2015, Issue 4, Volume 1, ISSN: 2395-4159, www.aamj.in.
9. Swapna Kumary, Mrutyunjaya Panda, Kamdev Das "Yashtimadhu Ghrita in Sadyovruna- "Yashtimadhu Ghrita in Sadyovruna- A Review, Anweshana Ayurvedic Journal, 2015, Issue 4, Volume 1, ISSN: 2395-4159, www.aamj.in.
10. Swapna Kumary, Mrutyunjaya Panda, Kamdev Das "Yashtimadhu Ghrita in Sadyovruna "Yashtimadhu Ghrita in Sadyovruna- A Review, Anweshana Ayurvedic Journal, 2015, Issue 4, Volume 1, ISSN: 2395-4159, www.aamj.in.

11. Sri Bhavamishra, edited by Pandit Sri Bramha Sankara Mishra, Bhavaprakasha, Volume 1, Ksheera Varga, Reprint 2015, Chaukambha Sanskrit Bhavan, and Varanasi.
12. Agnivesha, Charaka Samhita, edited by Vaidya Jadavji Trikamji Acharya, Sutra Sthana, Indriyopakramaniya Adhayaya, Chapter 8th, Re-print 2015, Chaukamba Orientalia, Varanasi.

How to cite this article: Dr. Apoorva MN, Dr. Hamsaveni V. Ayurvedic management of Corneal Foreign Body - A Case Report. J Ayurveda Integr Med Sci 2018;5:201-204.

<http://dx.doi.org/10.21760/jajims.v3i5.13844>

Source of Support: Nil, **Conflict of Interest:** None declared.
