



ISSN 2456-3110

Vol 4 · Issue 1

Jan-Feb 2019

Journal of
**Ayurveda and Integrated
Medical Sciences**

www.jaims.in

JAIMS



Charaka
Publications

Indexed

A Single Case Study of Diabetic Foot Ulcer treated with *Vrana Dhoopana* and *Kshara Picchu*

Dr. Shruthi P,¹ Dr. Shailaja SV²

¹Post Graduate Scholar, ²Professor & HOD, Department of Shalya Tantra, Sri Kalabyraveswara Swamy Ayurvedic Medical College, Hospital & Research Centre, Bangalore, INDIA.

ABSTRACT

In present scenario due to the sedentary lifestyle, diabetes mellitus has become common disease. Diabetic foot ulcer is a complication of diabetes mellitus which is the leading cause of lower limb amputations. It occurs in 15% of all patient with diabetes mellitus and precedes 84% of patients with diabetic foot ulcer which needs lower leg amputation. The management of diabetic foot ulcer requires blood sugar control, debridement, advanced dressing and offloading modalities. In Ayurvedic literature, *Acharya Sushruta* has described sixty treatment modalities, He has given more importance to *Vranashodhana* and *Ropana*. *Acharya Vagbhatta* has explained that *Vranas* which are caused by *Madhumeha* can be treated with *Aragwadhigana Dravyas*, hence in the present study for *Vrana Shodhanartha Prakshalana* with *Aragwadhadi Qwatha* and *Vrana Dhoopana* by *Guggulu, Nimba Choorna, Haridra, Jatyadi Ghrita* were selected and for *Vrana Ropanartha Jatyadi Taila* was selected.

Key words: Diabetic foot ulcer, *Vrana Shodhana*, *Vrana Ropana*.

INTRODUCTION

In present days the complications of diabetes mellitus like diabetic foot ulcer is often quite dreaded disability cause of lower extremity amputation. It occurs in 15% of all patient with diabetes mellitus and precedes 84% of patients with diabetic foot ulcer which needs lower leg amputation. Three factors play to produce diabetic ulcer are diabetic neuropathy, diabetic atherosclerosis causing ischaemia and Glucose laden tissue is quite vulnerable for infection and thus ulcer is formed.^[1] The pathogenesis of foot ulcer is complex. Common

sites are Foot - plantar aspect, leg, upper limb, back, scrotum, perineum.^[2] The management of Diabetic foot ulcer requires diabetes should be controlled, Antibiotics, Excision of the ulcer, debridement and skin grafting once healthy granulation tissue is formed.^[3] Diabetic ulcers might end up in amputation of the limb, if not treated properly. Majority of these amputations are preceded by non-healing ulcers. Only two-thirds of ulcers eventually heal. Hyperbaric oxygen therapy, electrical stimulation can be used as adjacent therapies for rapid healing of Diabetic foot ulcer.

In Ayurvedic literature, *Acharya Sushruta* has described sixty treatment modalities for *Vranas*,^[4] for any *Vrana* foremost management is *Vrana Shodhana* and *Ropana*. *Acharya Vagbhata* has explained that *Vranas* which are caused by *Madhumeha* can be treated with *Aragwadhigana Dravyas*.^[5] *Acharya Susrutha* says *Doopana* is useful for the *Vranas* which are having *Srava* and *Vedana*.^[6] Hence in the present study for *Vrana Shodhanartha Prakshalana* with *Aragwadhadi Qwatha* and *Vrana Dhoopana* by *Guggulu, Nimba Choorna*,^[7] *Haridra, Jatyadi Ghrita* were selected and for *Vrana Ropanartha Jatyadi Taila*^[8] was selected.

Address for correspondence:

Dr. Shruthi P.

Post Graduate Scholar, Department of Shalya Tantra, Sri Kalabyraveswara Swamy Ayurvedic Medical College, Hospital & Research Centre, Bangalore, INDIA.

E-mail: drshruthipgowda77@gmail.com

Submission Date: 13/01/2019

Accepted Date: 22/02/2019

Access this article online

Quick Response Code



Website: www.jaims.in

DOI: 10.21760/jaims.4.1.22

CASE REPORT

A 61years female patient visited the Shalya Tantra OPD of SKAMCH & RC with the complaints of Non-healing ulcer over medial side of plantar aspect of right foot and pain over right foot since 2½ months.

H/O present illness

Patient was said to be apparently healthy 2½ months before, she noticed a wound in the medial side of plantar aspect of right foot which occurred spontaneously after a swelling. The wound was painful, pain was pricking in nature, increases on long standing and walking for long hours and relieves after taking analgesics.

Occasionally tingling sensation and numbness over right foot was present. For these complaints she visited diabetes center and foot clinic. Where they advised investigations and advised to continue the insulin therapy along with antibiotics for 5 days and wound dressing on alternative days. The wound was not healed even after 2 months of treatment. So, for further management she came to Shalya Tantra OPD of SKAMCH & RC.

Purva Vyadhi Vruttanta

- Patient is a known case of Type 2 Diabetes mellitus for 10 years.
- P/H/O wound caused due to burn on the medial side of plantar aspect of right foot on 4/11/2016.
- P/H/O wound caused due to trauma on plantar aspect of right great toe on 9/5/2017.
- P/H/O blister over dorsal aspect of 5th digit of the right foot on 1/6/2017.

Family history: All other family members are said to be healthy

Vayaktika Vruttanta

- Diet - Mixed
- Appetite - Moderate
- Sleep - Good, 7-8 hours/night, 2-3 hours in the afternoon
- Micturition - 5-6 times/ day; 3-4 times/night

- Bowel - Regular, once /day, constipated sometimes
- Habits - Tea - 2 cups/day

Rogi Pareeksha**General Examination**

- Tongue - Uncoated
- Pulse - 72 beats/ min
- BP - 130/90 mm of Hg
- Temperature - 98.6°F
- Respiratory rate - 18 cycles/min
- Height - 157 cm
- Weight - 64 kgs
- BMI - 26

Systemic Examination

Cardio Vascular System Examination: S1, S2 heard, no added murmurs.

Respiratory System Examination: NVBS heard.

Per Abdomen Examination: Soft, Nontender, No Organomegaly.

Central Nervous System Examination: Conscious, Orientation to time, place, person - Intact

Vrana Pareeksha**Darshana**

- Vaya : Vruddhavastha
- Sthana : Dakshina pada
- Sankya : One
- Akrti : Vrutha
- Varna : Pandu
- Srava : Puya, Pandu varna, Putigandha, Sandra, picchila
- Shareera : Madhyama

Sparshana : Sheeta, Katina**Prashna**

- Hetu : Guru, Madhura, Snigda Ahara Sevana, Mamsa Sevana, Dadhi Sevana, Divaswapna, Atichankramana, Atichinta.
- Vedana : Present - Chumachumayana Vat, Todha.

- *Kala* : Chirakalina

Examination of Ulcer

History

1. Mode of onset : Spontaneous
2. Duration : 2 months
3. Pain : Present
4. Discharge : Pus
5. Associated disease : Diabetes

Local Examination

1. Inspection

- Size : 3.5cm x 2.5cm x 3mm, cavity was present at the anterior part of the ulcer which measures about 2.5cm
- Shape : Circular
- Number : One
- Position : Plantar aspect of right foot
- Edge : Slightly indurated
- Floor : Slough is noted
- Discharge : Purulent
 - Amount : Scanty
 - Smell : foul
- Surrounding area : Hyper pigmented

Palpation

- Edge : Slightly indurated
- Margin : Slightly thickened
- Base : Slightly indurated
- Depth : 3mm
- Bleeding : Bleeding on touch absent
- Surrounding skin : No marked increased temperature
 - Tenderness : Present at the medial aspect of the wound

- Fixity to deeper structures : Absent

- Examination of vascular insufficiency : Popliteal pulse, Dorsalis pedis pulse, Posterior tibial pulse - present

Investigation

- Blood urea - 30mg/dl
- Serum creatinine - 1.0 mg/dl
- Glycosylated Hemoglobin - 8.2 %
- FBS : 173mg/dl
- PPBS : 336mg/dl

Right lower limb venous doppler study

Impression - Patent deep venous system right lower limb. Competent saphenofemoral and saphenopopliteal junctions. Mild diffuse soft tissue edema of the lower leg and foot.

Right lower limb Arterial doppler study

Impression - Diffuse atherosclerotic changes.

MATERIALS AND METHODS

Preparation of Aragwadhadi Qwatha: Required quantity of *Aragwadhadi Qwatha Choorna* was taken and boiled in 8 parts of water and was reduced to one fourth and filtered in a clean vessel. The filtrate was used luke warm for *Prakshalana*. (Fig.1)



Fig. 1: Aragwadhadi Qwatha Choorna with Water

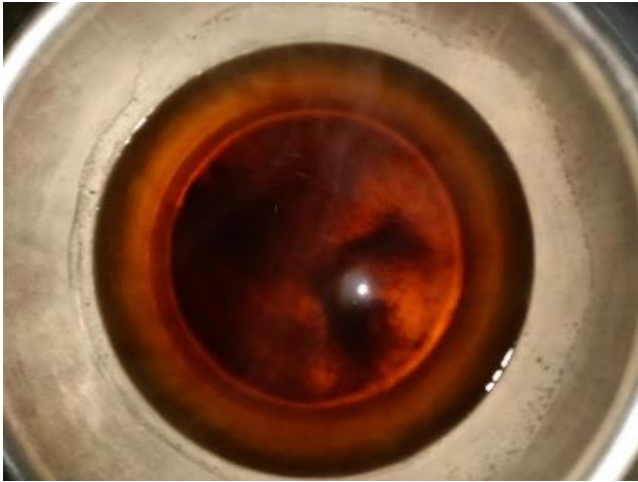


Fig. 2: Aragwadhadi Qwatha

Preparation of Kshara Picchu

- 4-5 strands of gauge was taken.
- *Mrudu Chitraka Kshara* was smeared over the strands of gauge and a *Pichu* was prepared.
- And kept for drying in the *Kshara Sutra* cabinet.



Fig. 3: Chitraka Kshara Picchu

Treatment

1. *Vrana Prakshalana* with *Aragwadhadi Qwatha*
 2. *Vrana Doopana* with *Guggulu, Nimba Choorna, Haridra, Jatyadighrita*
 3. Dressing with *Jatyadi Taila*
- } 10 Days



Fig. 4: Vrana Dhupana

Other medicines: Inj. Insugen 30/70 According to sliding scale

Internally

- Cap. GP 500 1-0-1 A/F
- Tab. *Gandhaka Rasayana* 1-0-1 A/F
- *Mahamanjistadi Kwatha* 15ml-0-15ml with 30ml of warm water B/F
- Tab. *Nishamalaki* 1-0-1 B/F
- *Triphala Guggulu* 1-1-1 A/F

on 10th day - Pus discharge was noted from the cavity of the ulcer.

Treatment from 11th day onwards

1. *Vrana Prakshalana* with *Aragwadhadi Qwatha*
2. *Kshara Picchu* insertion to the ulcer cavity 7 days. (Fig. 5)
3. For the remaining healthy granulation tissue dressing with *Jatyadi Taila*.

Treatment from 18th day onwards

1. *Vrana Prakshalana* with *Aragwadhadi Qwatha*
 2. *Jatyadi Taila Picchu* insertion to the ulcer cavity.
 3. Dressing with *Jatyadi Taila*
- } 10 Days

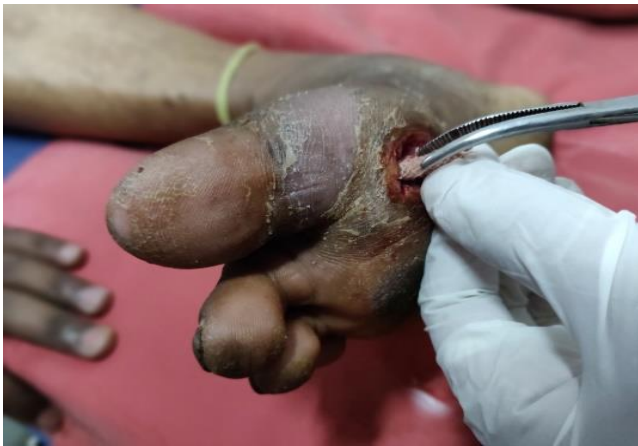

Fig. 5: Kshara Picchu insertion

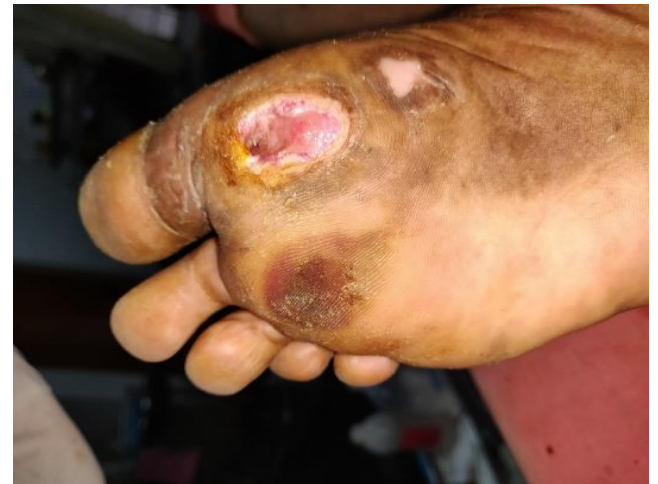

Fig. 8: Wound on 10th day - *Roohyamanavrana* - *Kapota Varna Pratima*, *Kledavarjita*, *Sthira*, *Pitikavanto*.

OBSERVATION AND RESULTS

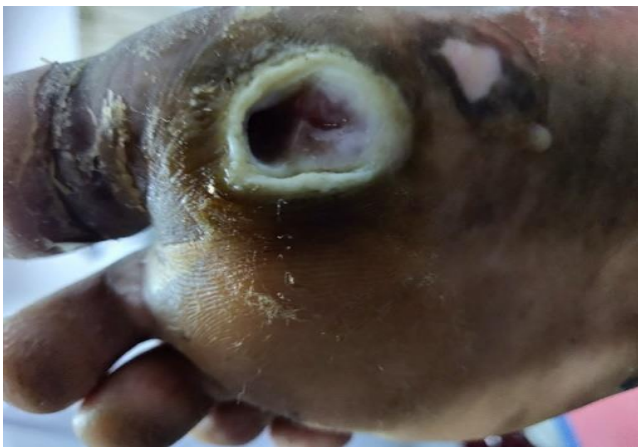

Fig. 6: On the day of admission

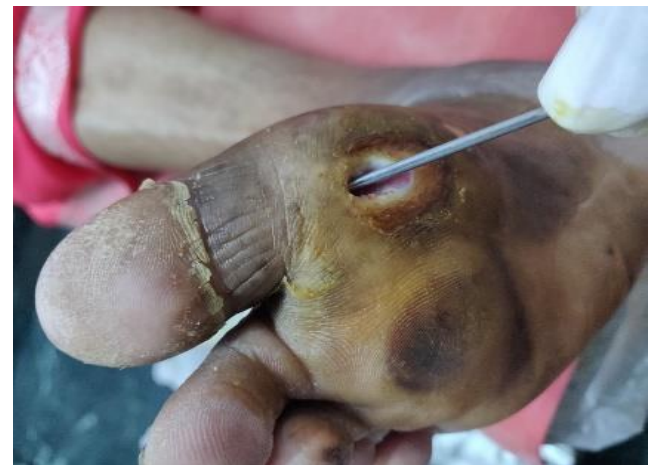

Fig. 9: Depth of the cavity - 1 cm on 15th day

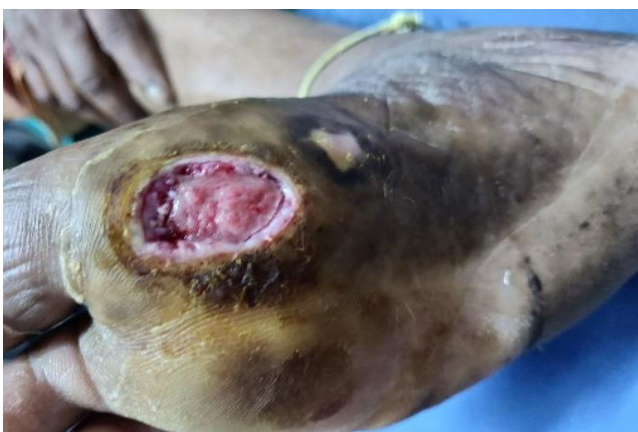

Fig. 7: Wound on 5th day - The healing was started with the formation of healthy granulation tissue. The wound started to contract by filling of tissue from the base of the wound day by day.

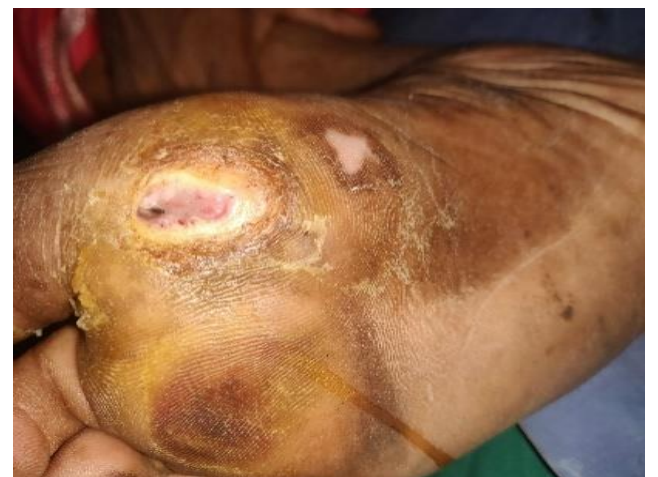

Fig. 10: On 20th day - It was observed that wound size was markedly reduced.

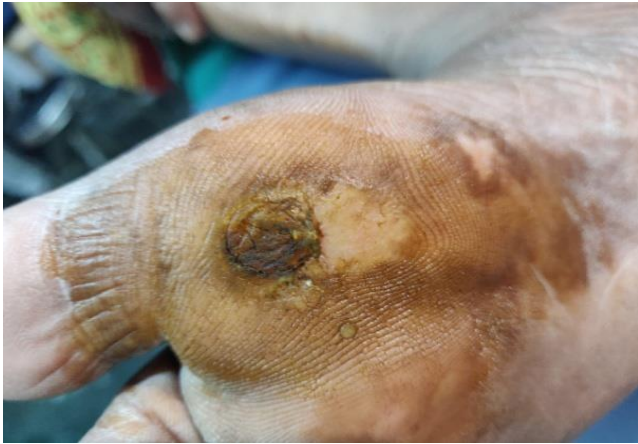

Fig. 11: On 27th day - The wound completely healed

DISCUSSION

Aragvadhadi Gana Dravyas are having the properties of *Vrana Shodhaka*, *Shothahara*, *Vedanasthapana*, *Ropaka* and *Mehahara*. And *Acharya Vagbhata* has explained *Aragvadhadi Gana Dravyas* can be used in *Madhumeha Vrana*. As it has anti inflammatory, analgesic, antibacterial hypoglycemic effects, hence for the *Vranashodhanartha Prakshalana* was done with *Aragvadhadi Kwatha*.

Acharya Sushruta while explaining about the wound care, has given importance to *Dhoopana*, *Dhoopana* is indicated in *Vranas* which are having *Ruja*, *Srava*, *Durgandha* the drugs like *Guggulu*, *Nimba Patra*, *Haridra*, *Jatyadi Ghrita* are *Shothahara*, *Vedanasthapana* and *Ropaka*, which are important requirements for the healing of wound.

Pus discharge was noted from the cavity of the ulcer hence *Kshara Picchu* treatment was started as the *Kshara* is having *Lekhana* property, and the *Vrana Shodhana*, *Ropana* properties of *Kshara* are helpful in the healing of discharge wounds. Most of the ingredients used in *Jatyadi Taila* are *Shothahara*, *Vedanasthapana* and *Ropaka*, the drugs like *Nimba*, *Daruharidra* are having antibacterial effect which promotes healing.

CONCLUSION

Diabetic ulcers might end up in amputation of the limb, if not treated properly. In our classic's

importance was given to *Vranashodhana* and *Vranaropana*. The present study was carried out giving importance to *Vranashodhana* and *Ropana*. *Acharya Vagbhata* has explained that *Vranas* which are caused by *Madhumeha* can be treated with *Aragvadhadi Gana Dravyas*. *Aragvadhadi Gana Dravyas* are having the properties of *Vrana Shodhaka*, *Shothahara*, *Vedanasthapana*, *Ropaka* and *Mehahara*, hence for the *Vrana Shodhanartha Prakshalana* was done with *Aragvadhadi Kwatha*. *Acharya Sushruta* says *Dhoopana* is useful for the *Vranas* which are having *Srava*, *Vedana*, *Durgandha*. The drugs like *Guggulu*, *Nimba Patra*, *Haridra*, *Jatyadi Ghrita* are *Shothahara*, *Vedanasthapana* and *Ropaka*, which are important requirements for the healing of wound. Pus discharge was noted from the cavity of the ulcer, hence *Kshara Picchu* treatment was started as the *Kshara* is having *Lekhana* property, and the *Vrana Shodhana*, *Ropana* properties of *Kshara* are helpful in the healing of discharge wounds. Most of the ingredients used in *Jatyadi Taila* are *Shothahara*, *Vedanasthapana* and *Ropaka*, the drugs like *Nimba*, *Daruharidra* are having antibacterial effect which promotes healing.

REFERENCES

1. Somen Das; A manual on clinical surgery, SD Kolkata, 9th edition, 4th chapter, Pg-70, Pp-650.
2. Sriram Bhat M; SRB's manual of surgery, Jaypee Brothers' Medical Publishers (P) LTD, 4th edition, 1st chapter, pg-25, pp-1335.
3. S. Das : A concise textbook of surgery , SD Kolkata 2012, 7th edition, 11th chapter, Pg – 161-162, Pp-1358.
4. Sushruta: Sushruta Samhita with commentary of Dalhana, edited by Vaidya Jadavaji Trikamji Acharya, Chowkhamba Surbharti Prakashan, Varanasi, reprint 2009, Chikitsa Sthana, 1st Chapter, Verse 8, Pg-397, Pp-824.
5. Vagbhata; Astanga Hrudayam with commentary of Arunadatta and Hemadri, Chaukhambha Orientalia Varanasi, Uttara Sthana, 25th chapter, verse 41, Pg-867, Pp-956.

6. Sushruta: Sushruta Samhita with commentary of Dalhana, edited by VaidyaJadavaji Trikamji Acharya, Chowakhamba Surbharti Prakashan, Varanasi, reprint 2009, Chikitsa Sthana, 1st Chapter, Verse 80, Pg-404, Pp-824.
7. Sushruta: Sushruta Samhita with commentary of Dalhana, edited by Vaidya Jadavaji Trikamji Acharya, Chowakhamba Surbharti Prakashan, Varanasi, reprint 2009, Sutra Sthana, 5thChapter, Verse18, Pg-21, Pp-824.

8. Pandit Sharangadharacharya; Sharangadhara Samhita, Madhyama khanda, 9th chapter, verse 168-171,Pg-229,Pp-398.

How to cite this article: Dr. Shruthi P, Dr. Shailaja SV. A Single Case Study of Diabetic Foot Ulcer treated with Vrana Dhoopana and Kshara Picchu. J Ayurveda Integr Med Sci 2019;1:109-115.
<http://dx.doi.org/10.21760/jaims.4.1.22>

Source of Support: Nil, **Conflict of Interest:** None declared.
