



ISSN 2456-3110

Vol 4 · Issue 2

Mar-Apr 2019

Journal of
**Ayurveda and Integrated
Medical Sciences**

www.jaims.in

JAIMS



Charaka
Publications

Indexed

Ksharavarti Prayoga (Alkali thread) in Puyalasa (Acute Dacryocystitis) : A Case Report

Dr. Sushobhitha M,¹ Dr. Sujathamma K.²

¹Post Graduate Scholar, ²Professor & HOD, Dept. of Post Graduate Studies in Shalaky Tantra, Sri Kalabyraveshwara Swami Ayurvedic Medical College and Research Centre, Vijayanagar, Bangalore, Karnataka, INDIA.

ABSTRACT

Puyalasa, one among the *Sandhigataroga* can be correlated to dacryocystitis based on the symptomatology which includes swelling in inner canthus, which later undergoes suppuration causing thick purulent discharge. Dacryocystitis is the inflammation of the lacrimal sac. Management of acute dacryocystitis differs based on the stage. *Puyalasa* treatment includes *Raktamokshana* (blood letting), *Upanaha* (poultice) and other *Vranashotha* (inflammatory swelling) treatment. A 28 year old female patient diagnosed as *Puyalasa* (acute dacryocystitis) was treated with blood letting, *Ksharavarti* (alkali thread) insertion and *Bidalaka* (applying medicines in paste form over eyelids) and the results proved to be significant on the basis of clinical assessment.

Key words: *Puyalasa*, *Dacryocystitis*, *Ksharavarti*, *Bidalaka*, *Raktamokshana*.

INTRODUCTION

Puyalasa is one among the *Sandhigata Rogas*.^[1] It is *Tridoshaja Vyadhana Sadhya Vyadhi*.^[2] According to *Acharya Sushruta*, *Puyalasa* is a disease where there will be inflammation in the inner canthus leading to thick purulent discharge.^[3] According to *Acharya Vagbhata*, swelling and discharge occurs at inner canthus which leads to thick purulent discharge and a minute opening in the skin.^[4] Owing to the symptoms of *Puyalasa* it can be co-related to Acute Dacryocystitis.

Dacryocystitis is an inflammatory condition of lacrimal sac, which is caused secondary to obstruction and

blockage of normal drainage of tears that leads to secondary infection.^[5] This complication is associated with structural abnormality, infectious disorder of the eye, and traumatic injury. The main clinical symptoms include pain, redness and swelling of lacrimal sac at medial canthus and epiphora due to inadequate drainage of tears. Dacryocystitis occurs in both acute and chronic forms. Management of Dacryocystitis will differ according to conditions.

In Ayurveda the management of *Puyalasa* includes; *Raktamokshana* (blood letting), *Upanaha* (poultice), *Anjana* (applying medicated kajal), *Vranashotha Chikitsa* (treatment of inflammatory swelling) according to *Acharya Sushruta*^[6] and *Vagbhata*. According to the condition we can choose the treatment modality.

Ksharavarti Prayoga is mentioned by *Acharya Sushruta* in *Nadivrana Chikitsa* (Sinus treatment).^[7]

MATERIALS AND METHODS

Case history

A 28 years old female patient came to outpatient department (Registration number F15073) on 8th May 2018, with complaints of swelling near the inner canthus of right eye for 10 days. It was associated

Address for correspondence:

Dr. Sushobhitha M.

Post Graduate Scholar, Dept. of Post Graduate Studies in Shalaky Tantra, Sri Kalabyraveshwara Swami Ayurvedic Medical College, Hospital and Research Centre, Bengaluru, Karnataka, INDIA.

E-mail: sushobhitham91@gmail.com

Submission Date: 09/02/2019 Accepted Date: 21/03/2019

Access this article online

Quick Response Code



Website: www.jaims.in

DOI: 10.21760/jaims.4.2.18

with severe pain, redness in and around the right inner canthus and watering from right eye.

Patient gave the history of an abrasion near right inner canthus by her son 6 months back. She neglected it but after 2-3 days developed a small swelling over scratched region which was associated with mild pain, redness. She consulted an ophthalmologist and had been advised antibiotic eye drops and analgesics. She got relief from complaints. After 3 months she developed with on and off mild watering from right eye. 10 days before once again she developed a small swelling in the same region. Day by day swelling increased in size and associated with redness and pain. After 1 week, pain increased and started to get mild to moderate watering from right eye. When she approached Shalakya OPD on 8/5/18, *Bidalaka* and leech therapy was done. 10 days after treatment once again she approached OPD with a small opening and pus discharge from the opening.

Local examination: on 8/5/18

Right eye - lacrimal apparatus : lacrimal puncta - swelling near puncta seen, skin over sac region - reddish discoloration ++ and pus point was there, secretion/ pus discharge - present on regurgitation test.

Lower lid - mild swelling and redness +

VA - OD - 6/6(P), OS - 6/6

On 21/5/18 - an external opening over pus point was present, skin over sac region - reddish discoloration ++

On lacrimal probing - track measurement was 3-4mm.

Materials used for procedure

Bidalaka - *Triphala Churna* (*Haritaki* - *Terminalia chebula*, *Amalaki* - *Phyllanthus emblica*, *Vibhitaki* - *Terminalia bellirica*), pinch of *Shunti Churna* (*Zingiber officinale*).

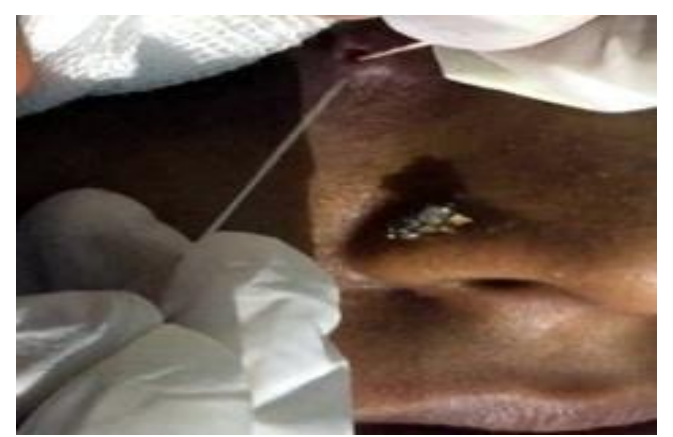Kshara Varti preparation : *Mrudu Kshara* (mild alkali) was prepared from *Kadali Kanda* (banana stem). Surgical barbour linen thread no. 20 was taken and dipped in *Kshara* and dried in *Kshara Sutra* cabin.

Method of application

Under aseptic precautions, the surrounding area was cleaned with spirit and the sac area was cleaned with betadine solution. The *Kshara Varti* was inserted into the opening daily once for three sittings and there after on alternative days for 3 sittings. After insertion of *Kshara Varti* bandaging was done.

Treatment history

Kshara Varti insertion

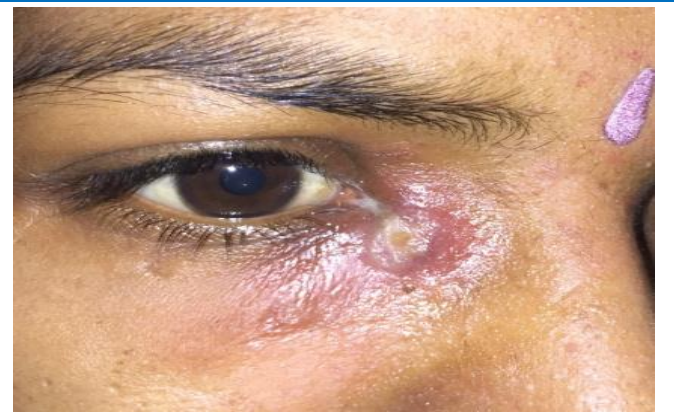


OBSERVATIONS

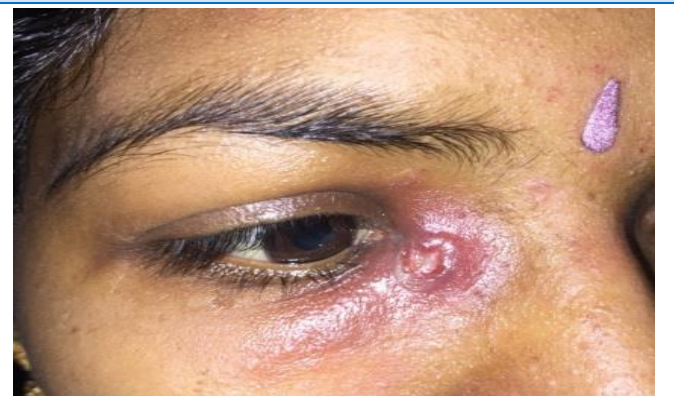The observations made before and during the treatment have been given below in table.

Date	Observation	Treatment given
8/5/18	Swelling, redness, tenderness	<i>Bidalaka</i> with <i>Triphala</i> and pinch of <i>Shunti Churna</i> done
9/5/18	Swelling, redness, tenderness	<i>Jalaukavacharana</i> at <i>Upanasika</i> was done followed by bandaging.
10/5/18 - 12/5/18	Swelling and redness reduced, mild pain	<i>Bidalaka</i> with <i>Triphala</i> and pinch of <i>Shunti Churna</i> done
21/5/18 - 23/5/18	Swelling, redness, an external opening with pus discharge	<i>Kshara Varti Prayoga</i> followed by bandaging daily
24/5/18 - 28/5/18	Swelling and redness reduced, Mild pus discharge	<i>Ksharavarti Prayoga</i> on alternative days.
30/5/18	Pus discharge absent,	<i>Bidalaka</i> with

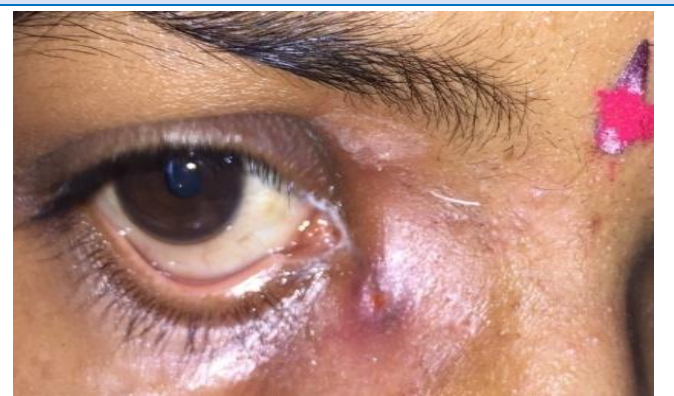- 2/6/18	external opening healed, mild swelling and pain on lacrimal syringing	<i>Triphala</i> and pinch of <i>Shunti Churna</i> .
5/6/18	On lacrimal syringing patient felt saline in throat, all complaints relieved.	



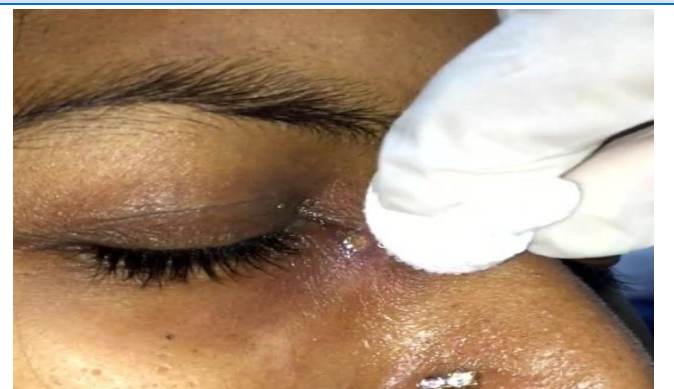Observation made on 21/5/18



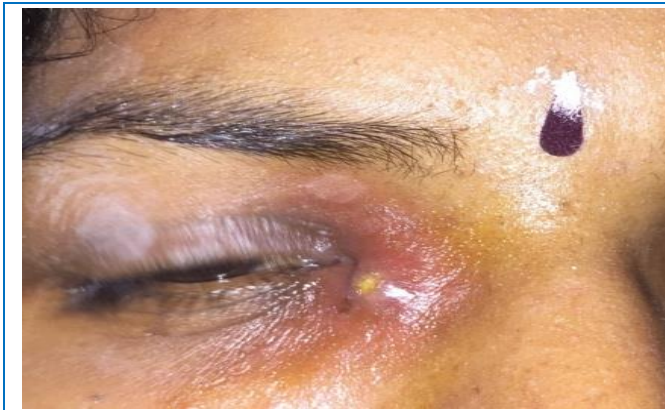Observation made on 22/5/18



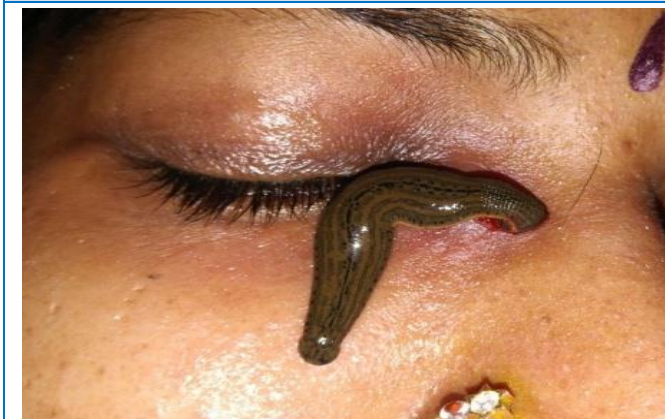Observation made on 25/5/18



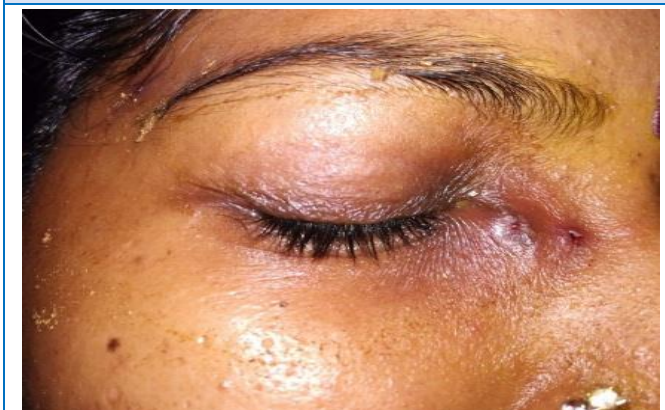Observation made on 5/6/18



Observation made on 8/5/18



Observation made on 9/5/18



Observation made on 10/5/18

DISCUSSION

Blood letting is first line of treatment advised by *Acharya Sushruta* and *Vagbhata*. *Jalaukavacharana* (leech application) is the easiest and convenient method of blood letting. Leech contains hirudin, calin, bdellins, euglins, destabilase in its saliva. These are anti-inflammatory, anti-coagulatory in nature. Hence it increases blood flow in that region, eliminates toxins and increases nutrition to affected area. Therefore *Jalukavacharana* has the property to subside immediately the pain, swelling, burning sensation and redness. *Acharya Charaka* and *Acharya Vagabhata* have indicated *Bidalaka* (application of medicine in paste form) in eye diseases with edema, lacrimation and redness.^[8] In *Puyalasa*;

1) Stage of swelling (Shopha) - one can choose *Bidalaka*. In this procedure medicine applied on the outer surface of lids leaving the eye lashes is absorbed by the skin due to the potency of drugs and reduces the local temperature there by relieves inflammation, imparting soothing effect and relieves pain. *Triphala Churna* is *Tridosahara* (pacifies *Vata*, *Pitta* and *Kapha*), *Vranaropaka* (wound healing) and helps in reducing swelling, redness and pain. It has actions like anti-microbial, anti-bacterial and anti-inflammatory, therefore it helpful in controlling the infection and inflammation. *Shunti Churna* helps to reduce the *Shopha* (swelling).

2) Stage of sinus formation - *Mridukshara* in the form of *Ksharavarti* can be inserted into the sac through the external opening. *Ksharasutra* (alkali thread) has proved out to be an effective treatment in *Nadi Vrana* (sinus). It has *Ksharana* (removal of unhealthy and dead tissues) and *Kshanana* (cleansing action) properties of *Kshara* by which the unhealthy granulation tissue is replaced by healthy granulation tissue and thus it facilitates healing.

CONCLUSION

Puyalasa should be managed properly, other wise it will lead to *Pillaroga*. Dacryocystitis is a common ocular condition with high recurrence rate. Dacryocystitis if not treated properly leads to many

complications like Acute conjunctivitis, corneal abscess, lid abscess, osteomyelitis of lacrimal bone, orbital cellulitis, facial cellulitis, acute ethmoiditis, Chronic intractable conjunctivitis, Ectropion of lower lid, Corneal ulcerations. Usage of *Kshara* and other ocular therapies like *Bidalaka* one can give effective treatment and reduce recurrence.

REFERENCES

1. Acharya Sushruta, Sushruta Samhitha, Nibandha samgrahatika of Dalhana and Nyaya Chandrikatika Gayadasa, Chowkhamba Sanskrit Samsthan, Varanasi, Edition-2015; Uttarantra, Chapter 2, Verse 3,pp: 598-824.
2. Acharya Sushruta, Sushruta Samhitha, Nibandha samgrahatika of Dalhana and Nyaya Chandrikatika Gayadasa, Chowkhamba Sanskrit Samsthan, Varanasi, Edition-2015; Uttarantra, Chapter 2, Verse-4,pp598-824.
3. Acharya Sushruta, Sushruta Samhitha, Nibandha samgraha tika of Dalhana and Nyaya Chandrikatika Gayadasa, Chowkhamba Sanskrit Samsthan, Varanasi, Edition-2015; Sharirasthana, Chapter 2, Verse 4,598-824.
4. Vagbhata, Astanga hrdaya, Sarvangasundara of Arunadatta and Ayurveda rasayana of Hemadri, Chowkhamba Sanskrit Samsthan, Varanasi, Edition-2015; Uttarasthana, chapter-22, verse- 108, 858-956.
5. A K Khurana & Aruj K Khurana. Comprehensive Ophthalmology. 6th edition. New Delhi. Jaypee Brothers Medical Publishers(P) Ltd.pp-623, pg-393
6. Acharya Sushruta, Sushruta Samhitha, Nibandha samgraha tika of Dalhana and Nyaya Chandrikatika Gayadasa, Chowkhamba Sanskrit Samsthan,Varanasi, Edition-2015; Sharirasthana, Chapter 12, Verse,45: 618-824.
7. Acharya Sushruta, Sushruta Samhitha, Nibandha samgraha tika of Dalhana and Nyaya Chandrikatika Gayadasa, Chowkhamba Sanskrit Samsthan,Varanasi, Edition-2015; chikitsasthana, Chapter 17, Verse 28-30.
8. Agnivesha, Charaka Samhita, Ayurveda Deepika Commentary of Chakrapani, edited by; Vaidya YadavjiTrikrampji Acharya, Choukambha Surabharati Prakashan, Varanasi, reprint-2014, Chikitsasthana, chapter 26th, Verse 231, Pp: 738, Page no 610.

How to cite this article: Dr. Sushobhitha M, Dr. Sujathamma K. Ksharavarti Prayoga (Alkali thread) in Puyalasa (Acute Dacryocystitis) : A Case Report. J Ayurveda Integr Med Sci 2019;2:140-144.
<http://dx.doi.org/10.21760/jaims.4.2.18>

Source of Support: Nil, **Conflict of Interest:** None declared.
