



ISSN 2456-3110

Vol 4 · Issue 5

Sept-Oct 2019

Journal of
**Ayurveda and Integrated
Medical Sciences**

www.jaims.in

JAIMS

An International Journal for Researches in Ayurveda and Allied Sciences



Charaka
Publications

Indexed

Nephroprotective activity of *Mundi* (*Sphaeranthus indicus* Linn.) - An Experimental Study

Dr. Seema Pradeep¹, Dr. Mahesh CD², Dr. Manjunath PM³, Dr. Saraswathidevi HN⁴

¹Professor & Head, ²Professor, ⁴Post Graduate Scholar, Department Of Dravyaguna, Sri Sri College Of Ayurvedic Science and Research, Bangalore, ³Associate Professor, Department of Pharmacology, Acharya & BM Reddy College of Pharmacy, Bangalore, Karnataka, INDIA.

ABSTRACT

Background: *Sphaeranthus indicus* Linn. (*Mundi*) is a medicinal plant widely used in Indian traditional and folk systems of medicine for treating various ailments. In the Indian system of medicine, the plant as a whole plant or its different anatomical parts viz., leaf, stem, bark, root, flower and seed are widely used for curing many diseases. The plant is bitter, stomachic, restorative, alterative, pectoral, demulcent and externally soothing. **Aim:** The present study was undertaken to scientifically evaluate the nephroprotective activity of the aqueous extract & ethanolic extract of *Mundi*, *Sphaeranthus indicus* Linn. **Methodology:** Experimental grouping, Group-1 served as health control; received purified water (5ml/kg, p.o.). Group -2 served as Nephrotoxic control; This group of animals received daily i.p. injection of gentamicin (80mg/kg body weight) for eight days. Group 3,4,5,6 animals of this group received 80 mg/kg of gentamicin i.p. nearly for eight days in addition to this they also received aqueous extract low dose (200mg), aqueous extract high dose (400mg), ethanolic extract low dose (200mg) and ethanolic extract high dose (400mg) respectively which was started three days prior to the gentamicin injection and continued with 8 days gentamicin treatment. Histopathological studies on isolated kidney revealed that the aqueous extract & ethanolic extract of *Sphaeranthus indicus* Linn, reversed the kidney damage and also restored normal kidney architecture. Statically Values are expressed in mean \pm S.E.M. (n=6), ** = p<0.01 and *** = p<0.001. **Conclusion:** The aqueous extract & ethanolic extract of *Sphaeranthus indicus* Linn. showed statistically significant nephroprotective activity. The plant extract proved to have nephroprotective potentials may because of its known flavonoids, saponins, tannins, and phenolic compounds.

Key words: Nephroprotective activity, *Sphaeranthus indicus* Linn., *Mundi*, *Gorakh Mundi*, *Gentamicin*.

INTRODUCTION

Sphaeranthus indicus Linn. commonly known as *Gorakh Mundi* is an annual spreading herb which grow up approximately 16-30cm height, the plant is

distributed throughout the plains and wet lands of India. Traditionally it is used for the treatment of *Kamala*, *Kushta*, *Jwara*, *Kasa* and some of the *Vrikka Vikaras*.^[1]

Address for correspondence:

Dr. Seema Pradeep

Professor & Head, Department Of Dravyaguna, Sri Sri College Of Ayurvedic Science and Research, Bangalore, Karnataka, INDIA.

E-mail: drvikramayur@gmail.com

Submission Date: 27/08/2019

Accepted Date: 10/10/2019

Access this article online

Quick Response Code



Website: www.jaims.in

DOI: 10.21760/jaims.4.5.24

The plant is known to possess varied medicinal properties and is reportedly used in classical Ayurvedic preparations for treating many disorder. This study was aimed over view on traditional use of the drug *Gorakh Mundi*, its phytochemical, pharmacological investigation and experimental evaluation on rats to elucidate the efficacy of drug in nephrotoxicity.^[1]

Nephrotoxicity is one of the most common kidney problem and occurs, when body is exposed to a drug or toxins. A number of therapeutic agents can adversely affect the kidney resulting in acute renal

failure, chronic interstitial nephritis and nephritic syndrome, because there is an increasing number of potent therapeutic drugs like amino glycoside, antibiotics, NSAID's, chemotherapeutic agents, have been added to the therapeutic around in recent years.^[2]

Acute renal failure refers to the sudden and usually reversible loss of renal function which develops over a period of days or weeks. There are many causes for renal failure which mainly includes acute tubular necrosis and commonly occurs for 85% of incidence, most acute tubular necrosis occurs either due to ischemia or toxins. The toxins may be exogenous agents or endogenous agents.^[3]

Considering the above incidence of the disease and use of the drug in traditional practice the present study "To evaluate the Nephro-protective activity of Mundi (*Sphaeranthus indicus* Linn. in Gentamicin induced Nephrotoxicity in experimental animals." is selected.

OBJECTIVE OF THE STUDY

To do toxicological and experimental evaluation of nephroprotective activity of *Sphaeranthus indicus* Linn.

METHODOLOGY

Toxicity Study (For dose fixing)^[4]

Acute Toxicity Study

Acute oral toxicity study of aqueous and alcoholic extract of whole plant of *Sphaeranthus indicus* Linn. was carried out according to OECD guidelines 425 for limit test.

Principle: The limit test is primarily used in situation where the experimental has prior information indicating that the material to be tested is likely to be non-toxic, that is having toxicity only above regulatory limit doses. Thus, it allows the starting dose of 2000 mg/kg and also 5000 mg/kg. the limit test is a sequential test that uses a maximum of 4 animals.

Method:

- Nulliparous, non-pregnant and 8 to 12 weeks old female rats weighing around 200 ± 10 gms where used

- A single dose of *Sphaeranthus indicus* Linn. extract (2000mg/kg b.w) was administrated to one of the animals included in the study.
- A single dose of *Sphaeranthus indicus* Linn. extract (5000mg/kg b.w) was administrated to one of the animals included in the study.
- Based on whether animals survived or died, suitable test were performed (if died, main test was performed and if survived, same test was continued with remaining animals).
- If three animals died the limit test was terminated and the main test was performed.
- The animals were observed continuously for 2 hours under following profile.

Behavioral profile: Spontaneous, restlessness, irritability and fearfulness.

Neurological profile: Spontaneous activity, reactivity, touch response, pain response and gait.

Autonomic profile: Defecation and urination. After period of 24 and 72 hours they were observed for any lethality or death. If toxic signs of lethality are not observed, then 1/5th, 1/10th part of the limit test dose were considered as test doses for present investigation.

Dose fixing^[5]

Acute oral toxicity studies revealed that there is no toxicity and no mortality of the rates with aqueous and ethanol extract of *Sphaeranthus indicus* Linn. are up to 2000mg /kg and 5000mg / kg body weight even after 14 days.

Preparation of the dose

Based on the body weight of the animals, dose is calculated separately for each animals and dose is fixed. For 1gm of drug , 5ml of distilled water is added and finely triturated with 0.1 gm of 2% of gum acacia and given orally with the help of gastric canula dose is given individually based on the body weight of the animals which were marked prior.

- Based on the short term toxicity profile, the consecutive dose of the extract was determined

as per OECD guideline 425 the maximum dose tested (2000mg/kg) for LD₅₀. 2000 mg/kg body weight is the dose fixed as per Limit test.

- From the LD₅₀ doses like 1/5th of 2000mg = 400mg/kg body weight is the high dose 1/10th of 2000mg = 200mg/kg body weight is the low dose is taken to carry out this study.

Experimental Study

Place of Work

The toxicological and experimental study was carried out in Department of Pharmacology, Acharya & B.M. Reddy College of Pharmacy, Bengaluru.

Ethical Clearance

The experimental procedure was carried out in accordance with the ethical guidelines for animals proposed by CPCSEA, Government of India. Ethical clearance was obtained from Department of Pharmacology, Acharya & B.M Reddy College of Pharmacy, Bengaluru as per the protocol outlined in publication of the committee for the purpose of control and supervision of experiments on animals' standard guidelines (CPCSEA) and approval was obtained from Institutional Animal Ethics committee (IAEC) with reference no: IAEC/ABMRCP/2018-2019/8. Dated 30/09/2018

Selection of Animals Maintenance

The required number of healthy Wistar Albino rats of both the sex weighing 150-250g were procured from animal house, Acharya & B.M Reddy college of Pharmacy, Bengaluru. Animals were maintained under controlled temperature at 270 ± 20C and 12hours light and dark cycles.

Animals were housed in polypropylene cage and free access to standard pellets and water ad libitum

Examination of the Animals prior to the experiment

- All the Wistar albino rats were subjected to general check-up for sex and weight.
- Weight of each animal was checked by using balance.

- Identification of the animals was done by specific marking with picric acid.
- The cages were labelled with the number of animals and dosage groups.

Inclusion Criteria

Albino-wistar strain rats weighing 150-250 g. of either sex are selected, healthy with normal behaviour and activity.

Exclusion Criteria

- Albino -wistar strain rats which are pregnant.
- Albino-wistar strain rats showing signs of infection during the course of study.
- Albino-wistar rats under other experiments.

Route of administration: The drugs were administered orally through rat gauging needle no 24.

Grouping^[6]

Table 1: For experimental evaluation of nephroprotective activity

SN	Group	No. of animals used	Drug used.
1.	Health Control	6	Purified water 5ml/kg/po
2.	Nephrotoxic Control	6	Inj Gentamicin 80mg/kg body wt IP
3.	Aq. Extract low dose (200mg)	6	Inj Gentamicin 80mg/kg body wt IP + Aq Extract low dose
4.	Aq. Extract high dose (400mg)	6	Inj Gentamicin 80mg/kg body wt IP + Aq Extract high dose
5.	Ethanollic extract low dose (200mg)	6	Inj Gentamicin 80mg/kg body wt IP + Ethanollic extract (Low dose)

6.	Ethanollic extract high dose (400mg)	6	Inj Gentamicin 80mg/kg body wt IP + Ethanollic extract high dose
----	--------------------------------------	---	--

Group - 1 served as health control; received purified water (5ml/kg, p.o.).

Group - 2 served as Nephrotoxic control; This group of animals received daily i.p. injection of gentamicin (80mg/kg body weight) for eight days.

Group 3,4,5,6 animals of this group received 80 mg/kg of gentamicin i.p. nearly for eight days in addition to this they also received aqueous extract low dose (200mg), aqueous extract high dose (400mg), ethanolic extract low dose (200mg) and ethanolic extract high dose (400mg) respectively which was started three days prior to the gentamicin injection and continued with 8 days gentamicin treatment.

Analysis of General Parameters

a) Estimation of Body weight: All the animals of each group are weighed individually at the beginning and end of the study,

b) Estimation of urine glucose.

- Each group of one animal was kept in individual cages and 24hr urine sample was collected on 11th day.
- All the animals were free access to drinking water during the urine collection period.
- Urine was analyzed for glucose

c) Blood collection techniques used in the present study: At the end of the experimental period, i.e. on the 11th day, the blood was collected by retro-orbital vein puncture using a fine capillary to an anticoagulant tube and allowed to stand for 30 min at 37°C and then centrifuged to separate the serum to evaluate the biochemical markers.^[7]

d) Analysis of serum biochemical parameters

- Estimation of Serum creatinine.
- Estimation of Serum urea.
- Estimation of Serum protein.

e) Histopathology analysis

At the end of the experimental period, i.e. on the 11th day, the abdomen was cut opened to remove both kidneys from one animal of each group. Isolated kidneys were cleaned off extraneous tissue and preserved in 10% Neutral Formalin.

f) Preparation of kidney homogenate^[7]

The kidney was quickly removed and perfused immediately with ice-cold saline (0.9% NaCl). A portion of the kidney was homogenized in chilled Tris-HCl buffer (0.025 M, pH 7.4) using a homogenizer. The homogenate obtained was centrifuged at 5000 rpm for 10 minutes, supernatant was collected and used for various biochemical assays.

Statistical Analysis

The results were expressed in mean \pm S.E.M. The difference among the data was statically analysed using one-way ANOVA followed by Turkey's test to determine the level of significance using prism, graph pad version5, (Graph pad software Inc.) difference between the data were considered significant at $P < 0.05$.

RESULTS

Assessment of General Parameters

Table 2: Representation of effect of AESI & EESI on Urea, Creatinine, Total protein, Urine Glucose, and Kidney weight in 6 groups of Experimental Study.

Group	Urea (mg/dL)	Creatinine (mg/dL)	Total Protein (g/dL)	Urine Glucose (mg/dL)	Kidney Weight (g)
Group 1	20.5 \pm 0.9	0.75 \pm 0.06	6.47 \pm 0.11	13.25 \pm 0.85	0.54 \pm 0.01
Group 2	56 \pm 1.4	2.25 \pm 0.06	12.9 \pm 0.24	27 \pm 0.91	0.85 \pm 0.22
Group 3	38.5 \pm 0.6 ***	1.77 \pm 0.06 ***	8.45 \pm 0.15 ***	18.75 \pm 0.85 ***	0.72 \pm 0.01* **
Group 4	26 \pm 1.2 ***	1.1 \pm 0.07 ***	6.75 \pm 0.06 ***	14.5 \pm 0.64 ***	0.61 \pm 0.01* **

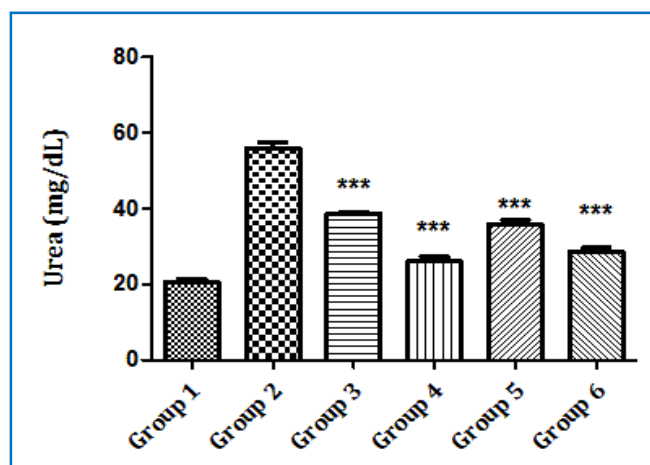
Group 5	35.75±1.3 ***	1.8±0.04 **	8.55±0.1 ***	19.5±1.19 ***	0.73±0.02* **
Group 6	28.75±0.8 ***	1.12±0.08 ***	6.6±0.16 ***	14.75±0.85 ***	0.62±0.01* **

Values are expressed in mean ± S.E.M.(n=6), **=p<0.01 and ***=p<0.001

Table 3: Representation of effect AESI & EESI on Blood Urea in 6 groups of Experimental Study.

Group	Urea (mg/dL)
Group 1	20.5±0.9
Group 2	56±1.4
Group 3	38.5±0.6 ***
Group 4	26±1.2 ***
Group 5	35.75±1.3 ***
Group 6	28.75±0.8 ***

Fig. 1: Diagrammatic representation of effect AESI & EESI on Blood Urea in 6 groups of Experimental Study.



Results

Effect of extract on Serum Urea

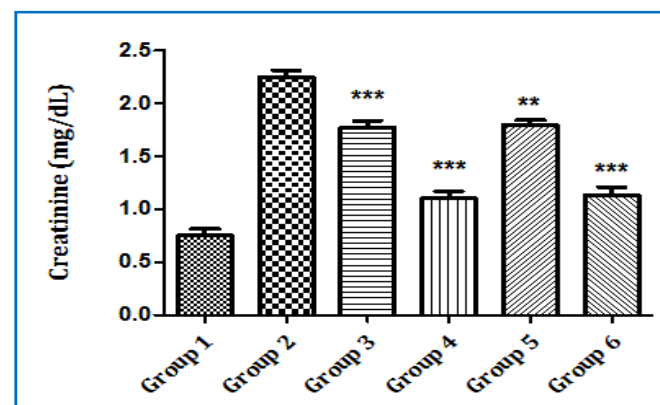
Animals in group 1 served as control group showed normal levels of serum urea (20.5±0.9 mg/dL). The effect of different doses of aqueous and ethanolic extracts on serum urea is demonstrated in Figure 1. In

groups 3, 4, 5 and 6 rats treated with lower and higher doses of aqueous and ethanolic extracts respectively showed significantly (P < 0.05) decrease in serum urea levels i.e. 38.5±0.6, 26±1.2, 35.37±1.3 and 28.75±0.8 mg/dL respectively compared to negative control group i.e. 56±1.4 mg/dL.

Table 4: Representation of effect AESI and EESI on Serum Creatinine in 6 groups of Experimental Study.

Group	Creatinine (mg/dL)
Group 1	0.75±0.06
Group 2	2.25±0.06
Group 3	1.77±0.06 ***
Group 4	1.1±0.07 ***
Group 5	1.8±0.04 **
Group 6	1.12±0.08 ***

Fig. 2: Diagrammatic representation of effect AESI and EESI on Serum Creatinine in 6 groups of Experimental Study.



Results

Effect of extract on Serum Creatinine

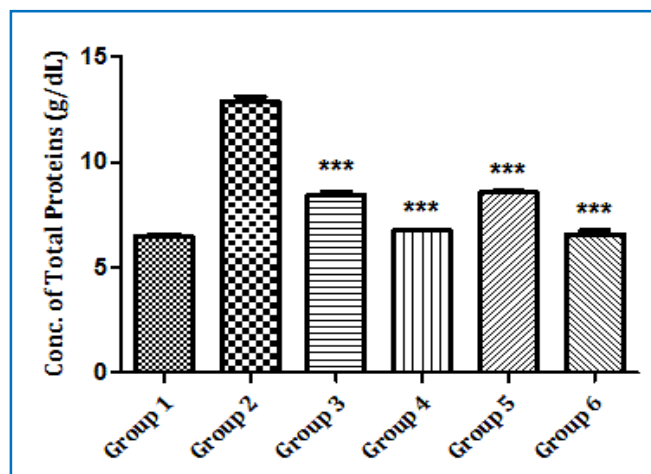
Group 1 animals served as control group showed normal levels of serum creatinine (0.75±0.06 mg/dL). The effect of different doses of aqueous and ethanolic extracts on serum creatinine is demonstrated in Figure 2. In groups 3, 4, 5 and 6 rats treated with lower and higher doses of aqueous and ethanolic extracts respectively showed significantly (P < 0.05) decrease in serum creatinine levels i.e. 1.77±0.06,

1.1±0.07, 1.8±0.04 and 1.12±0.08 mg/dL respectively compared to negative control group i.e. 2.25±0.06 mg/dL.

Table 5: Representation of effect AESI and EESI on Conc. of Total Proteins in 6 groups of Experimental Study.

Group	Total Protein (g/dL)
Group 1	6.47±0.11
Group 2	12.9±0.24
Group 3	8.45±0.15 ***
Group 4	6.75±0.06 ***
Group 5	8.55±0.1 ***
Group 6	6.6±0.16 ***

Fig. 3: Diagrammatic representation of effect AESI and EESI on Conc. of Total Proteins in 6 groups of Experimental Study.



Results

Effect of extract on Total protein

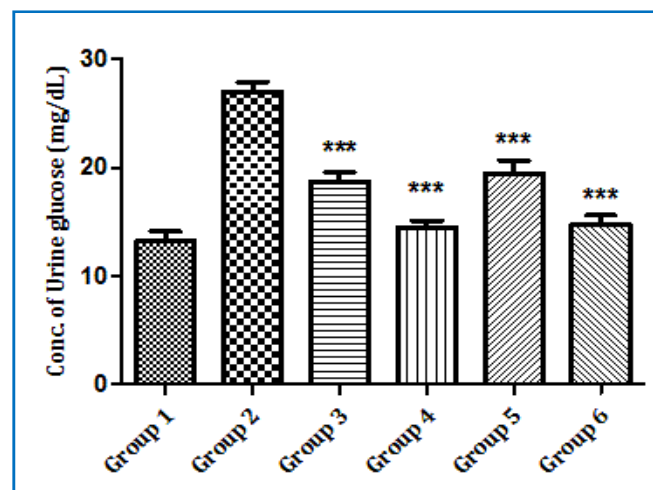
Group 1 rats served as control group showed normal levels of total protein (6.47±0.11 g/dL). The effect of different doses of aqueous and ethanolic extracts on total protein is demonstrated in Figure 3. In groups 3, 4, 5 and 6 rats treated with lower and higher doses of aqueous and ethanolic extracts respectively showed significantly ($P < 0.05$) decrease in total protein levels i.e. 8.45±0.15, 6.75±0.06, 8.55±0.1 and 6.6±0.16 g/dL

respectively compared to negative control group i.e. 12.9±0.24 g/dL.

Table 6: Representation of effect AESI and EESI on Conc. of Urine Glucose in 6 groups of Experimental Study.

Group	Urine Glucose (mg/dL)
Group 1	13.25±0.85
Group 2	27±0.91
Group 3	18.75±0.85 ***
Group 4	14.5±0.64 ***
Group 5	19.5±1.19 ***
Group 6	14.75±0.85 ***

Fig. 4: Diagrammatic representation of effect AESI and EESI on Conc. of Urine Glucose in 6 groups of Experimental Study.



Results

Effect of extract on Urine glucose levels

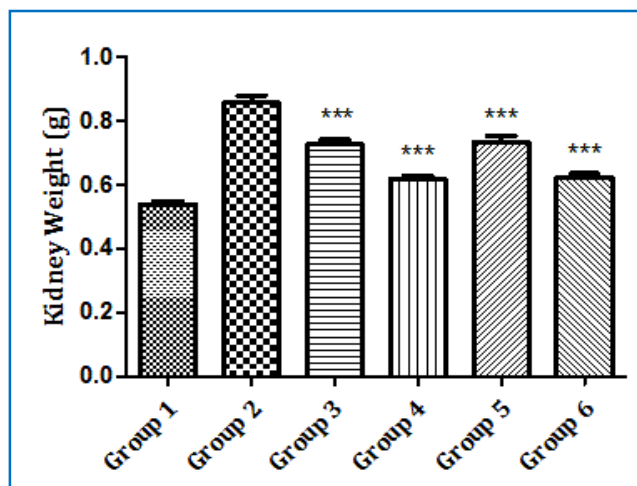
Animals in group 1 served as control group showed normal levels of urine glucose (13.25±0.85 mg/dL). The effect of different doses of aqueous and ethanolic extracts on urine glucose is demonstrated in Figure 4. In groups 3, 4, 5 and 6 rats treated with lower and higher doses of aqueous and ethanolic extracts respectively showed significantly ($P < 0.05$) decrease in urine glucose levels i.e. 18.75±0.85, 14.5±0.64,

19.5±1.19 and 14.75±0.85 mg/dL respectively compared to negative control group i.e. 27±0.91 mg/dL.

Table 7: Diagrammatic representation of effect AESI and EESI on Kidney Weight in 6 groups of Experimental Study.

Group	Kidney Weight (g)
Group 1	0.54±0.01
Group 2	0.85±0.22
Group 3	0.72±0.01***
Group 4	0.61±0.01***
Group 5	0.73±0.02***
Group 6	0.62±0.01***

Fig. 5: Diagrammatic representation of effect AESI and EESI on Kidney Weight in 6 groups of Experimental Study.



RESULTS

Effect of extract on Kidney weight

Group 1 animals served as control group showed normal of kidney weight (0.54±0.01 g). The effect of different doses of aqueous and ethanolic extracts on kidney weight is demonstrated in Figure 5. In groups 3, 4, 5 and 6 rats treated with lower and higher doses

of aqueous and ethanolic extracts respectively showed significantly ($P < 0.05$) decrease in kidney weight i.e. 0.72±0.01, 0.61±0.01, 0.73±0.02 and 0.62±0.01 g respectively compared to negative control group i.e. 0.85±0.22 g.

Histopathological Studies

Group 1: Health Control. Control Kidney showing normal architecture of glomerulus containing tuft of capillaries surrounded by Bowman's capsule (arrow). The proximal and distal convoluted tubules lined by columnar epithelial cells (asterisk).

Group 2: Nephrotoxic Control. Nephrotoxic Kidney showing disruption in the architecture with severe degeneration of glomerulus and accumulation of edema fluid (arrow), congestion of blood vessel. The proximal and distal convoluted tubules lined by columnar epithelial cells are showing vacuolar degeneration with swollen cells (asterisk).

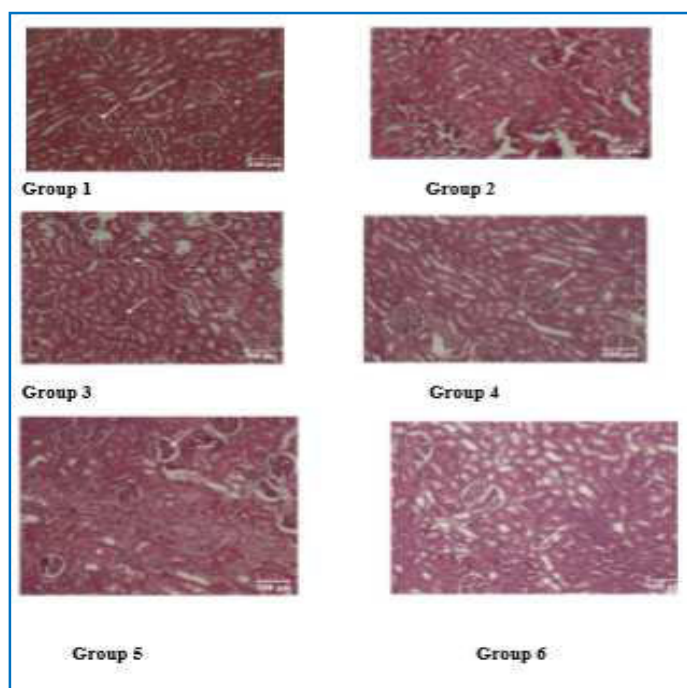
Group 3: Inj Gentamicin + Aq Extract low dose, low dose Kidney showing normal architecture with moderate degeneration of glomerulus (arrow), congestion of blood vessels. The proximal and distal convoluted tubules lined by columnar epithelial cells are showing vacuolar degeneration with cell debris in the lumen (asterisk).

Group 4: Inj Gentamicin + Aq Extract high dose. High dose Kidney showing normal architecture of glomerulus with tuft of blood capillaries surrounded by Bowman's capsule (arrow) with mild congestion of blood vessels. The proximal and distal convoluted tubules lined by columnar epithelial cells are showing normal architecture (asterisk).

Group 5: Inj Gentamicin + Ethanolic extract (Low dose), low dose Kidney showing normal architecture with moderate degeneration of glomerulus with loss of blood capillaries (arrow) with mild congestion of blood vessels. The proximal and distal convoluted tubules lined by columnar epithelial cells are showing vacuolar degeneration, swollen cells and edema fluid accumulation (asterisk). Haematoxylin and Eosin stain, scale bar=100µm.

Group 6: Inj Gentamicin 80mg/kg body wtIP + Ethanolic extract high dose, high dose Kidney showing normal architecture with mild degeneration of glomerulus with loss of blood capillaries and vacuoles (arrow) with mild congestion of blood vessels. The proximal and distal convoluted tubules lined by columnar epithelial cells are showing vacuolar degeneration and cell debris in the lumen (asterisk).

Plate 1: Histopathology pictures of kidneys of rats



DISCUSSION

Discussion on experimental study

Aqueous extract and ethenolic extract of *Sphaeranthus indicus* Linn. is used for the study to compare with gentamicin induced nephrotoxicity in rats. The animal models employed for screening of nephrotoxicity and nephron protective effect of the drug.

The acute toxicity studies done suggested that drug is nontoxic up to 2000-4000mg/kg, this revealed that drug is safe and appreciated for use in very high dose also.

The data related to serum biochemical parameter indicates that injection of gentamicin causes highly significant elevation indicating that the protocol employed produces significant kidney injury,

remarkable reversal of these changes by both the test extracts indicates presence of significant nephroprotective activity. The observed effect was dose depended further there was no significant difference between aqueous and ethanol extracts. The above results were further correlated by the histopathological examination in which gentamicin was focused to be produced. The toxicants induced changes were found to be significantly less in test extract administered groups in comparison to gentamicin control.

Discussion on histopathological study

Plate 1- Examination of kidney sections from normal control group showed normal sito architecture in both cortex and medullary regions. Plate 1 repeats representative photo micrograph from this group.

Plate 2- Microscopic examination of kidney sections from gentamicin control group showed marked degenerative changes. This was evident in the form of nephrotic oedema, marked necrotic changes in tubular epithelium, accumulation of proteous material in the tubules also occur. Plate 2 repeats photomicrograph of representative section from this group.

Plate 3- Examination of kidney sections from gentamicin injected, low dose aqueous extract administered group revealed comparatively moderate degenerative changes in comparison to gentamicin induced group, only moderate degenerative changes in the tubular epithelium, proteous material, accumulation in tubular lumen is low.

Plate 4- Examination of sections of kidney from gentamicin injected, high dose aqueous extract administered group revealed almost normal sito architecture, glomeruli and tubules, blood vessels are found to be normal no significant degenerative changes to be observed.

Plate 5- Examination of sections of kidney from gentamicin injected, low dose ethanolic extract administered group revealed, moderate to severe degenerative changes in the form of glomular congestion, increase in peri glomerular, extensive

diffused tubular necrosis, accumulation of protiaus material and mild cell degeneration

Plate 6- Examination of sections of kidney from gentamicin injected, High dose ethanolic extract administered group revealed, mild degenerative changes in the form of glomerular dilatation and diffused degenerative changes in the tubular epithelium, and otherwise the section exhibited normal sito architecture.

CONCLUSION

Toxicological studies showed that the drug is safe for use in both lower and higher doses. Hence *Mundi* can be used as drug of choice in renal diseases. Histopathological parameters justified that both aqueous and ethanol extracts showed nephroprotective activity, when compared between these, aqueous extract with high dose was proven to be better than other extracts.

REFERENCES

1. <https://scialert.net/fulltext/?doi=ijp.2011.171.179>
2. <https://dailyhealthpost.com>.

3. Dymock W, Warden CJ, Hooper D. 2nd. London: Kegan Paul, Trench, Trubner and Co; 1891. Pharmacographia India; p. 257.
4. Anonymous. www.OECD.com.
5. Horbone IB. Phytochemical methods-A grade to modern techniques of plant analysis. Chapman and hall London; 1998: pp 44, 129, 203.
6. Abdel-Gayoum AA, Ali BH, Abdel Razig KM, Bashir AA, Ghywarsua K. Effect of gentamicin-induced nephrotoxicity on some carbohydrate metabolism pathways in the rat renal cortex. Arch Toxicol 1994; 68:643-7.
7. Yousef et al. protective effect of grape seed proanthocyanidin extract against oxidative stress induced by cisplatin in rats, food and chemical toxicology 47(2009)1176-1183(science direct).

How to cite this article: Dr. Seema Pradeep, Dr. Mahesh CD, Dr. Manjunath PM, Dr. Saraswathidevi HN. Nephroprotective activity of Mundi (*Sphaeranthus indicus* linn.) - An Experimental Study. J Ayurveda Integr Med Sci 2019;5:143-151. <http://dx.doi.org/10.21760/jaims.4.5.24>

Source of Support: Nil, **Conflict of Interest:** None declared.
