



ISSN 2456-3110

Vol 5 · Issue 2

Mar-Apr 2020

Journal of
**Ayurveda and Integrated
Medical Sciences**

www.jaims.in

JAIMS

An International Journal for Researches in Ayurveda and Allied Sciences



Charaka
Publications

Indexed

An Anatomico-Physiological review of the *Uttara Guda* and *Adhara Guda* w.s.r. to the concept of defecation

Dr. Deepak Verma¹, Dr. Shivangi Kunwar²

¹Assistant Professor, Dept. of Sharira Rachana, Shivalik Institute of Ayurved and Research, Dehradun, ²Post Graduate Scholar, Dept. of Sharira Rachana, Rishikul Campus, Haridwar, Uttarakhand, INDIA.

ABSTRACT

Ayurveda is the sea of knowledge and to get a pearl from it, we should wear a 'diving suit of curiosity' and make deep dive. The cause of our diving is to curiosity about the human body part called *Guda* (ano-rectum). We elaborate how it is correspond to ano-rectum in modern anatomy. On the basis of literature review we also elaborate the two terminologies i.e. *Uttara Guda* (distal rectum) and *Adhara Guda* (anal canal), which seems to be the functional division of *Guda* (ano-rectum). The function of *Uttara Guda* (distal rectum) and *Adhara Guda* (anal canal) are compared with the particular parts of ano-rectum to simplify the exact anatomy of these parts.

Key words: *Guda, Uttara Guda, Adhara Guda, Ano-rectum.*

INTRODUCTION

As *Ayurveda* is an *Upveda* of *Atharaveda*, it is one of the earliest and undoubted sciences. It comprises the vast knowledge about human health and way to live life. The *Granthas* (literatures) related to this science is filled with the description of human body and its constituent. Components of the body are described concisely with the diseases in which they involve or in some particular chapters which gives some details of body parts. Due to this pattern of our literature, the knowledge of body components are scattered and in disordered way.

Address for correspondence:

Dr. Deepak Verma

Assistant Professor, Dept. of Sharira Rachana,
Shivalik Institute of Ayurved and Research, Dehradun,
Uttarakhand, INDIA.

E-mail: deepakroboverma@gmail.com

Submission Date: 16/03/2020 Accepted Date: 22/04/2020

Access this article online

Quick Response Code



Website: www.jaims.in

Published by Maharshi Charaka
Ayurveda Organization, Vijayapur,
Karnataka (Regd) under the license CC-
by-NC-SA

One of the important body part which is widely referred in the ancient *Ayurvedic Granthas* is *Guda* (ano-rectum). Almost every *Acharayas* described the diseases which effect *Guda* such as *Guda Bhamsha* (rectal prolapsed), *Bhagandara* (ano-rectal fistula), *Arsha* (piles), *Parikartika* (fissure in ano), *Sanniruddha Guda* (imperforated anal canal) etc. major description about the *Guda* (ano-rectum) i.e. its measurement, appearance etc. is seen with the description of disease *Arsha*. *Guda* (ano-rectum) is also mentioned as one of the *Kosthanga* (viscera), *Moola* of *Purisha Vaha Srotasa* (root of the channels which carry faeces), a *Karmendriya*, *Pranayatana* (a place where *Prana* situated), site of *Mooladhara Chakra* (inferior hypogastric plexus) and a *Marma* (vital point) situated in *Udara Pradesh* (abdomen). *Acharayas* also mentioned the *Mamsa Peshi* (muscles), *Sandhi* (joint), *Asthi* (bone), *Dhamani* (artery), *Kala* (membrane or lining), *Sira* (vein) and *Snayu* (ligament) present in the *Guda* region.

Instead of these details about *Guda* (ano-rectum), division of *Guda* (ano-rectum) is one of the important but leftover parts of it. In the ancient literature most of the time *Guda* (ano-rectum) term is used to denote it but in some places *Acharayas* mentioned *Uttara*

Guda (distal rectum) and *Adhara Guda* (anal canal) in place of *Guda* (ano-rectum). *Uttara Guda* (distal rectum) and *Adhara Guda* (anal canal) seems like the division of *Guda* (ano-rectum) but the basis of this division is still a question. The existing literature evidences hints that the division shows the functional variations and has different anatomy. Due to lack of references the clarification of this topic is still controversial. So there is a need for thorough study of related topic, to illuminate *Uttara Guda* (distal rectum) and *Adhara Guda* (anal canal) by filling this lacuna.

AIM AND OBJECTIVE

To review the literature related to *Guda* (ano-rectum), and to clarify the *Uttara Guda* (distal rectum) and *Adhara Guda* (anal canal) by mean of Ayurveda as well as modern aspect.

GUDA

According to *Shabda Kalpa Druma* word *Guda* is derived from Sanskrit term “*Gud + Egupadeti*”,^[1] it means the organ which does the function of *Apanavayu*. According to *Amarakosha*,^[2] “The *Guda* word is derived from ‘*Gu*’ *Dhathu* and does the function of expulsion of faeces”. *Maharshi Sushruta* has described the process of the formation of *Guda* (ano-rectum) i.e. the *Prasada Bhaga* (extract) of *Asruk* (blood) together with *Shleshma* (mucous), while undergoing *Paka* (digestion) by *Pitta*, is traversed by *Vayu*. Due to this activity, the *Antrani* (intestines), the *Guda* (rectum and anus) as well as the *Basti* (urinary bladder), get formed inside the abdomen, just like essence of gold gets formed by blowing air^[3] (on the molten gold). *Guda* (ano-rectum) is mentioned as one of the *Koshthanga*^[4] (viscera) which means it is situated somewhere in *Koshtha* (thoracoabdominal cavity). According to *Acharya Sushruta*, situation of *Guda* (ano-rectum) is considered as below the *Nabhi* (umbilicus); which is accompanied with other organs such as; *Pakvashaya* (large colon), *Kati* (lower back), *Mutra* (urine), *Purisha* (stool), *Basti* (urinary bladder), *Medhra* (penis) and *Sakthi* (lower limbs).^[5] *Vagbhata* has explained that *Basti* (urinary bladder), *Basti Shira* (ureter), *Medhra* (penis), *Kati* (lower back), *Vrishana*

(scrotum) and *Payu* (ano-rectum) are situated in *Guda Asthi Vivara* (pelvic cavity), these structures are related with each other.^[6] *Acharaya Charaka* and *Maharshi Sushruta* both have mentioned the length of *Guda* (ano-rectum) with the description of *Arsha Vyadhi* (piles). The length of *Guda* (ano-rectum) is 4 ½ *Angula*.^{[7],[8]} (1 *Angula* is equals to 1.9 cm.) and it is attached with *Sthulaantra*^[8] (large intestine). *Vagbhata* and *Bhavprakasha* have the same view about the length of *Guda* (ano-rectum) as *Charaka* and *Sushruta*. *Guda Vali* (transverse rectal folds) is the chief constituent of the *Guda* (ano-rectum). These are 3 in number named as *Pravahini* (superior rectal fold), *Visarjini* (middle rectal fold) and *Samvarani* (inferior rectal fold), and have the colour resemblance to the *Gaja Talu* (elephant’s palate). These three *Valies* (transverse rectal folds) are arranged in a spiral manner like the ridges of conch shell, placed one above another at an interval of one and half *Angula* (finger). Lower most *Vali* (inferior rectal fold) is situated at a distance of 1 *Angula* (finger) from *Gudoashtha*^[9] (anal orifice). *Gudoashtha* (anal orifice) is the lower most part of *Guda* (ano-rectum). *Maharshi Sushruta*, *Vagbhata* and *Bhavprakasha* have mentioned that the area of 1½ *Yava Pramana* (barley grain) i.e. ½ *Angula Pramana* (finger in measurement) from the *Romanta* (borderline from where anal hair ends) is considered as *Gudoashtha* (anal orifice).^{[10],[11]}

Guda (ano-rectum) is mentioned as one of the *Karmendriya*. Its function as mentioned by *Acharyas* is *Visarga*^[12] (expel), means to excrete the *Mala* (faeces) from the body. *Guda* (ano-rectum) and *Antra* (colon) are the sites of *Apana Vayu* (functional entity of lower abdomen), this *Vayu* generates the force to the expulsion of fecal material.^[13]

Uttara Guda and Adhara Guda

The *Uttara Guda* (distal rectum) and *Adhara Guda* (anal canal) are not detailed as an independent heading throughout the ancient literature, instead these terms are referred in the description of *Koshthanga* (viscera) and *Matruja Bhava* (maternal element).

Acharya Charaka and Bhela both have considered that Uttara Guda (distal rectum) and Adhara Guda (anal canal) are Koshthanga (viscera).^{[4],[14]} Acharya Charaka mentioned that all the soft organs are formed by “Matruja Bhava” (maternal element), Uttara Guda (distal rectum) and Adhara Guda (anal canal) are also listed among them.^[15]

Chakrapani has elaborated Uttara Guda (distal rectum) as a part where stool rests and Adhara Guda (anal canal) as the lower part of Guda (ano-rectum) which expels Purisha (stool).^[16]

MODERN REVIEW

Ano-rectum is the terminal part of large intestine. It is 15-16 cm long. Its extension is from anal verge to recto-sigmoidal junction. The average length of rectum is 12 cm and anal canal is 4 cm in length. The rectal part is from recto-sigmoidal junction to ano-rectal ring and the anal canal extends proximally from the anorectal junction and distally to the anal verge (edge of the anal orifice / ano cutaneous line of Hilton). Anal verge is identified by the characteristic puckering of the skin formed by the penetrating fibres of the conjoint longitudinal muscle of the anal canal. Rectum’s upper diameter is similar to that of the sigmoid colon, but more inferiorly it becomes dilated as the rectal ampulla. The muscular layer of rectum contains outer longitudinal layer and the inner circular layer. When the rectum is empty, the mucosa has several longitudinal folds in its lower part. These folds promote distension when the stool starts collection in the lower rectum (adaptive relaxation). The rectum commonly has three permanent semilunar transverse or horizontal folds i.e. superior, middle and inferior.

The anal canal is divided into upper and lower parts by the pectinate line (dentate line). The upper part contains anal column (6-10 permanent longitudinal folds), anal valves and anal sinuses (anal gland’s ducts open into it). The lower part of anal canal is further divided into two regions. Its upper region (pectin / transitional zone) is 15 mm long and extends from the pectinate line to Hilton’s line (white line of Hilton). Lower region (cutaneous part) is about 8 mm in

extent and lined by the true skin, contains sweat and sebaceous gland.^[17] (Figure 1)

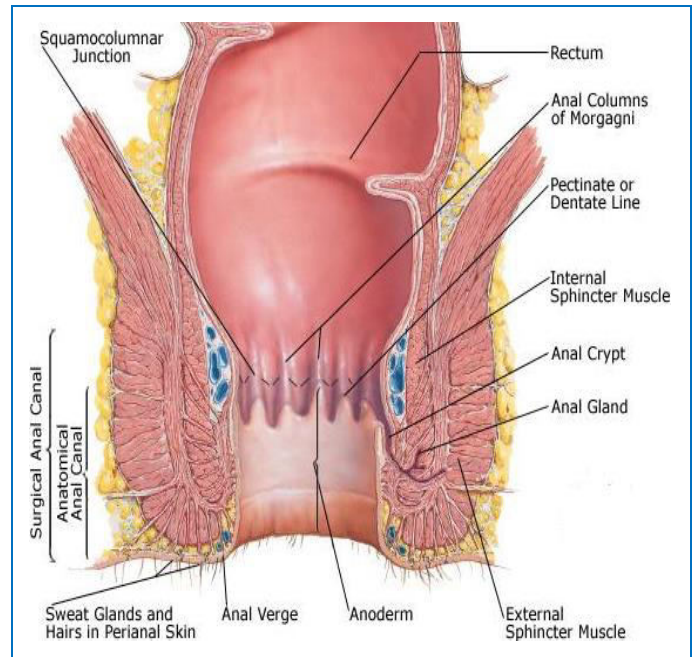


Figure 1: The Lower Rectum with Anal Canal and the Musculature

Source: https://link.springer.com/chapter/10.1007/978-3-319-95114-0_59

Muscles of the Anal Canal (Figure 2)^{[17],[18]}

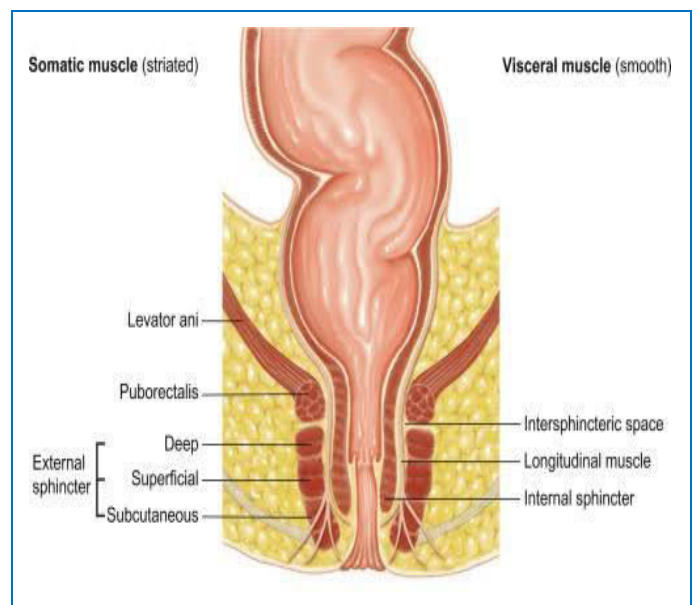


Figure 2: The musculature of ano-rectum with its division.

Source: <https://www.sciencedirect.com/topic/immunology-and-microbiology/sphincter>

Internal anal sphincter

The Internal anal sphincter is composed of smooth muscle fibers and is the thickened continuation of circular layer of the rectum. The caudal end of the internal anal sphincter is located at a distance of 8-10 mm from the anus. It is absent in the contraction zone of the subcutaneous portion of the external anal sphincter. Outside the internal anal sphincter is located a longitudinal smooth muscle layer. The puborectalis muscle, the deep and superficial portions of the external anal sphincter are located outside of longitudinal smooth muscle layer. This sphincter is innervated by autonomic nerves (autonomic nervous system).

Function

The internal anal sphincter is a smooth muscle in a state of continuous maximal contraction. It is represented as a natural barrier to the involuntary loss of gas and stool, but it relaxes as a consequence of reflex activity, predominantly during defecation. Rectal distension causes temporary relaxation of the upper internal anal sphincter. Relaxation of this sphincter gives passage for the progression of distal rectal contents into the upper anal canal; this is accompanied by sustained contraction of the distal internal anal sphincter and contraction of the external anal sphincter to maintain continence.

Conjoint longitudinal muscle

The outer longitudinal layer of the rectum, at the level of the anorectal ring, mixes with fibers (striated muscle fibres) of the levator ani muscle to form the conjoined longitudinal muscle. It descends between internal and external anal sphincters. As conjoint longitudinal muscle passes down the anal canal, muscle fibres peel off in three directions i.e. internally (to reach the anal submucosa), inferiorly (to insert into the perianal skin), Outwards (towards the subcutaneous fat around anal canal). The conjoint longitudinal muscle is innervated by autonomic nerves. Its contraction during defecation shortens and widens the anal canal, and everts the anal orifice to assist incontinence.

External anal sphincter

The external anal sphincter is an oval tube of striated muscle forms the maximum part of the anal sphincter complex. It covers the internal anal sphincter and ends slightly more distal to it. Like the levator ani and internal anal sphincter, the external anal sphincter is tonically contracted at rest (the postural reflex).

Division

It is with upper (deep) and lower (superficial and subcutaneous) parts. The upper part surrounds the internal anal sphincter while the lowermost part encircles the anal canal inferior to the internal anal sphincter. Subcutaneous part is a true circular sphincter. The superficial portion of the external anal sphincter has a U-shape. The deep part of the external anal sphincter has a small volume and is located caudal to the puborectalis muscle. It is located so close to the puborectalis muscle so considered to be part of the puborectalis muscle. The external sphincter is controlled by nerve fibers in the pudendal nerve, which is part of the somatic nervous system and therefore is under voluntary, conscious, or at least subconscious control.

The levator-ani muscle

This group of muscle is also give support to sphincteric mechanism in the anal canal. It is a broad; thin muscle which forms the floor of pelvic cavity. The main function of the levator ani muscle is the opening of the anal canal and to straighten the anorectal angle during defecation.

It is consists of 3 parts;

1. Iliococcygeus:
2. Pubococcygeus:
3. Puborectalis:

Anorectal Ring and Anorectal Angle (Figure 3)^[17]

It is a ring of muscles surrounds at the junction of rectum & anal canal. This is composed of puborectalis sling and upper border of internal & external sphincters. Due to the anterior pull of puborectalis muscle an angle is formed between rectal ampulla

and the anal canal, called anorectal angle. The anorectal angle is thought to be the result of the anatomic configuration of the U-shaped sling of puborectalis muscle around the anorectal junction. Whereas the anal sphincters are responsible for closure of the anal canal to retain gas and liquid stool, the puborectalis muscle and the anorectal angle are designed to maintain gross faecal continence.

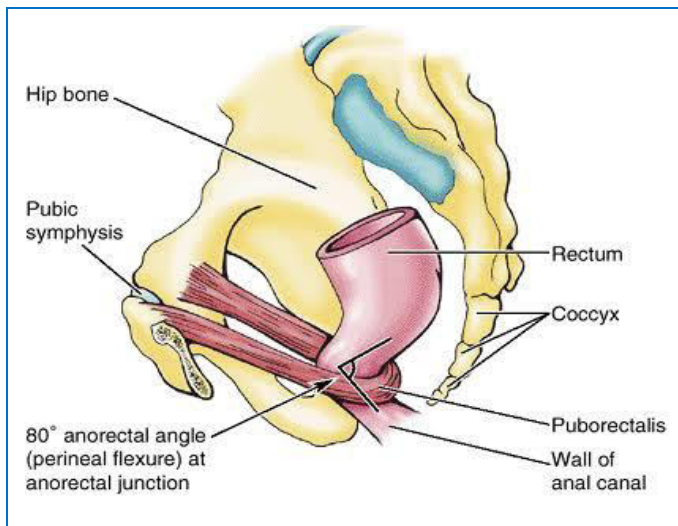


Figure 3: The ano-rectal ring and ano-rectal angle with puborectalis

Source:

<https://www.goggle.com/amp/s/www.pinterest.com/amp/pin/403072235372119982/>

Defecation^[18-20]

Defecation is the act of voiding stool from the anus and involves the coordinated function of the colon and rectum, pelvic floor and anal sphincter. Most of the time, the rectum is empty of feces because a weak functional sphincter exists about 20 centimeters from the anus at the recto-sigmoidal junction and also a sharp angulation here that contributes additional resistance to filling of the rectum. Contraction in the colon results in the antegrade propulsion of intraluminal contents to the rectum. There are two type of defecation reflex which initiates the defecation;

A. Intrinsic reflex mediated by the local enteric nervous system in the rectal wall. It is relatively weak reflex.

Feces reaches in rectum → distention of the rectal wall → afferent signals initiated → these signals spread through the myenteric plexus to initiate peristaltic waves in the descending colon, sigmoid, and rectum, forcing feces toward the anus → inhibitory signals from myenteric plexus relaxes the internal sphincter → defecation will be occurred if the external anal sphincter relaxed voluntarily at the same time.

B. Parasympathetic defecation reflex - The reflex involves the sacral segments of the spinal cord and strengthens the intrinsic reflex to make defecation.

Rectal distention → nerve ending stimulated → signals are transmitted to the spinal cord → then signal reflexes back to the descending colon, sigmoid, rectum, and anus by way of parasympathetic nerve fibers in the pelvic nerves → these signals greatly intensify the peristaltic waves and relax the internal anal sphincter.

Defecation signals which are entering the spinal cord also cause the pelvic floor to relax downward and pull outward on the anal ring to evaginate the feces.

The rectum acts as a reservoir and is able to relax to accommodate fecal material and gas (adaptive relaxation). Between the rectum and anal canal there is a narrow opening (it appears in the upper portion of anal canal due to the relaxation of the upper fibres of internal anal sphincter) through which the gas and liquid feces can penetrate into the upper part of the anal canal. In the mucosa at this level there are sensors that allow distinguishing the liquid from gas. In the presence of gas is enough to strain the abdominal wall to increase rectal pressure and expel gas through the lower part of the closed anal canal. Passing under pressure through a narrow channel gas causes a characteristic sound. When the liquid feces penetrate into the upper part of the anal canal the tone of the EAS (external anal sphincter) increases, which leads to a contraction of the IAS (internal anal sphincter) and crowding out of the fluid from the anal canal into the rectum this process is called anorectal inhibitory reflex. During anorectal inhibitory reflex the formed stool remain in the rectum due to acute

anorectal angle and the narrow holes between the rectum and anal canal. After a few seconds the rectum adapts to the new volume of stool and relaxes. After entering into the rectum of another portion of faeces this picture (anorectal inhibitory reflex) is repeated. This picture can be observed upto 7 times per hour. During the anorectal inhibitory reflex a gas and liquid does not penetrate into the lower part of the anal canal as result of circular contraction of the deep portion of the EAS (external anal sphincter) and the contraction of puborectalis muscle. If the defecatory urge is associated with a conscious decision to evacuate, distal progression of colonic high-amplitude propagating complexes, rectal contractions, raised intra-abdominal pressure from voluntary straining (the efficiency of which is influenced by posture), relaxation of puborectalis (which straightens the anorectal angle) and the anal sphincters all combine to enable defecation.

DISCUSSION

Guda (ano-rectum) is situated in *Koshtha / Madhya Sharira* (thoraco-abdominal cavity). Here are two division of *Guda* (ano-rectum) mentioned in classical literature i.e. *Uttara Guda* (distal rectum) and *Adhara Guda* (anal canal). *Gudoaushtha* (anal orifice) is mentioned as lower most part of *Guda* (ano-rectum). *Chakrapani* gives commentary on both of the *Guda* (ano-rectum) part i.e. *Uttara Guda* (distal rectum) is a part of *Guda* (ano-rectum) where *Purisha* (faeces) stored or it is a reservoir of stool, on the other hand *Adhara Guda* (anal canal) is a part which involved in the removal process of faecal material.

Uttara means higher, so it means *Uttara Guda* (distal rectum) is located superiorly and it stores faeces. *Uttara Guda* (distal rectum) should have enough space for the storage. According to modern science the rectum acts as a reservoir and accommodate according to faecal material and gas. The lower part of rectum lodges several longitudinal folds which become vanished during distention. Rectum did not involve in defecation until conscious decision has been taken to evacuate the stool. Relaxation of upper part of internal anal sphincter (sampling) is reflex

response to rectal distention, it cause the leaking of the rectal content into upper most part of anal canal. This sampling is occurs only to know either the content is faeces or flatus (gas), if it is gas then it pushes outside instead if it is faeces then it pushes back to the rectum. The stool is pushes back because the external anal sphincter didn't relaxed, it can only relaxed voluntarily (on the urge to defecate) otherwise it is always in a state in a tonic contraction. It simply proves that when rectum is full of stool it distended till the area where upper most margin of external anal sphincter lies or distended rectum never encroach the region where external anal sphincter lies. Another muscle called puborectalis also plays a great role in continence. It also maintains a state of tonic contraction until it is voluntarily relaxed in the process of defecation. The upper margin or fiber of external anal sphincter, internal anal sphincter and puborectalis sling are combinedly composed the anorectal ring. So the *Uttara Guda* (distal rectum) region is above the anorectal ring. This anorectal ring seems like the area of differentiation for *Uttara* (distal rectum) and *Adhara Guda* (anal canal).

Adhara means lower part, so it is the lower region of *Guda* (anal canal) and its function is to remove faeces from body. In the procedure of defecation colon, rectum, intra abdominal pressure (due to straining), relaxation of puborectalis, the anal sphincters and conjoint longitudinal muscle takes place. All of these factors are actively participate when the urge for the defecation occurs. It causes voluntary relaxation of external sphincter. This sphincter extends from anorectal ring to anal verge. The external anal sphincter is controlled by pudendal nerve, which is a part of somatic nervous system and therefore under voluntary conscious control. Simultaneously With the external anal sphincter contraction, rectal contraction, relaxation of puborectalis (its relaxation straighten the anorectal angle) and contraction of conjoint longitudinal muscle (it shorten and open the anal canal and also flatten the anal cushion) occurred. Essential changes in the lower anal canal (below the anorectal ring) i.e. relaxation of external anal sphincter and puborectalis and contraction of conjoint

longitudinal muscle causes removal of faecal material. So the *Adhara Guda* (anal canal) mentioned by *Acharyas* should be the region below the ano-rectal ring. In the study we saw that the structures responsible for the storage of faeces are the same factors which involve expelling the stool also. It indicates that the term *Guda* (ano-rectum) is used to denote the anatomical structure which is situated at the end of *Sthula Antra* (large colon) but the terms *Uttara Guda* (distal rectum) and *Adhara Guda* (anal canal) are used to denote the specific part of *Guda* (ano-rectum) which are physiologically different. It seems like *Acharya Charaka* listed the *Koshthanga* (viscera) on the basis of their functional variations. The *Uttara Guda* (distal rectum) perform his activity under involuntary control (autonomic control), on the other hand *Adhara Guda* (anal canal) is in voluntary control (somatic nerve).

CONCLUSION

Uttara Guda (distal rectum) can be compared with rectum especially the lower rectum (ampullary part) because it is a part of *Guda* where accumulation of *Mala* (faecal material) takes place; the same function is done by ampullary part of rectum (due to the presence of longitudinal folds). *Adhara Guda* (anal canal) is compared with the anal canal from anorectal ring to anal verge.

The term *Guda* (ano-rectum) is used to denote the anatomical structure at the terminal part of *Sthulaantra* (large colon) on the other hand *Uttara Guda* (distal rectum) and *Adhara Guda* (anal canal) are division of the *Guda* (ano-rectum) on the basis of functional variations.

ACKNOWLEDGEMENT

The authors are highly thankful to the learned faculty Dr. A. N. Pandey for his active guidance throughout the completion of the work.

REFERENCES

1. Radhakant Dev, *Sabda Kalpdrama*, Naag Publication; Reprint 1988; Vol-2, p.338

2. Amarasimha; *Amarakosha*, Chaukhambha Sanskrit Sansthan Varanasi; Reprint 2006; kaand-2,varga-6, p.293
3. *Sushruta Samhita of Sushruta with Ayurveda – Tattva - Sandipika Hindi commentary*; edited by Kaviraja Ambikadutta Shastri; Chaukhambha Sanskrit Sansthan, Varanasi, Reprint 2010; *Sharira Sthana*, 4th chapter, 26 and 27th verse, p.41
4. *Charaka Samhita of Agnivesha with Ayurveda, Vidyotini Hindi commentary*, edited by Dr. Gorakha Nath Chaturvedi and Pt. Kasinatha Shastri ; Chaukhambha Bharati Academy, Varanasi; Reprint 2015; *Sharira Sthana*, chapter 7th, 10th verse, p.913
5. *Sushruta Samhita of Sushruta with Ayurveda – Tattva - Sandipika Hindi commentary*, edited by Kaviraja Ambikadutta Shastri; Chaukhambha Sanskrit Sansthan, Varanasi, Reprint 2010; *Sharira Sthana*, chapter 9th, 7th verse, p.14
6. *Ashtanga Hridaya of Acharya Vagbhata with Vidyotini Hindi commentary*, edited by Atrideva Gupta, Chaukhamba Publication, Varanasi, Reprint 2015; *Nidana Sthana*, chapter 9th, 1st verse, p.340
7. *Charaka Samhita of Agnivesha with Ayurveda Vidyotini Hindi commentary*, edited by Dr. Gorakha Nath Chaturvedi and Pt. Kasinatha Shastri ; Chaukhambha Bharati Academy, Varanasi; Reprint 2015; *Chikitsa Sthana*, chapter 14th, 6 verse, p.417
8. *Sushruta Samhita of Sushruta with Ayurveda – Tattva - Sandipika Hindi commentary*, edited by Kaviraja Ambikadutta Shastri; Chaukhambha Sanskrit Sansthan, Varanasi, Reprint 2010; *nidana Sthana*, chapter 2nd, 5th verse, p.307
9. *Sushruta Samhita of Sushruta with Ayurveda – Tattva - Sandipika Hindi commentary*, edited by Kaviraja Ambikadutta Shastri; Chaukhambha Sanskrit Sansthan, Varanasi, Reprint 2010; *Sharira Sthana*, chapter 2nd, 5 to 8th verse, p.307
10. *Ashtanga Hridaya of Acharya Vagbhata with Vidyotini Hindi commentary*, edited by Atrideva Gupta, Chaukhamba Publication, Varanasi, Reprint 2015; *Nidana Sthana*, chapter 7th, 5th verse, page no.331
11. *Bhava Prakasha Samhita of Acharya Bhava Mishra with Vidyotini Hindi commentary*, edited by Shri Harihar Prasad Pandey; Chaukhambha Sanskrit Sansthan,

- Varanasi, 3rd edition; Purva Khand, chapter 3rd, 91th verse, p.29
12. Charaka Samhita of Agnivesha with Ayurveda Vidyotini Hindi Commentary, edited by Dr. Gorakha Nath Chaturvedi and Pt. Kasinatha Shastri ; Chaukhambha Bharati Academy, Varanasi; Reprint 2015; Sharira Sthana, chapter 1st, 26th verse, p.807
13. Charaka Samhita of Agnivesha with Ayurveda:Vidyotini Hindi Commentary, edited by Dr. Gorakha Nath Chaturvedi and Pt. Kasinatha Shastri ; Chaukhambha Bharati Academy, Varanasi; Reprint 2015; Chikitsa Sthana, chapter 28th, 11 verse, p.778
14. Bhel Samhita of Acharaya Bhela; Hindi commetary edited by Shri Girijadyalu Shukla, Chaukhambha Bharati Academy, Varansi; Reprint 1999; Sharira Sthana, chapter 7th, 4th verse; page no.90
15. Charaka Samhita of Agnivesha with Ayurveda Vidyotini Hindi Commentary, edited by Dr. Gorakha Nath Chaturvedi and Pt. Kasinatha Sastri ; Chaukhambha Bharati Academy, Varanasi; Reprint 2015; Sharir Sthana, chapter 3rd, 6th verse, p.855
16. Charaka Samhita by Agnivesha with Ayurveda Dipika Ayushi Hindi Commentary, edited by Vd. Harish Chandra Singh Kushwaha, Chaukhamba Orientalia, Varansi; Reprint 2016; Sharir Sthana, chapter 7th, 10th verse; p.847
17. Peter j Lunniss, Gastrointestinal tract, in: Susan standring, editor. The anatomical basis of clinical practice; 41th edition, Elsevier Publication: U.S.A., 2016, p.1146-1157
18. Michael d. Levin, The role of the external anal sphincter in the physiology of the pelvic floor, Pelvipereineology, 2017;36(3):24-29
19. Peter j Lunniss, Gastrointestinal tract, in: Susan standring, editor. Gray's anatomy, The anatomical basis of clinical practice; 41th edition, Elsevier Publication: U.S.A., 2016, p.1158
20. Arthur C. Guyton and john E. hall. Guyton and hall: Textbook of medical physiology, 12th edition. U.S.A. Elsevier publication, 2006.

How to cite this article: Dr. Deepak Verma, Dr. Shivangi Kunwar. An Anatomico-Physiological review of the Uttara Guda and Adhara Guda w.s.r. to the concept of defecation. J Ayurveda Integr Med Sci 2020;2:148-155.

Source of Support: Nil, **Conflict of Interest:** None declared.

Copyright © 2020 The Author(s); Published by Maharshi Charaka Ayurveda Organization, Vijayapur (Regd). This is an open-access article distributed under the terms of the Creative Commons Attribution License (<http://creativecommons.org/licenses/by/4.0>), which permits unrestricted use, distribution, and reproduction in any medium, provided the original work is properly cited.